visit our website www.jaypeebrothers.com, for detailed information on obstetrics & gynecology books, visit our website www.jaypeebrothers.com

SECOND EDITION

Celebrating 50 Passion, Quality and Innovation in Healthcare Publishing

GYNECOLOGICAL EMERGENCIES



Editor
Kamini A Rao

Co-Editor
Arveen Vohra

JAYPEE

Contents

SECTION 1: ADOLESCENTS

1. **Common Gynecologic and Urinary Problems in Pediatric and Adolescent Females** 3
   Meghana V Nyapathi
2. **Sexual Abuse and Assault in Pediatric Patient** 17
   Priyanka Yadav

SECTION 2: REPRODUCTIVE AGE GROUP

3. **Early Pregnancy: Miscarriage** 23
   Vyshnavi A Rao
4. **Gestational Trophoblastic Diseases** 34
   Arunima Halder
5. **Ectopic Pregnancy** 47
   Harpreet Kaur
6. **Leiomyoma Uterus Presenting as Emergency** 53
   Arya Rajendran
7. **Dysmenorrhea** 59
   Arveen Vohra
8. **Abnormal Uterine Bleeding** 69
   Mekhala B Dwarakanath, Jahnavi Esanakula
9. **Postcoital Bleeding** 76
   Sowmya Davuluri
10. **Infections** 81
    Karthigayeni R
11. **Pelvic Mass** 109
    Ravishankar P, Tejaswi K
12. **Ovarian Hyperstimulation Syndrome** 119
    Nivedita Shetty
13. **Ovarian Torsion** 126
    B Ramesh

14. Management of Ovarian Mass in Premenopausal Women 133
Kavita Manchanda, Jahnavi Esanakula

15. Emergencies and Complications Related to Contraception 144
Shashikala KT

SECTION 3: POSTMENOPAUSAL AGE GROUP

16. Pyometra 155
Arveen Vohra

17. Postmenopausal Bleeding 159
Arveen Vohra

18. Management of Ovarian Mass in Postmenopausal Women 167
Sonal Agarwal

19. Gynecological Emergencies in Postmenopausal Women with Mass per Vaginum 180
Anu Joseph

SECTION 4: EMERGENCIES IN GYNECOLOGICAL SURGERIES

20. Complications in Open Gynecological Surgery 187
Jahnavi Esanakula, Varsha Rengaraj

21. Complications in Laparoscopy 196
Kavita Manchanda, Varsha Rengaraj

22. Gynecological Oncology Emergencies 206
Ipsita Batra

23. Imaging in Gynecological Emergencies 214
Aradhana Kalra Dawar, Jahnavi Esanakula

SECTION 5: MISCELLANEOUS GYNECOLOGICAL EMERGENCIES

24. Acute Retention of Urine 227
Arveen Vohra

25. Sexual Assault 232
Priyanka Yadav

26. Miscellaneous Gynecological Emergencies 236
Sowmya Davuluri

27. Medicolegal and Ethical Issues in Gynecological Emergencies 242
Taswin Kaur Reddy

Index 251

4

CHAPTER

Gestational Trophoblastic Diseases

Arunima Halder

JAYPEE BROTHERS

INTRODUCTION

Gestational trophoblastic tumor is an all-inclusive term including a spectrum of benign and malignant disorders **(Flowchart 1)**. The incidence of gestational trophoblastic diseases is about 1 in 40,000 pregnancies with preponderance in the Asian population as compared to the European or the American counterparts.[1] Gestational trophoblastic neoplasia (GTN) is one of the most curable gynecological cancers. With proper chemotherapy, not only can patients be completely cured but can undergo pregnancy subsequently without any potential harm to the developing fetus.

PATHOGENESIS OF GESTATIONAL TROPHOBLASTIC DISEASES

Risk factors for developing gestational trophoblastic diseases are given in **Table 1**.

Flowchart 1: Classification of gestational trophoblastic diseases.[2]

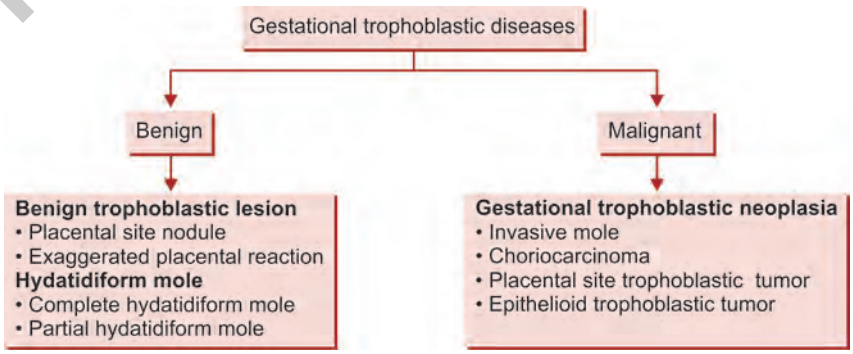

TABLE 1: Risk factors associated with gestational trophoblastic diseases.

S. No.	*Factors*	*Description*	*Remarks*
1.	Age	• Hydatidiform mole appears to be more common in extremes of gestational age and the distribution has been shown to follow a J-shaped curve[3] • Possible pathogenesis behind this could be abnormal gametogenesis and abnormal fertilization in both advanced maternal and paternal age	The risk between maternal age and the development of hydatidiform mole is better established for complete moles than partial moles
2.	Reproductive history	• Previous history of hydatidiform mole increases chance of developing molar pregnancy subsequently. Most of the time it is the same type of mole which had appeared previously • Previous spontaneous abortion may double the risk of molar pregnancy[5]	There is 1% increased chance of molar pregnancy in previous 1 hydatidiform mole and 25% chance in previous 2 moles[4]
3.	Diet	Several studies have suggested an increased incidence of complete mole with decreasing consumption of animal fat and beta-carotene. This may explain geographical variations[6]	Studies show conflicting results
4.	Others	• *Oral contraceptive pills:* Development of molar pregnancy has been attributed to prior usage of oral contraceptive pills (OCPs), its duration, and conception in the similar cycle[7] • High education, irregular menses, only male infants previously, smoking[8]	Weak association Linkage mainly to partial mole[8]

GENETICS OF GESTATIONAL TROPHOBLASTIC DISEASE

Complete Hydatidiform Mole

Complete moles are paternal in origin and are diploid. Eighty percent of them develop from the duplication of haploid sperm in an egg which has lost its maternal nuclear material before or after fertilization. Twenty percent of these may arise from the fertilization of two sperms. Though the nuclear deoxyribonucleic acid (DNA) is of paternal origin, the mitochondrial DNA remains maternal **(Figs. 1A to D)**.[9]

CLINICAL FEATURES

Previously, complete hydatidiform mole used to present with an array of symptoms like vaginal bleeding, hyperemesis gravidarum, preeclampsia, and more for gestational age uterine size. However, in the present era, such presentation is rare as detection of the molar pregnancy is quite early due to increased awareness regarding early pregnancy scans and beta-human chorionic gonadotropin (β-hCG) levels. Partial moles on the other hand, usually present with missed miscarriage or vaginal bleeding. Partial mole is usually diagnosed in histology.

PATHOLOGY

The gestational trophoblastic tumors are derived from different parts of a normal placenta itself.

JAYPEE BROTHERS

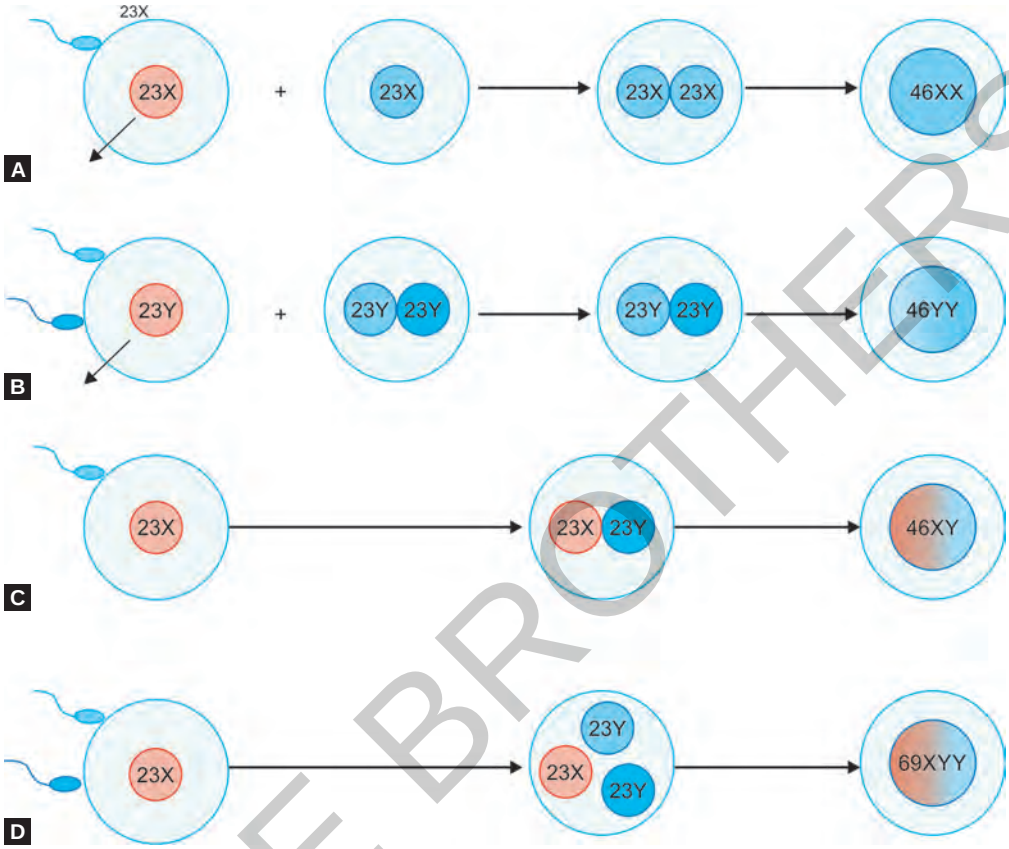

Figs. 1A to D: Genetic origins of the hydatidiform mole. (A) Loss of maternal chromosome with duplication of 23X from sperm; (B) Loss of maternal chromosome with duplication of 23Y from sperm; (C) Biparental complete hydatidiform mole (CHM) in females who are homozygous or compound heterozygous for mutations NLRP7 and KHDC3L; (D) Partial mole.

TABLE 2: Origins of various gestational tumors.

Derived from villous trophoblast	*Derived from extravillous (interstitial) trophoblast*
• Complete hydatidiform mole • Partial hydatidiform mole • Choriocarcinoma	• Placental site trophoblastic tumor • Epithelioid trophoblastic tumor

The origins of various gestational tumors are as per **Table 2.**

Complete hydatidiform moles exhibit a villous structure with the following features **(Fig. 2)**:[10]

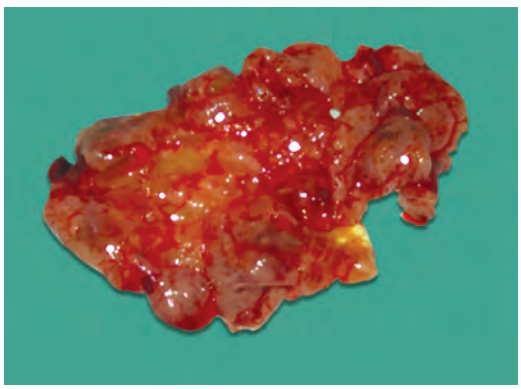

Fig. 2: Early complete hydatidiform mole.
Courtesy: Dr Soundarya Raghuram, Ganesamoni Hospital, Nagercoil

JAYPEE BROTHERS

- Abnormal trophoblastic hyperplasia
- Stromal hypercellularity
- Stromal karyotypic debris
- Collapsed blood vessels.

Partial hydatidiform mole shows:[10]

- Patchy villous hydropic changes
- Scattered abnormally-shaped villi
- Trophoblastic pseudoinclusions
- Localized trophoblastic hyperplasia.

IMMUNOHISTOCHEMISTRY IN HYDATIDIFORM MOLE

When a pregnancy is aborted in the early first trimester, it is difficult to distinguish between complete mole, partial mole, and hydropic chromosomally normal abortuses that mimic molar pregnancy. This distinction can be done by p57KIP2 immunostaining. The *p57KIP2* gene is paternally imprinted and maternally expressed. As a result, it is strongly expressed in a normal placenta. It also gets expressed in partial moles and hydropic fetuses. However, in complete moles, it remains unexpressed as the entire genome is of paternal origin. Fluorescent in situ hybridization, flow cytometry, and molecular genotyping can be used to do the immunostaining. In a summary, though histology is the primary diagnostic modality to differentiate between the types of moles, immunostaining remains an adjuvant especially for borderline histological diagnoses.

DETERMINATION OF PLOIDY

Ploidy helps in the determination of the number of complete set of chromosomes that might be present. It can be measured using flow cytometry or automated image cytometry. Automated image cytometry is however, more sensitive in the former.

TRANSVAGINAL ULTRASONOGRAPHY

Transvaginal ultrasonography is the primary mode of clinical diagnosis. Usually it presents as an enlarged heterogeneous mass of complex echogenicity. The lesion is typically called as "snowstorm appearance" or granular owing to the heteroechoic nature **(Fig. 3)**.[11] Transvaginal sonography (TVS) can also detect the extent of myometrial invasion if any. In the first trimester, the fluid-filled areas (which are actually the hydropic villi) are approximately 1 mm up to 30 mm in size. These spaces increase in size with the gestational age making a molar pregnancy more easily detectable in the second trimester. Another important thing is the measurement of uterine volume, which helps in determining the tumor burden and hence risks stratification.[12]

Partial moles, on the other hand, are associated with a growth-retarded fetus along with an enlarged placenta with heteroechoic areas or cystic areas. Partial moles can be differentiated from a dizygotic diploid twin pregnancy with concurrent complete mole by

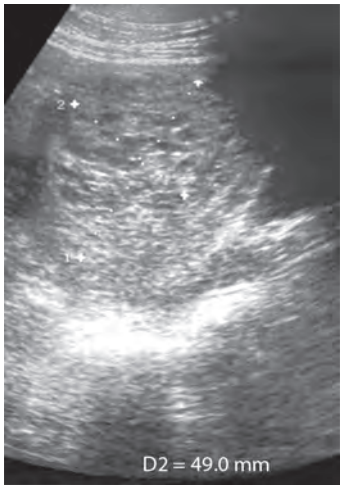

Fig. 3: Snowstorm appearance on USG.
Courtesy: Dr Vydehi. Dwarakamayi Hospital. Srikakulam.

JAYPEE BROTHERS

identification of a normal placental structure in the latter.[12,13] In the presence of cystic spaces in the placenta, a ratio of transverse to anteroposterior diameter of the gestation sac of greater than 1.5 contributes to the reliable diagnosis of partial moles.[14]

Bilateral theca lutein cysts is a common finding occur as a result of high circulating hCG levels in the body.

Although ultrasonography may be the primary diagnostic modality, histopathology along with immunochemistry clinches the diagnosis of molar pregnancy.[15]

TREATMENT OF MOLAR PREGNANCY

Most of the time, the diagnosis of a molar pregnancy is made preoperatively. However, if it is diagnosed prior to evacuation a proper treatment plan can be chalked out. Necessary investigations prior to evacuation have been enumerated in **Table 3**.

TABLE 3: List of pre-evacuation investigations.[16]

S. No.	*Investigations*	*Rationale*
1.	Chest X-ray	Postevacuation trophoblastic infiltration into lungs may occur. Pre-evacuation X-ray will prevent any confusion postoperatively
2.	CBC	Preoperative hemoglobin status
3.	BG and Rh typing	Anti-D in case of Rh-negative
4.	β-hCG	Postevacuation surveillance
5.	LFT	

(BG: blood group; β-hCG: beta-human chorionic gonadotropin; CBC: complete blood count; LFT: liver function test; Rh: rhesus)

Suction and Evacuation

Suction evacuation is the most preferred method of termination of a molar pregnancy. It is usually done under general anesthesia.

The steps while performing suction evacuation are as follows:[17]

- Oxytocin infusion to be started prior to induction of anesthesia.
- Serial cervical dilatation to be done. Misoprostol ripening of cervix to be avoided to prevent the embolization of the trophoblastic tissue.
- Suction evacuation to be carried out followed by gentle sharp curettage.
- In case of excessive intraoperative bleeding, the process of suction evacuation should be expedited.
- In case, the need for suction evacuation is precluded by the size of fetus especially in cases of partial mole, medical termination can be done. However in these cases, the chance of persistent trophoblastic disease is higher.[14,17]
- Anti-D prophylaxis to be given to those who have Rh-negative type of blood group.

Hysterectomy

In women who do not desire to preserve their fertility, hysterectomy could be an option.

Chemotherapy

Providing prophylactic chemotherapy at the time of evacuation remains controversial. In a Cochrane meta-analysis, three randomized controlled trials (RCTs) involving 613 women were analyzed. This study suggested that prophylactic chemotherapy decreases the number of women developing cancer after a molar pregnancy. However, this was more relevant in case of complete moles. The

JAYPEE BROTHERS

study further suggested that prophylactic chemotherapy actually delays the diagnosis of cancer and leads to increased requirements of anticancer agents to treat the disease.[18]

Chemotherapy may be given in the following situations:

- Stagnant or rising beta-hCG levels
- Histopathologically proven choriocarcinoma
- Distant metastases in the brain, liver, gastrointestinal (GI) tract or lungs (chest X-ray showing metastases >2 cm in diameter)
- Transvaginal or intraperitoneal or GI hemorrhage
- Vaginal metastases or lung metastases
- Serum β-hCG levels are >20,000 IU/L even after 4 weeks of evacuation (repeat evacuation has increased chance of uterine perforation).

COMPLICATIONS OF HYDATIDIFORM MOLE[19]

- *Metastases*: The metastases of molar pregnancy may happen in lungs, brain, vagina, and liver. If present in the lungs, patient may present with hemoptysis, shortness of breath, and chest pain. If in brain, they may present with dizziness, fainting, seizure, and headache. Vaginal metastases can present with vaginal bleeding or pus discharge. Liver metastases may present with signs and symptoms of jaundice and abdominal pain.
- *Anemia*: Excessive vaginal bleeding may result in lowered hemoglobin to up to less than 10 in patients with molar pregnancy.
- *Hyperthyroidism*: Associated hyperthyroidism could be seen in approximately 7% of patients with molar pregnancy. Beta sympathetic blockers are to be given in these patients before induction of anesthesia to prevent thyroid storm during a surgical procedure.
- Preeclampsia
- Pulmonary distress is seen in 2% of the cases.

POSTMOLAR SURVEILLANCE

- Postmolar surveillance is strictly individualized.
- Following evacuation, titers of β-hCG should be monitored every week or 2 weeks.
- If hCG has come back to normal within a period of 56 days following the pregnancy, follow-up has to be done for a period of 6 months from the date of evacuation. If hCG has not returned to normal within 56 days of pregnancy then follow-up for 6 months from normalization of the hCG levels.
- To prevent confusion regarding the β-hCG levels women are advised to use contraception till its levels fall below 5 mIU/L, though pregnancies during the surveillance remain more or less uneventful.

Gestational Trophoblastic Neoplasia

This is a group of disorders which is characterized by the proliferation and invasion of trophoblastic cells in the endometrium and myometrium **(Table 4)**. Although these diseases are characterized histologically, very little tissue is usually available. Most of the times, the diagnosis is made by β-hCG levels. Most of the times, an antecedent pregnancy cannot be confirmed with certainty. Most of the cases occur after molar pregnancy.

Diagnosis of GTN can be made in the following situations:[20,21]

JAYPEE BROTHERS

TABLE 4: Comparison of various gestational trophoblastic tumors.

Characteristics	*Invasive mole*	*Gestational choriocarcinoma*	*PSTT*	*ETT*
Antecedent event	Complete or partial molar pregnancy	Molar pregnancy (majority), nonmolar pregnancy	Any type of pregnancy (term gestation most commonly)	Remote pregnancy event or in most cases prior gestation cannot be confirmed
Histopathology	Syncytiotrophoblastic or cytotrophoblastic hyperplasia with presence of chorionic villi	Sheets of anaplastic trophoblastic tissue with syncytiotrophoblastic and cytotrophoblastic cells without any chorionic villi	Nests and sheets of intermediate trophoblastic cells invading between myometrial cells and fibers	Intermediate trophoblasts in sheets and nests forming tumor nodules in myometrium
Immunohistochemistry	Positive for β-hCG	Positive for β-hCG	50–100% positive for hPL. <10% positive for β-hCG	Positive for multiple markers like cytokeratin and inhibin A
Invasive nature/ metastases **(Figs. 4A to D)**	Local invasion into the vagina	Hematogenous spread to lungs, liver, and brain	Hematogenous spread to lungs, liver, and brain	Hematogenous spread to lungs, liver, and brain
Clinical features	Irregular vaginal bleeding, uterine subinvolution, theca lutein cysts, persistent vaginal bleeding, uterine perforation, and intraperitoneal hemorrhage	Vaginal bleeding, most commonly diagnosed during surveillance	Hemoptysis, headache, vaginal bleeding (signs and symptoms of metastatic event)	Hemoptysis, headache, vaginal bleeding (signs and symptoms of metastatic event)
Ultrasonography	Sonographically indistinguishable from one another. May be echogenic, hypoechoic, complex or multicystic mass within the myometrium. On Doppler they appear hypovascular or at times hypervascular			
Treatment	Single dose of chemotherapy	Chemotherapy	Hysterectomy	Hysterectomy

(β-hCG: beta-human chorionic gonadotropin; ETT: epithelioid trophoblastic tumor; hPL: human placental lactogen; PSTT: placental site trophoblastic tumor)

- Four β-hCG values that have plateaued over a period of 3 weeks (on days 1, 7, 14, and 21)
- A rising β-hCG value of greater than 10% noted over a period of 2 weeks (day 1, 7, and 14)
- β-hCG levels still persisting after a period of 6 months postevacuation of the hydatidiform mole.
- Diagnosis of choriocarcinoma on histopathology.

JAYPEE BROTHERS

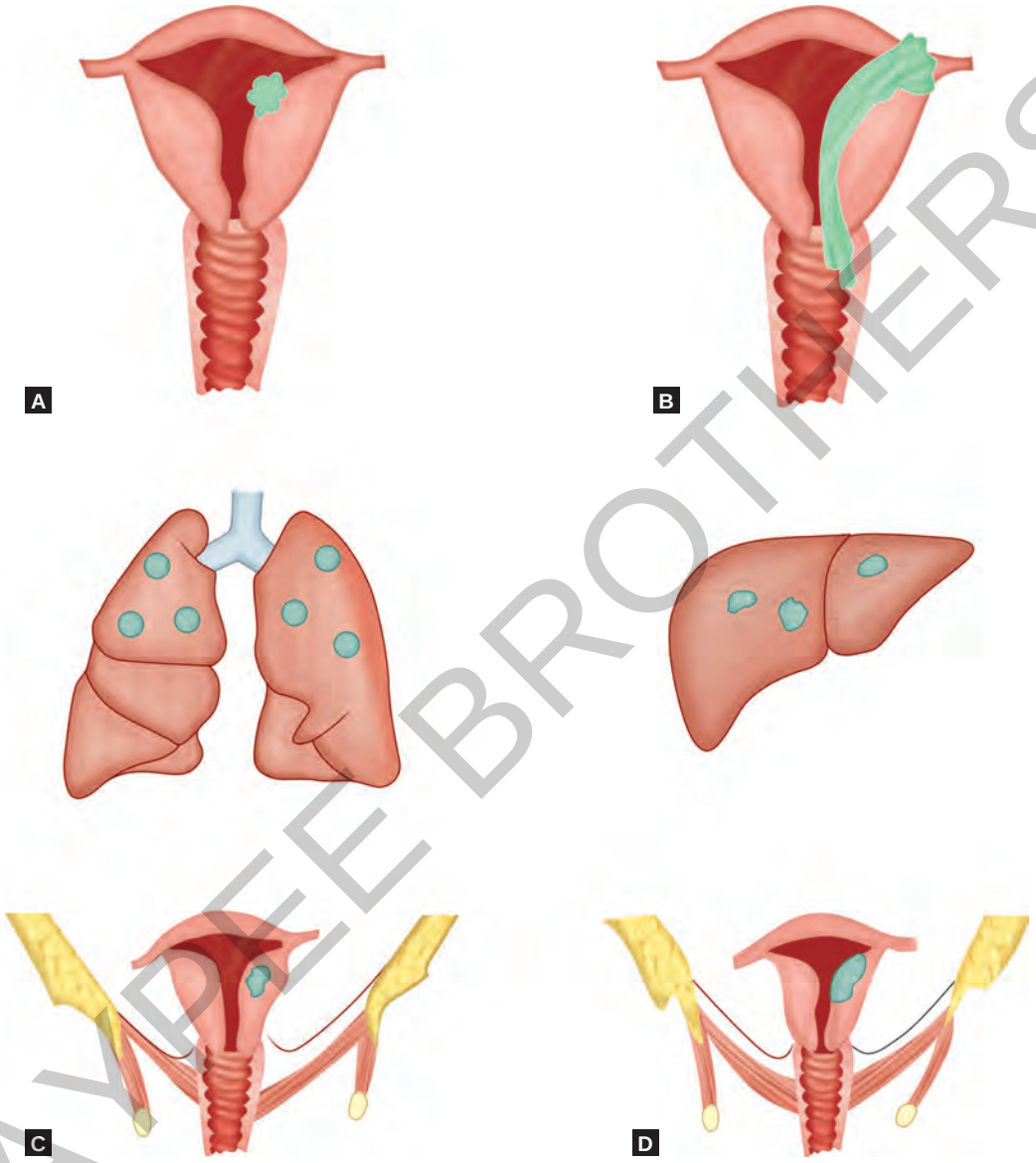

Figs. 4A to D: Various stages of gestational trophoblastic neoplasia (GTN). (A) *Stage I:* Disease confined to uterus; (B) *Stage II:* GTN extended beyond the uterus but limited to genital structures; (C) *Stage III:* GTN extends to the lungs with or without extension to other genital organs; (D) *Stage IV:* All other metastatic sites.

- Clinical or radiological evidence of metastasis.

Investigations to determine treatment strategies for a patient with GTN are as per **Table 5**.[4]

TREATMENT OF GESTATIONAL TROPHOBLASTIC NEOPLASIA

The treatment of GTN depends upon the prognostic scoring **(Table 6)** and stratifies the

JAYPEE BROTHERS

TABLE 5: Investigations to determine treatment strategies for a patient with gestational trophoblastic neoplasia (GTN).

S. No.	*Evaluation*	*Rationale*
1.	Clinical history	
2.	Examination	
3.	Measurement of serum beta-human chorionic gonadotropin (β-hCG)	
4.	Doppler ultrasound	• To the absence of pregnancy • To look for the size of the uterus, volume, and spread of the disease and its vascularity • Vascularity which is measured by Doppler pulsatility index is an independent risk factor for resistance to single dose methotrexate therapy[22]
5.	Chest X-ray (CXR)	Pulmonary metastases are most common
6.	Magnetic resonance imaging (MRI)	MRI brain is done to look or metastases if the CXR is positive

TABLE 6: The International Federation of Gynecology and Obstetrics (FIGO) scoring system.[23]

Score	*0*	*1*	*2*	*4*
Age in years	<40 years	≥40 years	–	–
Antecedent pregnancy	Male	Abortion	Term	–
Time interval in months between the end of the antecedent pregnancy and start of treatment	<4	4 to less than 7	7 to less than 13	≥13
Human chorionic gonadotropin (hCG) levels prior to the treatment	$<10^3$	10^3 to less than 10^4	10^4 to less than 10^5	$\geq 10^5$
Largest tumor size (including uterus)	<3	3 to less than 5	≥5	–
Metastatic sites	Lung	Kidney and spleen	Gastrointestinal	Liver, brain
Number of metastases	–	1–4	5–8	>8
Previous failed chemotherapy	–	–	Single drug	2 or more drug

Note: A score of 6 or lower is considered as low risk and a score of 7 or higher is considered as high risk.

patient into a low risk category and a high risk category. The management of GTN primarily depends upon the clinical presentation rather than the histology.

About 95% of the patients diagnosed with GTN after hydatidiform mole have low risk neoplasia.[4] The role of D&C in the treatment of GTN is only valuable when the hCG levels is below 5,000 IU/L with disease confined to the endometrium and no invasion to the myometrium. However, the role of second D&C in decreasing the need for chemotherapy

JAYPEE BROTHERS

BOX 1: Chemotherapy for low-risk gestational trophoblastic neoplasia (GTN).

Chemotherapy regimen for low-risk diseases:
- *Methotrexate (MTX)*:* 50 mg by intramuscular infection repeated every 48 hours for a total of four doses
- *Folinic acid*:* 15 mg orally 30 hours after each injection of MTX

Alternative regimens with methotrexate:
- *Methotrexate:* 30–50 mg/m^2 intramuscular (IM) weekly
- *Methotrexate:* 0.3–0.5 mg/kg intravenous (IV) or IM daily for 5 days every 2 weeks (maximum 25 mg per dose)

Methotrexate
- MTX 100 mg/m^2 IV over 30 minutes followed by MTX 200 mg/m^2 IV infusion over 12 hours

Folinic acid
- 15 mg every 12 hours in six doses IM or orally beginning 24 hours after starting MTX

Alternative regimens with actinomycin-D:
- Actinomycin-D 10–12 mg/kg IV push daily for 5 days
- Actinomycin-D 1.25 mg/m^2 IV push every 2 weeks

*Courses every 2 weeks

remains controversial. Meanwhile there are some people who have completed their families and request hysterectomy.

Single agent chemotherapy regimen with methotrexate (MTX) or actinomycin-D (ActD) is traditionally considered as the primary chemotherapy for low risk GTN **(Box 1)**. The MTX/folinic acid regimen developed at Charring Cross Hospital is effective, well tolerated and well accepted. However, it was common to have treatment resistance or side effects. In 2016, an updated Cochrane review[24] was conducted wherein the authors concluded that ActD was more likely to cure disease in the first instance as compared to MTX and was less likely to fail. Also the side effects for both the treatment regimens were similar which were commonly nausea fatigue and anemia. In another Cochrane study published in the same year[25] it was deduced that for cases resistant to MTX or recurrent low risk GTN, a 5-day dactinomycin followed by methotrexate, actinomycin-D, and cyclophosphamide (MAC) or etoposide, methotrexate, actinomycin-D, cyclophosphamide, vincristine (EMA/CO) if required may be given. It was also suggested that dactinomycin for 5 days had more side effects than pulsed dactinomycin. However, RCTs regarding this were still lacking.

Step-by-Step Outline for the Management of Low-risk Gestational Trophoblastic Neoplasia[26,27]

Flowchart 2 presents outline for the management of low-risk GTN.

Management of High-risk Gestational Trophoblastic Neoplasia

High-risk cases of GTN are usually uncommon. A score equal to or above 7 is considered high risk for GTN.[4] These patients are typically at a high risk of developing drug resistance and typically single agent chemotherapy does not work for them. Hence, several different therapies have been developed for them **(Table 7)**.[28]

The EMA/CO regimen was first developed at the Charring Cross Hospital and has been widely accepted.[4] It has a predictable and short-term toxicity profile which is relatively easier to deal with. In a Cochrane study published in 2013, the authors concluded that CHAMOCA regimen was extremely toxic and not better as compared to the MAC regimen. The study could not establish that EMA/CO was the best and the least toxic regimen as compared to others though it suggested that it remains the most widely used regimen in the world for high-risk GTN **(Box 2)**.[29]

JAYPEE BROTHERS

Flowchart 2: Outline for the management of low risk GTN.

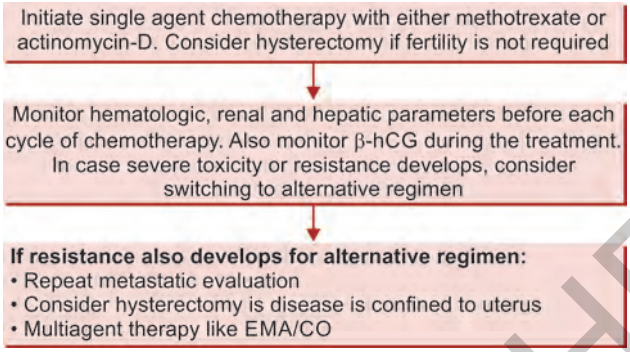

(β-hCG: beta-human chorionic gonadotropin; EMA/CO: etoposide, methotrexate, actinomycin-D, cyclophosphamide, vincristine; GTN: gestational trophoblastic neoplasia)

TABLE 7: Various regimens for treatment of high-risk gestational trophoblastic neoplasia (GTN).

S. No.	*Therapy*	*Short form*
1.	Methotrexate (MTX), folinic acid, and actinomycin-D	MFA
2.	MTX, actinomycin-D, cyclophosphamide, doxorubicin, melphalan, hydroxyurea, and vincristine	CHAMOCA
3.	MTX, actinomycin-D, cyclophosphamide	MAC
4.	Etoposide, MTX, actinomycin-D, cyclophosphamide, vincristine	EMA/CO

BOX 2: The EMA/CO regimens.

Regimen 1

Day 1:

- Etoposide 100 mg/m^2 intravenous infusion over 30 minutes
- Actinomycin-D 0.5 mg intravenous bolus
- Methotrexate 100 mg/m^2 intravenous bolus 200 mg/m^2 intravenous infusion over 12 hours

Day 2:

- Etoposide 100 mg/m^2 intravenous infusion over 30 minutes
- Actinomycin-D 0.5 mg intravenous bolus
- Folinic acid rescue 15 mg intramuscularly or orally every 12 hours for four doses (starting 24 hours after beginning the methotrexate infusion)

Regimen 2

Day 8:

- Vincristine 1 mg/m^2 intravenous bolus (maximum 2 mg)
- Cyclophosphamide 600 mg/m^2 intravenous infusion over 30 minutes
- The two regimens are given alternate weekly.

(EMA/CO: etoposide, methotrexate, actinomycin-D, cyclophosphamide, vincristine)

With the EMA/CO regimen the complete reversal rate was near to 85%. The 5 years survival rates in these cases were 75–80%. However, in those who had distant metastases like in the brain or the liver, prognosis appeared to be somewhat poorer.[29-31]

SUMMARY

- Pre-evacuation diagnosis of molar pregnancy may be made by trends of β-hCG and sonography. However, a definitive diagnosis may be reached only after histological examination.
- Suction curettage is the method of choice of evacuation for complete as well as partial molar pregnancies except when the size of the fetal parts deters the use

JAYPEE BROTHERS

of suction curettage and then medical evacuation can be used.

- Follow-up after gestational trophoblastic disease (GTD) is of prime importance.
- If hCG has reverted to normal within 56 days of the pregnancy event then follow up will be for 6 months from the date of uterine evacuation.
- If hCG has not reverted to normal within 56 days of the pregnancy event then follow-up will be for 6 months from normalization of the hCG level.
- In those patients with gestational trophoblastic neoplasia, the risk stratification according to FIGO scoring should be done and treatment regimen should be chosen accordingly.

CONCLUSION

Gestational trophoblastic diseases are a rare group of diseases wherein majority of them are completely treatable. The key to the treatment here is strict follow-up with beta hCG and early diagnosis of neoplasia. If diagnosed to have neoplasia, risk stratification should be done corresponding treatment should be given.

REFERENCES

1. Bruce S, Sorosky J. Gestational trophoblastic disease. [Updated 2019 Jul 30]. In: StatPearls [Internet]. Treasure Island (FL): StatPearls Publishing; 2019 Jan-. Available from: https://www.ncbi.nlm.nih.gov/books/NBK470267/
2. Bouchard-Fortier G, Covens A. Gestational trophoblastic disease hydatidiform mole, nonmetastatic and metastatic gestational trophoblastic tumor: Diagnosis and management. Comprehensive Gynecology, 7th edition. Amsterdam, Netherlands: Elsevier; 2016. pp. 787-99.
3. Sebire NJ, Foskett M, Fisher RA, et al. Risk of partial and complete hydatidiform molar pregnancy in relation to maternal age. BJOG. 2002;109:99-102.
4. Seckl MJ, Sebire NJ, Fisher RA, et al. Gestational trophoblastic disease: ESMO Clinical Practice Guidelines for diagnosis, treatment and follow-up. Ann Oncol. 2013;24(Suppl 6):vi39-50.
5. Parrazini F, Mangili G, La Vecchia C, et al. Risk factors for gestational trophoblastic disease: a separate analysis of complete and partial hydatidiform moles. Obstet Gynecol. 1991;78:1039-45.
6. Berkowitz RS, Cramer DW, Bernstein MR, et al. Risk factors for complete molar pregnancy from a case-control study. Am J Obstet Gynecol. 1985;152(8):1016-20.
7. Parazzini F, Cipriani S, Mangili G, et al. Oral Contraceptive Pills and risk of gestational trophoblastic disease. Contraception. 2002;65:425-7.
8. Hoffman BL, Schorge JO, Schaffer JL, et al. William's Gynecology, Second edition. The McGraw Hill Companies Inc; 2012.
9. Seckl MJ, Sebire NJ, Berkowitz RS. Gestational trophoblastic disease. Lancet. 2010;376:717-29.
10. Sebire NJ, Seckl MJ. Immunohistochemical staining for diagnosis and prognostic assessment of hydatidiform moles: current evidence and future directions. J Reprod Med. 2010;55:236-46.
11. Wagner BJ, Woodward PJ, Dickey GE. From the archives of the AFIP. Gestational trophoblastic disease: radiologic-pathologic correlation. Radiographics. 1996;16(1):131-48.
12. Allen SD, Lim AK, Seckl MJ, et al. Radiology of gestational trophoblastic neoplasia. Clin Radiol. 2006;61(4):301-13.
13. Dhanda S, Ramani S, Thakur M. Gestational trophoblastic disease: A multimodality imaging approach with impact on diagnosis and management. Radiol Res Pract. 2014;2014:842751.
14. RCOG. (2010). Gestational Trophoblastic Disease (Green-top guideline No. 38). [online] Available from https://www.rcog.org.uk/en/guidelines-research-services/guidelines/gtg38/ [Last accessed September, 2019].
15. Fowler DJ, Lindsay I, Seckl MJ, et al. Routine pre-evacuation ultrasound diagnosis of hydatidiform mole: experience of more than

JAYPEE BROTHERS

1000 cases from a regional referral center. Ultrasound Obstet Gynecol. 2006;27(1):56-60.
16. Berek JS. Berek and Novak's Gynecology. Fifteenth edition. Philadelphia. Wolters Kluwer India Private Limited; 2012.
17. Gerulath AH, Ehlen TG, Bessette P, et al. Gestational Trophoblastic Disease. J Obstet Gynaecol Can. 2002;24:434-9.
18. Wang Q, Fu J, Hu L, et al. Prophylactic chemotherapy for hydatidiform mole to prevent gestational trophoblastic neoplasia. Cochrane Database Syst Rev. 2017;9:CD007289.
19. Jelly P, Rakesh S. Gestational trophoblastic disease (GTD). Int J Med Paediatr Oncol. 2016;2(2):70-3.
20. Ngan HY, Seckl MJ, Berkowitz RS, et al. Update on the diagnosis and management of gestational trophoblastic disease. Int J Gynecol Obstet. 2015;131 (Suppl 2):S123-6.
21. Kani KK, Lee JH, Dighe M, et al. Gestational trophoblastic disease: multimodality imaging assessment with special emphasis on spectrum of abnormalities and value of imaging in staging and management of disease. Curr Probl Diagn Radiol. 2012;41(1):1-10.
22. Agarwal R, Harding V, Short D, et al. Uterine artery pulsatility index: a predictor of methotrexate resistance in gestational trophoblastic neoplasia. Br J Cancer. 2012;106:1089-94.
23. FIGO Oncology Committee. FIGO staging for gestational trophoblastic neoplasia 2000. Int J Gynecol Obstet. 2002;77:285-7.
24. Lawrie TA, Alazzam M, Tidy J, et al. First-line chemotherapy in low-risk gestational trophoblastic neoplasia. Cochrane Database Syst Rev. 2016;(6):CD007102.
25. Alazzam M, Tidy J, Osborne R, et al. Chemotherapy for resistant or recurrent gestational trophoblastic neoplasia. Cochrane Database Syst Rev. 2016;(1):CD008891.
26. Soper JT, Spillman M, Sampson JH, et al. High-risk gestational trophoblastic neoplasia with brain metastases: individualized multidisciplinary therapy in the management of four patients. Gynecol Oncol. 2007;104(3): 691-4.
27. Deng L, Yan X, Zhang J, et al. Combination chemotherapy for high-risk gestational trophoblastic tumour. Cochrane Database Syst Rev. 2009;(2):CD005196.
28. Deng L, Zhang J, Wu T, et al. Combination chemotherapy for primary treatment of high-risk gestational trophoblastic tumour. Cochrane Database Syst Rev. 2013;(1): CD005196.
29. Ahamed E, Short D, North B, et al. Survival of women with gestational trophoblastic neoplasia and liver metastases: is it improving? J Reprod Med. 2012;57(5-6):262-9.
30. Neubauer NL, Latif N, Kalakota K, et al. Brain metastasis in gestational trophoblastic neoplasia: an update. J Reprod Med. 2012;57 (7-8):288-92.
31. Newlands ES, Holden L, Seckl MJ, et al. Management of brain metastases in patients with high-risk gestational trophoblastic tumors. J Reprod Med. 2002;47(6):465-71.

JAYPEE BROTHERS

for detailed information on obstetrics & gynecology books, visit our website www.jaypeebrothers.com, for detailed information on obstetrics & gyn

GYNECOLOGICAL EMERGENCIES

Salient Features

- An invaluable reference guide for students and gynecologists
- Covers management of all Gynecological Emergencies in a simple and precise manner
- New modernized version incorporating evidence-based practice guidelines using diagrams, user-friendly flowcharts and tabulated data
- Special emphasis given to ethical and medicolegal issues, clinical emergencies associated with puberty, menstruation and menopause with the appropriate investigations and management strategies
- Concise yet updated algorithms that were the hallmark of success for the first edition.

Kamini A Rao DGO DORCP DCh FRCOG (UK) MCh (UK) FRCOG PGDMLE (Law) FNAMS a pioneer of the assisted reproduction fraternity in India is the Medical Director of Milann—The Fertility Center, Bengaluru, Karnataka, India and a recipient of the Padma Shree. Her vision for developing the reproductive medicine talent in the country led to the setting up of a strong education vertical which is affiliated to Milann (A unit of BACC Healthcare), and is considered to be amongst the country's premier institutions for education and training in reproductive medicine. Being academically oriented, she has authored nearly 50 medical textbooks and a large number of journals and chapter publications. She served as the President of the Federation of Obstetric and Gynaecological Societies of India (FOGSI) in the year 2000 as well as the President of the Indian Society for Assisted Reproduction (ISAR) between 2006 and 2008. She is the Member of the Central Supervisory Board, Government of India, for implementation of the Prenatal Diagnostic Techniques (PNDT) Act, the National Apex Committee for Stem Cell Research and Therapy, and the Drafting Committee for formulating national guidelines for "Accreditation, Supervision and Regulation of ART Clinics in India".

Arveen Vohra MBBS MS (Obs & Gyn) Fellowship in Reproductive Medicine (FRM) is Fertility Specialist, the Clinical Director and Senior Consultant in Reproductive Medicine at Milann—The Fertility Center, Indiranagar, Bengaluru, Karnataka, India. Her areas of expertise include Reproductive physiology and endocrinology, Ultrasound in ART, Mild stimulation in ART, Poor responders, Endometrial receptivity, PCOS, Counseling, and Fertility preservation. She is passionate about teaching and is actively involved in education programs for clinicians and embryologists. She has also been a part of organizing teams and faculty for various National and International Conferences in the field of OBG. She has authored many chapters in various textbooks and contributed extensively to the curriculum and chapters for nationally recognized textbooks in Reproductive Medicine. She has to her credit many publications in various international indexed journals. She was a Gold Medalist during her MS (OBG), a recipient of Mrs Indumati Jhaveri Prize for Best Original Research Paper for her presentation at the 53rd AICOG, Guwahati in January 2010 and recipient of the First Prize for Best Original Research Paper for her presentation at the 53rd KSOGA, Hassan, Karnataka in 2010.

Available at all medical bookstores
or buy online at www.jaypeebrothers.com



JAYPEE BROTHERS
Medical Publishers (P) Ltd.
www.jaypeebrothers.com

Join us on facebook.com/JaypeeMedicalPublishers

Shelving Recommendation
OBSTETRICS & GYNECOLOGY

