y books, visit our website www.ejaypee.com, for detailed information on cardiology books, visit our website www.ejaypee.com, for detailed information on cardiology books

ECG in Medical Practice

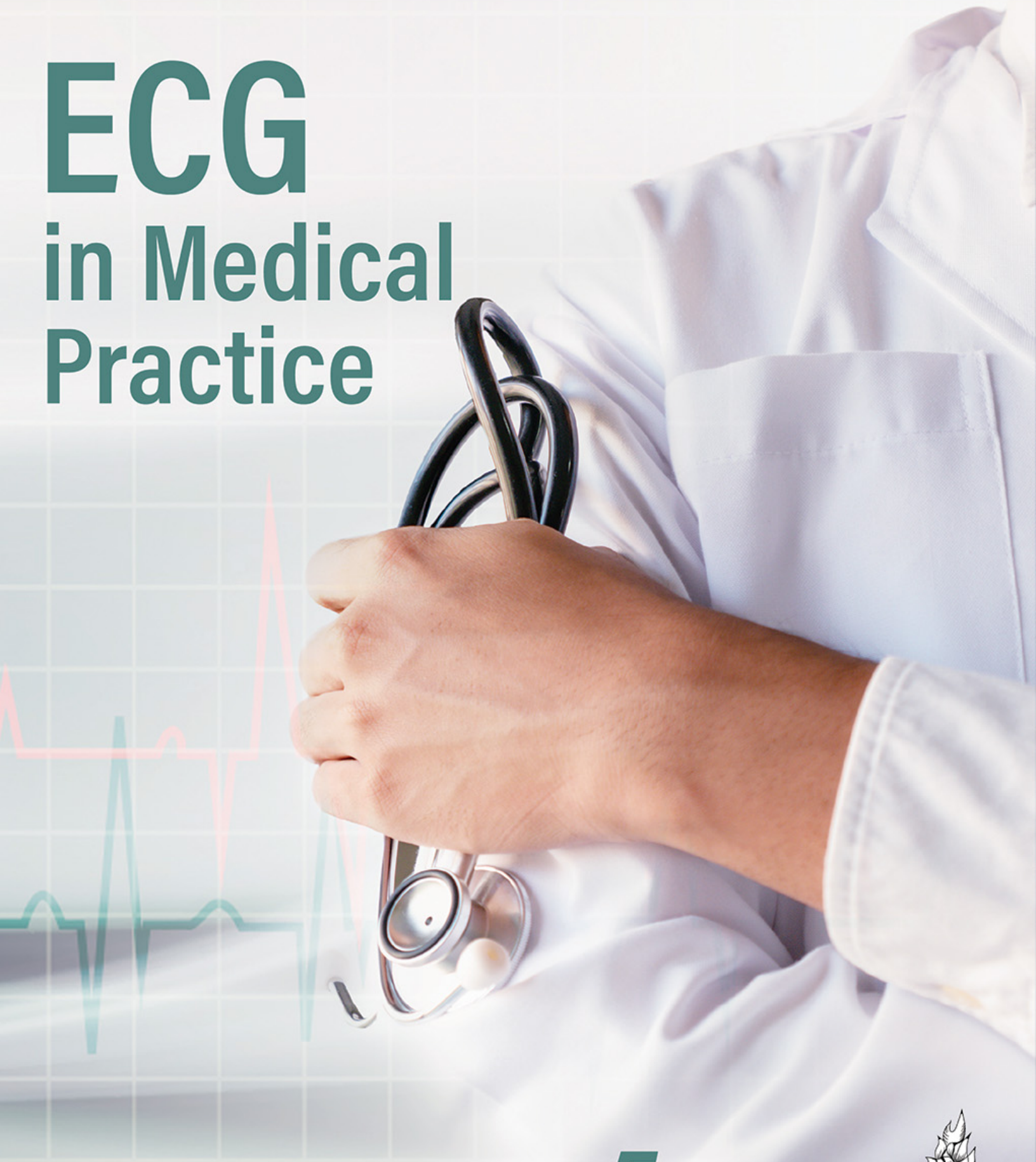

ABM Abdullah

5th Edition

JAYPEE

Contents

Chapter 1: Basic Concepts of ECG 1

- Specialized Conductive System of The Heart *3*
- Anatomy of Conductive Tissue *4*
- Coronary Circulation *5*
- Properties of Cardiac Muscles *6*
- Nerve Supply of The Heart *6*
- Electrocardiogram *7*
- Before Interpretation of Electrocardiogram *10*
- Brief Discussion About Electrocardiogram Paper *11*
- Normal Electrocardiogram *14*
- Intervals In Electrocardiogram *16*
- Brief Discussion of Waves and Intervals in Electrocardiogram *17*
- Rhythm of Heart *32*
- Calculation of Heart Rate *33*
- Cardiac Axis *34*
- Normal Variants In Electrocardiogram *37*
- Exercise Electrocardiogram (Exercise Tolerance Test or ETT) *38*
- Holter Monitoring (Ambulatory Electrocardiogram) *40*

Chapter 2: ECG Changes in Different Diseases 41

- Left Ventricular Hypertrophy *43*
- Right Ventricular Hypertrophy *46*
- Biventricular Hypertrophy (Combined Left Ventricular Hypertrophy and Right Ventricular Hypertrophy) *49*
- Left Atrial Hypertrophy *50*
- Right Atrial Hypertrophy *51*
- Combined Left and Right Atrial Hypertrophy (Biatrial Hypertrophy) *53*
- Sinus Arrhythmia *54*
- Sinus Tachycardia *55*
- Sinus Bradycardia *58*
- Supraventricular Tachycardia *60*
- Atrial Tachycardia *64*
- Nodal Rhythm (Junctional Rhythm) *66*
- Wandering Pacemaker *68*
- Atrial Fibrillation *70*
- Ashman Phenomenon (Ashman Beats) *74*
- Atrial Flutter *75*
- Ectopic Beat *77*
- Atrial Ectopic *79*
- Ventricular Ectopic *80*
- Ventricular Bigeminy *84*
- Ventricular Trigeminy *86*

- Ventricular Quadrigeminy *86*
- Ventricular Pentageminy *87*
- Ventricular Hexageminy *87*
- Ventricular Tachycardia *88*
- Torsades De Pointes *91*
- Ventricular Fibrillation *93*
- Ventricular Flutter *94*
- Heart Block *95*
- SA Block 98
- Sick Sinus Syndrome *100*
- Atrioventricular Block (AV Block) *102*
- First-Degree AV Block *102*
- Second-Degree AV Block *103*
- Complete Heart Block (3rd Degree) *105*
- Atrioventricular Dissociation *108*
- Bundle Branch Block *110*
- Fascicular Block (Hemiblock) *112*
- Left Bundle Branch Block *115*
- Myocardial Infarction *117*
- Myocardial Ischemia *128*
- Ventricular Aneurysm *131*
- Acute Pericarditis *133*
- Pericardial Effusion *135*
- Wolff–Parkinson–White Syndrome *137*
- Lown–Ganong–Levine Syndrome *141*
- Pacemaker *142*
- Digoxin Effect *147*
- Hypokalemia *150*
- Hyperkalemia *152*
- Hypermagnesemia *155*
- Hypomagnesemia *156*
- Hypocalcemia *157*
- Hypercalcemia *159*
- Pulmonary Embolism *161*
- Dextrocardia *164*
- Hypothermia *166*
- Chronic Obstructive Pulmonary Disease *167*
- Atrial Septal Defect *168*
- Hypothyroidism *170*
- Hyperthyroidism *171*
- Pulseless Electrical Activity or Electromechanical Dissociation *172*
- Raised Intracranial Pressure *173*

Chapter 3: 151 Tracings of ECG 174

- Findings of ECG Tracings *327*

Suggested Reading *345*

Index *347*

CHAPTER 3

151 Tracings of ECG

"Most of the doctors can competently interpret ECG without getting submerged in its complexities"

Remember "there is no need for the ECG to be daunting: Just as most people drive car without knowing much about the engines and the gardeners do not necessarily need to be a botanist"

JAYPEE BROTHERS

151 ECG tracings are included here.
The reader should interpret by himself and then
compare the findings given in the last pages.
In this way, it will offer a good
self-learning and exercise in ECG.

JAYPEE BROTHERS

ECG No. 1

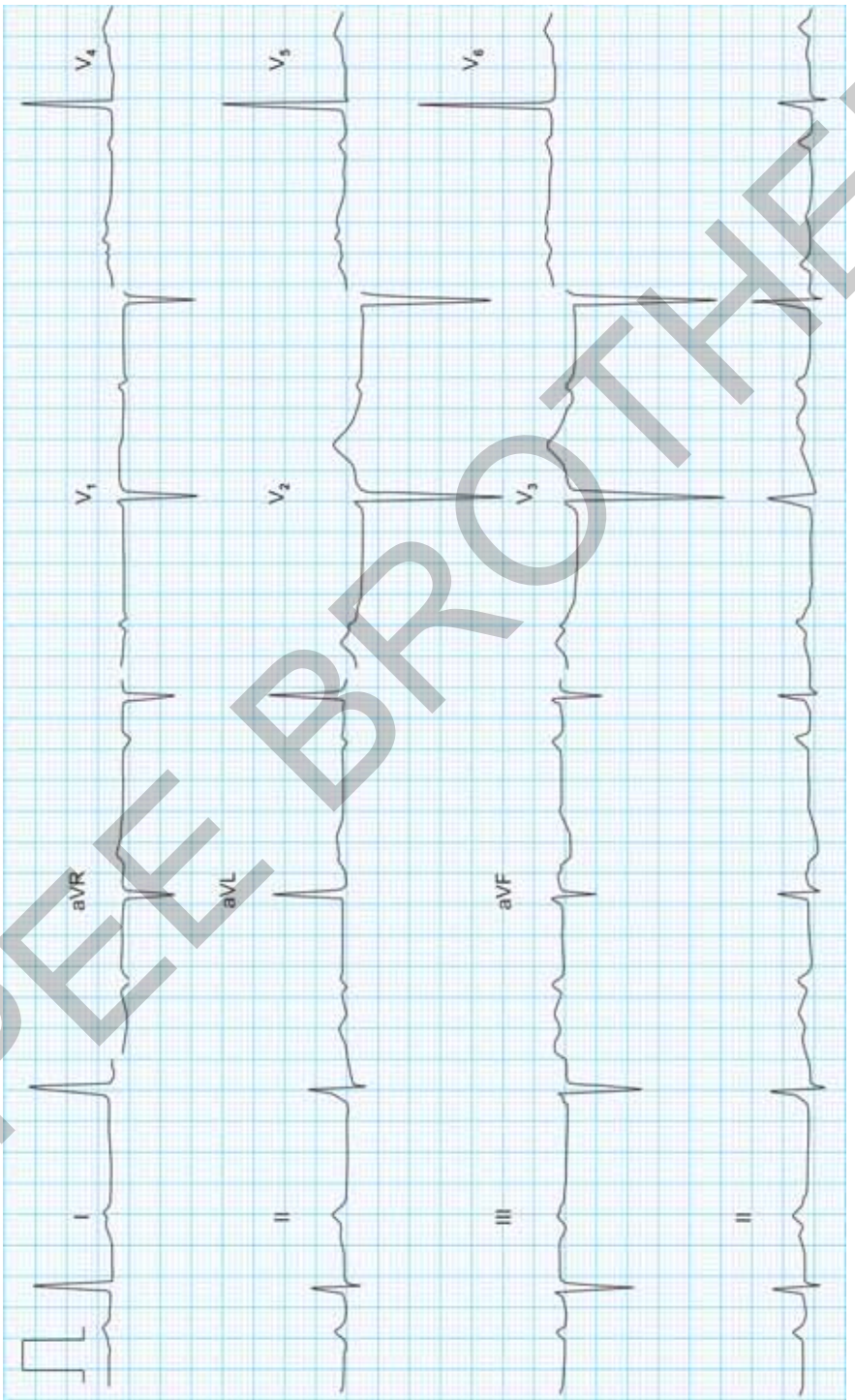

JAYPEE BROTHERS

ECG No. 2



JAYPEE BROTHERS

ECG No. 3

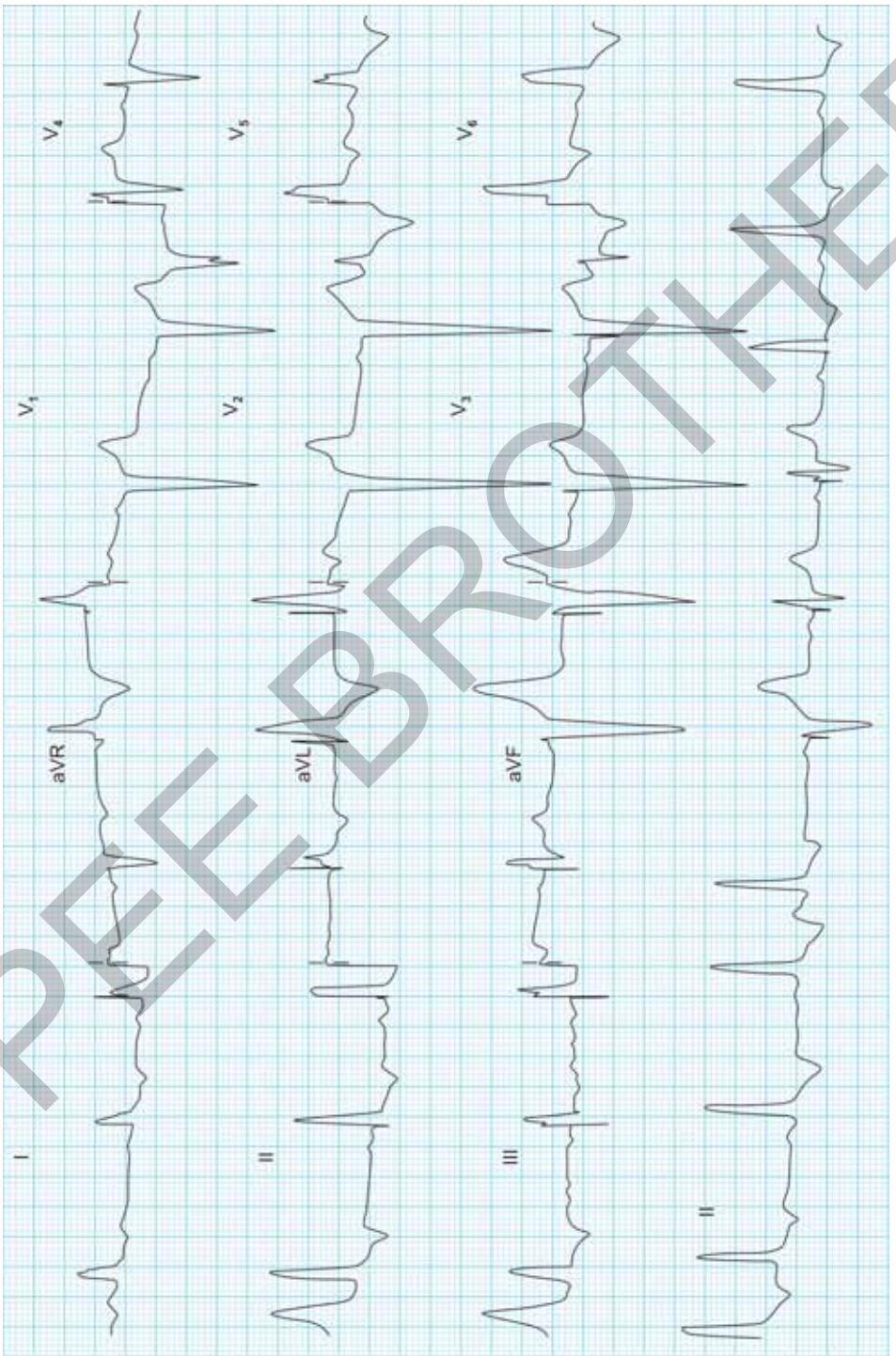

JAYPEE BROTHERS

ECG No. 4

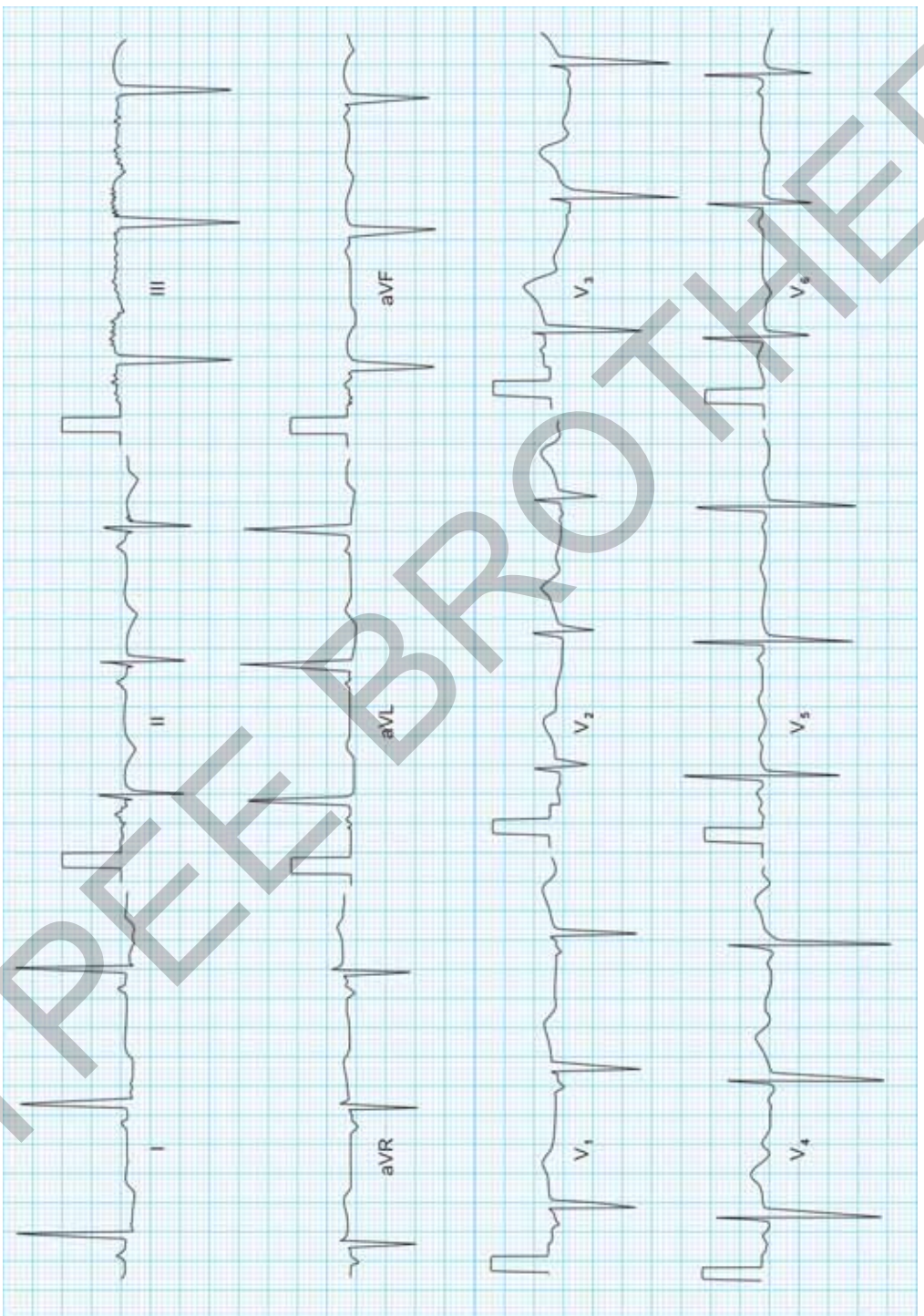

JAYPEE BROTHERS

FINDINGS OF ECG TRACINGS

1. This electrocardiogram (ECG) shows:
   - Atrial rate—75/min
   - Ventricular rate—50/min
   - There is complete dissociation between P and QRS

Diagnosis: Complete heart block.

2. This ECG shows:
   - P wave—absent
   - RR interval—irregular (rhythm irregular)
   - Heart rate >100 beats/min

Diagnosis: Fast atrial fibrillation (atrial fibrillation with rapid ventricular response).

3. This ECG shows:
   - Pacemaker spike followed by QRS
   - In some leads, there are no spikes which indicate demand pacemaker

Diagnosis: Single chamber demand ventricular pacemaker.

4. This ECG shows:
   - Pathological Q in lead III and aVF
   - Tall R in lead I and deep S in aVF (indicates left axis deviation)
   - Tall R (19 mm) in aVL (left ventricular hypertrophy)
   - U wave in V_4 and V_5

Diagnosis: Old inferior myocardial infarction, left ventricular hypertrophy with hypokalemia.

5. This ECG shows:
   - $SV_1 + RV_6$ >35 (here 48)
   - T inversion in lead I, aVL, V_2–V_6

Diagnosis: Left ventricular hypertrophy with strain.

Ques. Is there any other criteria of left ventricular hypertrophy in this ECG?

Ans. Yes. There is tall R (33 mm) in V_5 (R >25 in V_5 indicates left ventricular hypertrophy).

Ques. What is the differential diagnosis in this type of ECG?

Ans. Hypertrophic cardiomyopathy (echocardiogram should be done to confirm the diagnosis).

6. This ECG shows:
   - Heart rate—150 beats/min
   - P, QRS, and T—normal
   - Rhythm—regular

Diagnosis: Sinus tachycardia.

7. This ECG shows:
   - Heart rate—124 beats/min
   - Pathological Q in lead II, III and aVF, also in V_1–V_5
   - ST elevation in V_2–V_5

Diagnosis: Acute anterior and old inferior myocardial infarction with sinus tachycardia.

8. This ECG shows:
   - Tall P in lead II and III (P pulmonale)
   - Q wave in lead II, III and aVF
   - Tall R in V_1
   - Poor R wave progression in V_5 and V_6

Diagnosis: Right atrial hypertrophy (P pulmonale) with right ventricular hypertrophy with old inferior myocardial infarction.

JAYPEE BROTHERS

9. This ECG shows:
   - Short PR interval (0.08 second)
   - Delta wave in lead I, aVL, V_2–V_6
   - Deep S in V_1
   - Q in lead III and aVF—confuses with old inferior myocardial infarction

Diagnosis: Wolff–Parkinson–White (WPW) syndrome type B.

10. This ECG shows:
   - P wave—absent
   - Rhythm is irregular (RR interval is irregular)
   - ST depression in lead I, II, V_4–V_6 (thumb impression or reversed tick appearance)
   - Heart rate is 160 beats/min

Diagnosis: Fast atrial fibrillation with digoxin effect.

11. This ECG shows:
   - Pathological Q in V_1–V_4
   - ST elevation in V_2–V_4
   - T inversion in lead I, aVL, V_2–V_6

Diagnosis: Acute anteroseptal myocardial infarction.

12. This ECG shows:
   - Pathological Q in V_1–V_6
   - ST elevation in V_2–V_6

Diagnosis: Acute extensive anterior myocardial infarction.

13. This ECG shows:
   - Tall R in lead I and deep S in lead aVF (indicates left axis deviation)
   - Deep T inversion in lead I, II, aVL, V_2–V_6

Diagnosis: Subendocardial myocardial infarction or non-ST-elevation myocardial infarction (non-STEMI).

Differential diagnosis: Hypertrophic cardiomyopathy.

14. This ECG shows:
   - Pacemaker spike in V_4–V_6 followed by QRS
   - No spike in other leads

Diagnosis: Single chamber ventricular pacemaker.

15. This ECG shows:
   - Pacemaker spike in almost all the leads followed by QRS

Diagnosis: Single chamber ventricular pacemaker.

16. This ECG shows:
   - P wave—absent
   - Flutter wave in V_1–V_3
   - Rhythm—irregular
   - Ventricular ectopic (in some leads)

Diagnosis: Atrial flutter fibrillation with multiple ventricular ectopics.

17. This ECG shows:
   - P wave—absent
   - QRS normal and narrow
   - Rhythm—irregular (RR irregular)
   - Heart rate—160 beats/min

Diagnosis: Fast atrial fibrillation.

Differential diagnosis: Supraventricular tachycardia with variable block.

JAYPEE BROTHERS

detailed information on cardiology books, visit our website www.ejaypee.com, for detailed information on cardiology books, visit our website www.ejaypee.com, for detailed

ECG in Medical Practice

Key Features

- An easy, simple, and practical book on ECG with basic concepts and their interpretation
- Good learning tool for beginners in medicine and allied subjects
- Contains full information regarding cardiac and extracardiac diseases which show ECG changes
- Contains complete outline of ECG changes in different diseases, which is described first followed by the diagnosis and brief description of the disease with related questions-answers
- Includes 151 ECG tracings for self-assessment in a separate chapter
- Helpful for undergraduate and postgraduate students and teachers, doctors, and busy practitioners to refresh their memory without going through a voluminous textbook.

ABM Abdullah MRCP (UK), FRCP (Edin) Ex-Chairman Department of Medicine and Ex-Dean, Faculty of Medicine, Bangabandhu Sheikh Mujib Medical University, Dhaka, Bangladesh, was honored as "UGC Professor" (University Grant Commission Professor) in 2019. In 2020, he has been appointed as Personal Physician to the Honorable Prime Minister of Bangladesh.

He has a good number of publications, among which 41 research articles have been published in various nationally and internationally renowned journals. Apart from this book "ECG in Medical Practice," he is the author of six other highly praised and well-accepted medical books, which are entitled as *Short Cases in Clinical Medicine, Long Cases in Clinical Medicine, Radiology in Medical Practice, Practical Manual in Clinical Medicine, Case History and Data Interpretation in Medical Practice* and *Practical Standard Prescriber*. He has written two other books in Bengali which are also highly appreciated by all classes of people.

He is continuously writing common medical articles, which are being published in several reputed daily newspapers. For research and academic activities, he has been honored with five awards—"Ekushey Padak 2016 (which is the highest prestigious state award)," "University Grants Commission Award 2013," "Honorary Fellowship by Bangla Academy 2017," "Mercantile Bank Award 2016," and "Bangla Darpan Sommanona 2016".

Shelving Recommendation
CARDIOLOGY

ISBN 978-93-89587-25-8
9 789389 587258

Buy from ejaypee

JAYPEE BROTHERS