nation on radiology books, visit our website www.jaypeebrothers.com, for detailed information on radiology books, visit our website www.jaypeebrothers.com



Essentials of
Breast Imaging

Smiti Sripathi
Aron Sraj

Foreword
Sabita Desai

JAYPEE

Contents

1. Anatomy of Breast and Pathophysiology of Breast Diseases **1**

2. Mammography **10**

2.1 Technique and Positioning 10
2.2 Quality Assurance in Mammography 24
2.3 Approach to Reading a Mammogram 27
2.4 The Breast imaging-reporting and Data System (BI-RADS) Classification 31
2.5 Breast Calcifications 49
2.6 Digital Breast Tomosynthesis 60

3. Ultrasound **62**

3.1 Equipment and Technique 62
3.2 Breast imaging-reporting and Data System (BI-RADS) Classification 69
3.3 Ultrasound Features of Breast Masses 86
3.4 Evaluation of Nipple: Areolar Region 89
3.5 Evaluation of Axilla 106
3.6 Newer Techniques 118

4. Magnetic Resonance Imaging **121**

4.1 Image Acquisition and Indications 121
4.2 Breast imaging-reporting and Data System (BI-RADS) Lexicon 125
4.3 Multimodality Evaluation of Breast Lesions 132

5. Inflammatory Conditions of Breast **139**

6. Male Breast **152**

7. Imaging of Postoperative Breast **163**

8. Breast Implants **184**

9. Breast Interventions **196**

9.1 Breast Interventions and Modalities Used for Imaging 196
9.2 Fine Needle Aspiration Cytology (FNAC) and Core Needle 202
9.3 Radiologic Pathologic Concordance and Discordance 206

10. Uncommon Diseases of Breast **209**

10.1 The Paget Disease of Breast 209
10.2 Cystosarcoma Phyllodes 212
10.3 Lobular Carcinoma 214
10.4 Metaplastic Carcinoma 217
10.5 Lymphoma 219
10.6 Angiosarcoma 220
10.7 Pseudoangiomatous Stromal Hyperplasia 221
10.8 Mondor Disease 222

Mammography

CHAPTER 2

2.1 Technique and Positioning

INTRODUCTION

Mammography has been long the imaging modality of choice for early detection of breast cancer all over the world as it is the most common malignancy in women.[1]

It is important to obtain good quality images including maximum tissue so that accurate diagnosis can be made. A complete clinical history with a good quality mammogram is a prerequisite for proper interpretation of the images.

With the increased number of breast cancer's cases in India, we do not need only breast radiologists but also trained technologists to obtain optimal quality mammograms so that early breast cancer can be detected. It is imperative that budding breast radiologists also learn techniques and positioning of mammography properly to guide their radiographers.

There is tremendous improvement in both hardware and software of mammography over the last few years, thereby improving image quality. The factors that need to be taken care of are adequate compression and correct positioning and therefore a good technologist is a must.

It is worth remembering what Dr Eklund said, "Bad mammography cannot be perceived without the knowledge of good mammography." One must follow the standards of positioning to get good quality mammograms so that "the cancer is not left behind in the mammography room." A badly taken mammogram can result in a blurred image, whereas a properly taken mammogram shows a detailed map of breast, which will prove to be a huge difference between life and death. One must not forget that sometimes subtle changes in breast architecture can be the only sign of cancer. Remember, no matter how many mammograms are done that day, the patient is receiving her first and only mammogram of the year.

Screen Film Mammography

This has been used for a long time all over the world. It helps in detecting early breast cancer as microcalcifications are seen well because of high spatial resolution.[2] Contrast resolution is a limitation and especially so in women with dense breasts. Because of this, it has a lower sensitivity (62.9%) in dense breast as compared to fatty breast (87%).[3]

It is extremely important that dedicated equipment for mammography should be used.

Those with computed radiography (CR)-based system should use high-resolution cassettes (20 pixel/mm) and CR reader.

Full-field Digital Mammography

Digital radiography began once the transfer of images to digital format started. Slowly the digital technology started getting adopted by other imaging modalities. The first full-field digital mammography (FFDM) unit was approved for sale by the Food and Drug Administration in 2000.[4]

Digital mammography has several advantages over screen film mammography that include:

- Easier access to images and computer-assisted diagnosis
- Better transmission, retrieval and storage of images
- Lower average radiation dose without a compromise in diagnostic accuracy.

The workflow in digital mammography is more effective[5] and the time taken to perform it is reduced.[6] The storage space required is also less as compared to screen film mammography. In women with dense breast and in younger women, digital mammography is more accurate.[7]

This may be because of dynamic range of digital mammography as it captures contrasting densities and displays them without compromising the contrast resolution very much.

JAYPEE BROTHERS

TECHNIQUE AND POSITIONING: AN OVERVIEW

Patient preparation: Mammogram should be done after the menstrual phase. There is no specific preparation required for a mammography, but it is always better if the patient is told about the procedure beforehand to reduce apprehension. The patient should be asked to avoid using talcum powder on the day of examination as it can produce artifacts. A proper clinical history and indication for mammogram is mandatory. The patient should be asked to bring previous mammograms for comparison.

Positioning: Proper positioning of breast is very important for optimum mammogram quality and maximizes the amount of tissue obtained. Proper attention during positioning eliminates most of the artifacts and increases the diagnostic accuracy of mammography. Since body habitus of each individual is different, adjustments have to be made in positioning for maximum tissue visualization. For example, the head should be turned for craniocaudal (CC) view, arm should be raised for mediolateral oblique (MLO) view and any injury to shoulder and arm should be avoided.

Two of the most important principles of breast positioning are (1) the mobile tissues have to be moved toward fixed tissue and (2) the compression paddle should not be moved against fixed tissue; hence, these principles should be adhered to during mammography positioning. One should remember that inferior and lateral portions of breast are mobile and medial and superior portion are fixed.

Role of breast compression: Breast compression is very important during mammography as it improves image quality by preventing overlapping of structures and produces sharper images.

This is because of the following reasons:

- The breast thickness is reduced during compression that reduces ratio of scatter radiation to primary radiation, thereby improving subject contrast
- The structures in breast are brought closer to image receptor; hence, geometric blurring is reduced
- The uniform breast thickness results in even penetration and uniform radiographic density
- Compression causes immobilization of breast and reduces motion blur
- The spreading of the breast tissue during compression reduces superimposition of breast tissue enabling suspicious lesions to be more easily identified
- Both image unsharpness and radiation dose are reduced.

The failure in optimal positioning and compression are operator dependent and can be avoided by proper training.

Standard mammographic views: There are two standard views:

1. Craniocaudal view
2. Mediolateral Oblique (45 degrees) view

Additional views

- Extended CC view
- True lateral view
- Axillary view (Cleopatra view)
- Cleavage view/valley view
- Spot compression view
- Magnification view
- Rolled view
- Tangential view
- Caudocranial or from below view
- Eklund view for implants.

STANDARD MAMMOGRAPHIC VIEWS

Craniocaudal View

This view is one of the standard views and guidelines for positioning must be followed while doing it (Fig. 1A).

Technique

- Technologist should stand on medial side of patient and film tray should be raised to the height of inframammary crease/fold. The patient should be asked to take half step away from the receptor or film tray and breast should be placed on the image receptor
- The patient is then asked to lean forward toward receptor—chest forward and hip backward and head is brought around side of a tube
- The breast is pulled laterally and nipple is centered and placed in profile
- The breast tissue is pulled toward nipple and taut compression is applied at the same time
- Wrinkles and folds on the skin should be smoothened out
- Marker should be placed at axilla

Once the above steps are done, a good quality CC view is produced (Fig. 1B).

JAYPEE BROTHERS

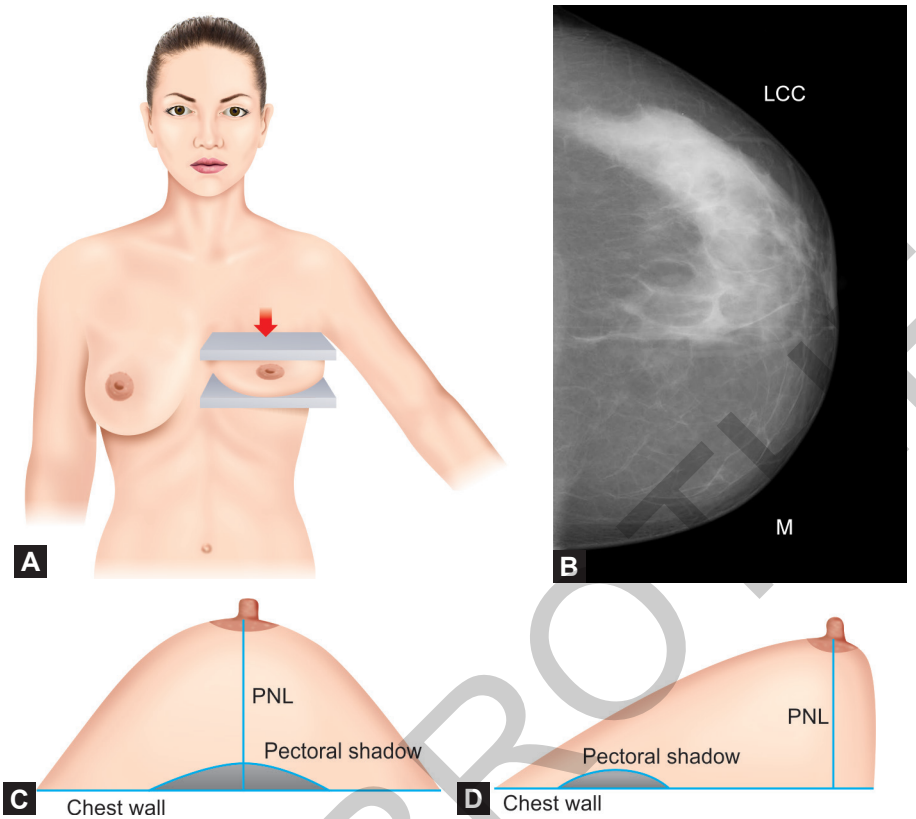

Figs. 1A to D: (A) Positioning for CC view; (B) Mammogram image showing correctly positioned CC view; (C) PNL on a correctly positioned CC view; (D) PNL on a badly positioned CC view. (CC: craniocaudal; PNL: posterior nipple line).

CHECKLIST FOR A PROPER CRANIOCAUDAL VIEW

1.	Uniform tissue thickness
2.	Visualization of central, subareolar and medial aspect of breast
3.	Posterior most extent of breast are covered adequately
4.	Retroglandular fat is well seen
5.	No skin folds are present
6.	No artifacts are present
7.	Pectoral muscle is seen in 30–40% cases
8.	Posterior nipple line (PNL) is within 1 cm on mediolateral oblique (MLO) view

Posterior nipple line is a line drawn posteriorly from the nipple towards the pectoral muscle on mammogram. In an adequately positioned breast, the difference in measurement of this line in CC and MLO view should be <1 cm (Figs. 1C and D).

Mediolateral Oblique (MLO) or Lundgren's View

This is the second standard view (Fig. 2A) done on mammogram.

Technique

- The plane of the image receptor is between 30 and 60° to the horizontal so that it is parallel to pectoralis muscle. The angle can differ depending upon the built of the patient.
  - For average height and built patients: 40–50°
  - For tall and thin patients: 50–60° (steeper angle)
  - For short patients: 30–40°.
- The top of image receptor should be kept at axilla, following which the breast should be lifted and both pectoralis muscle and breast should be pulled anteriorly and medially. The breast should be held away from the chest wall and compression should be then applied. The upper corner of the compression paddle should be just below the clavicle. It is important to ensure that nipple is in profile and marker is kept at axilla. While the hand is moved out

JAYPEE BROTHERS

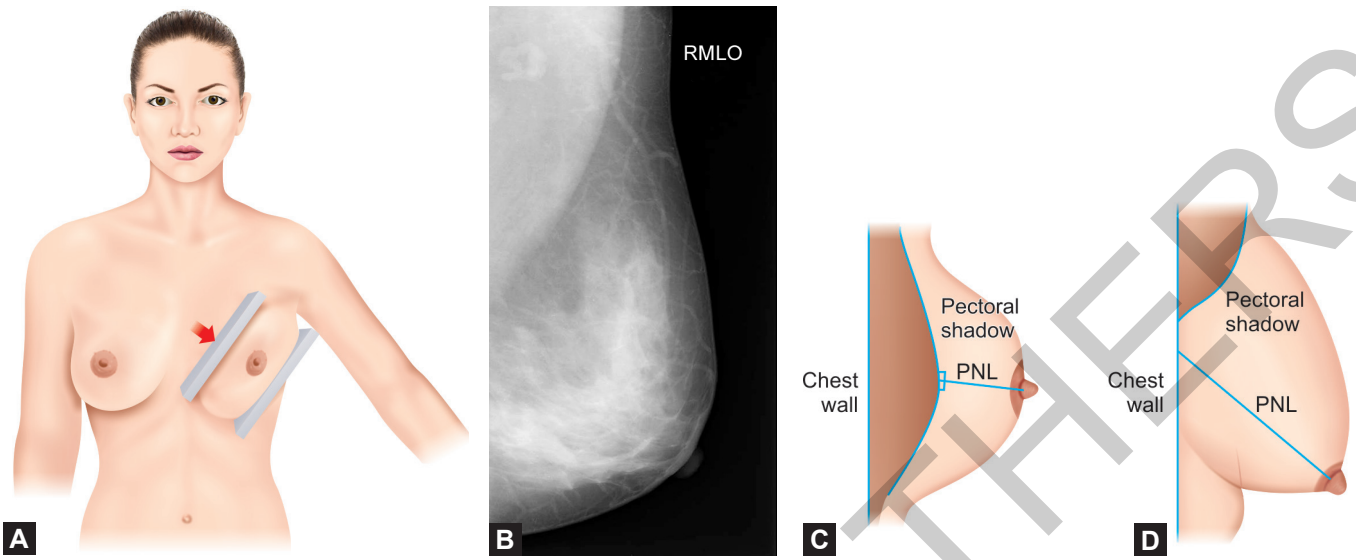

Figs. 2A to C: (A) Positioning for MLO view; (B) Mammogram image showing correctly positioned MLO view; (C) PNL on a correctly positioned MLO view; (D) PNL on a badly positioned MLO view. (MLO: mediolateral oblique; PNL: posterior nipple line).

of the field, anterior portion of the breast should be supported and at the same time abdominal tissue should be pulled down to open inframammary fold. The entire breast from infra mammary fold to the axilla must be centered on the image receptor. The patient is asked to hold on to the bar with the ipsilateral arm.

Once the above steps are followed, a properly taken MLO view is obtained (Fig. 2B).

CHECKLIST FOR PROPER MEDIOLATERAL OBLIQUE VIEW

1.	Breast supported up and away from thorax and perpendicular to chest wall
2.	Visualization of retroglandular fat
3.	Inframammary fold should open out
4.	Nipple should be in profile
5.	Pectoralis muscle should be well seen. It is wide superiorly with a convex anterior border extending to or below the posterior nipple line
6.	No artifacts
7.	No skin folds

ADDITIONAL MAMMOGRAPHIC VIEWS

Lateral View

This is the most commonly done additional view. It is a 90° true lateral view and can be mediolateral (Figs. 3A and B) or lateromedial view (Fig. 4).

It is done commonly before stereotactic biopsy to decide upon the approach.

It is used to triangulate the exact location of lesion in the breast.

To see calcification due to milk of magnesia (tea-cup calcification).

Technique (90° Mediolateral View)

- The image receptor is at 90° to horizontal
- Confirm true lateral (90°) position
- Compression is applied
- Nipple should be in profile
- Marker should be placed at axilla.

Extended CC View

This view depicts lesions in deeper outer portion of breast including the axillary tail (Figs. 5A and B). The nipple should be in profile. Sometimes pectoralis muscle may be seen.

Technique

The patient should be positioned as in CC view after which the inframammary fold should be elevated and the patient is rotated till lateral aspect of breast is positioned on the receptor. A 5° lateral rotation should be given to remove the shoulder from the way. Both the shoulders should be at the same level.

JAYPEE BROTHERS

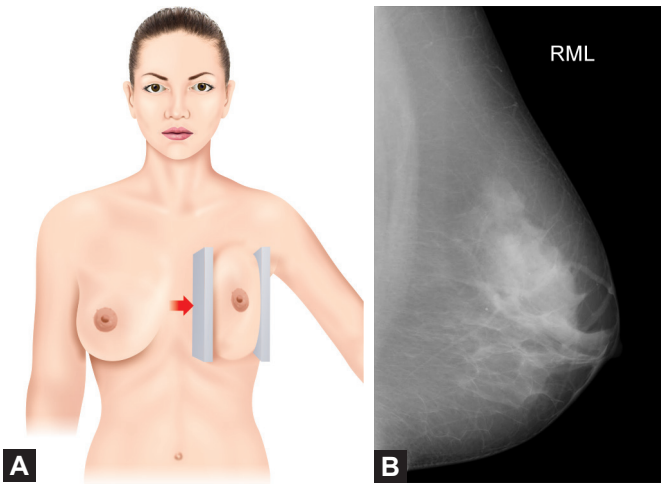

Figs. 3A and B: (A) Positioning for 90° mediolateral view; (B) Mammogram showing correctly positioned ML (Mediolateral view). (MLO: mediolateral oblique).

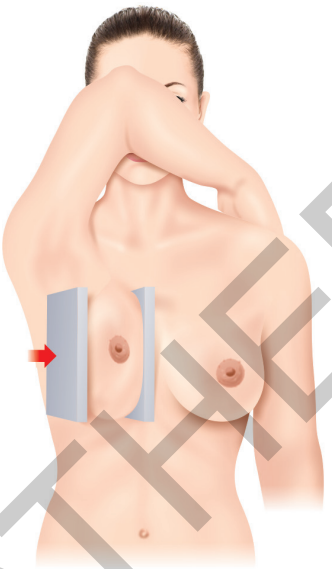

Fig. 4: Positioning for 90° lateromedial view.

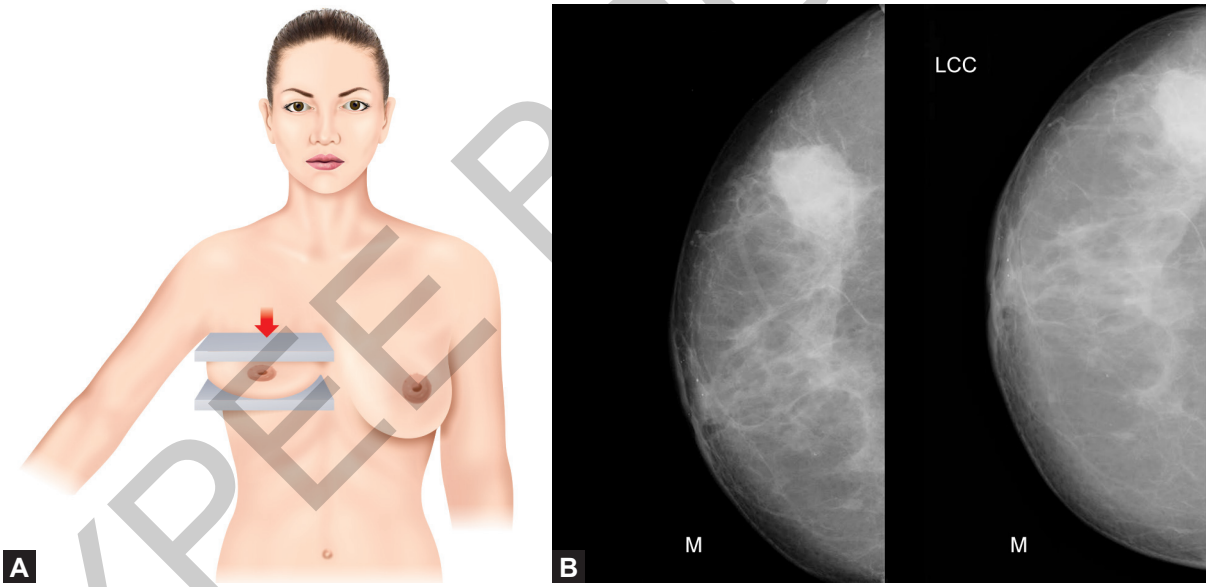

Figs. 5A and B: (A) Positioning for extended CC view; (B) Mammogram showing inadequate coverage of laterally placed mass in routine CC view that would be covered properly in the extended CC view. (CC: craniocaudal).

Axillary Tail View (Cleopatra View)

This view is done to look for abnormalities in axillary tail region and most lateral portion of breast.

The C arm should be raised at 25–30° and breast should be comfortably positioned on bucky.

The axillary aspect of the breast should be gently pulled out away from the chest wall and placed on the image receptor while applying compression (Figs. 6A and B) mass.

Cleavage View or Valley View

This view is taken for demonstration of mass at medial aspect of breast (Figs. 7A and B) which is not adequately covered in CC view.

Technique

The radiographer should stand behind the patient and wrap her arm around the patient to reach her breast at the

JAYPEE BROTHERS

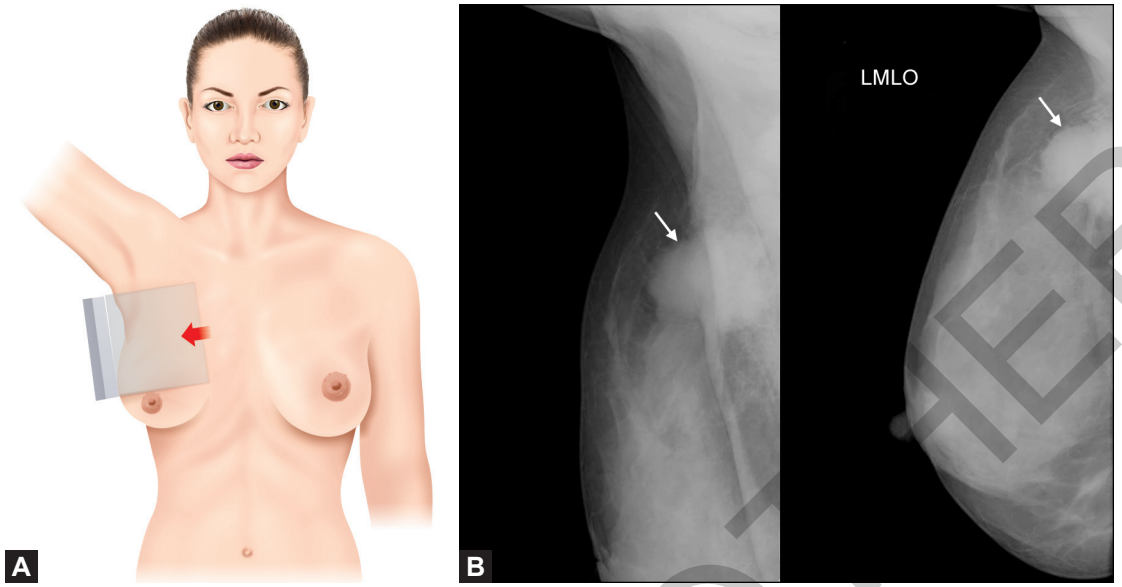

Figs. 6A and B: (A) Positioning for axillary tail (Cleopatra view); (B) Mammogram MLO view shows an inadequately covered mass in axillary tail region that was seen better on the axillary tail view. (MLO: mediolateral oblique).

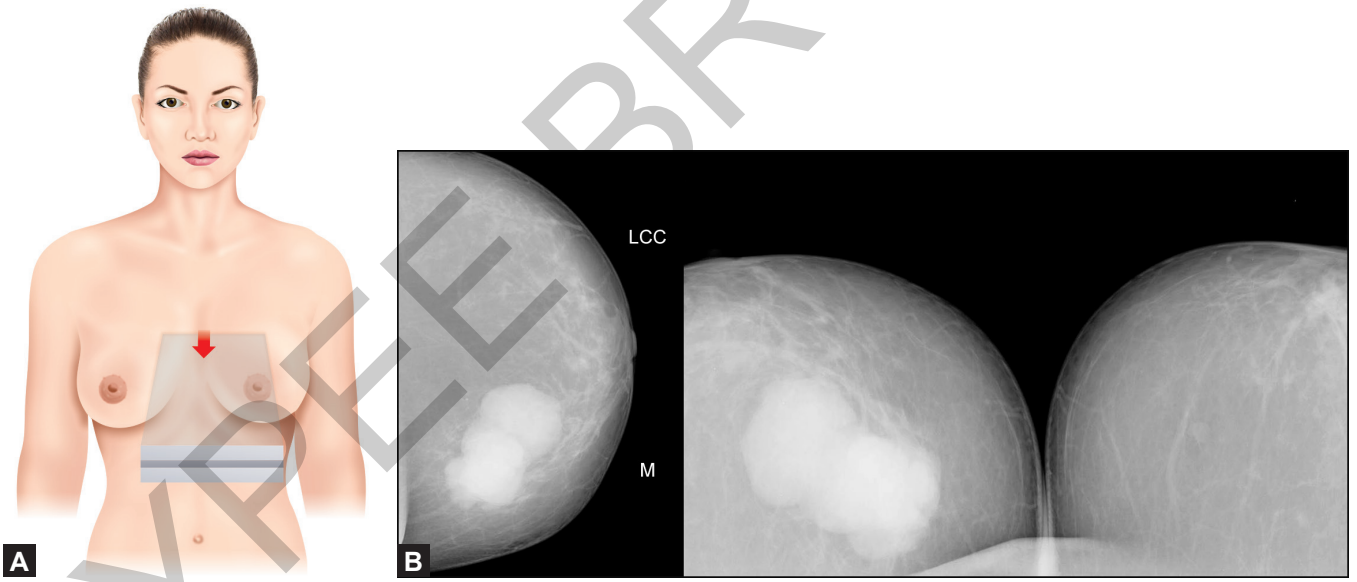

Figs. 7A and B: (A) Positioning for cleavage view also called as valley view; (B) CC view shows a mass in the medial quadrant that is seen well on cleavage view. (CC: craniocaudal.)

same time pulling the medial aspect of both the breasts anteriorly and position them on the image receptor. This way the cleavage area will be positioned adequately.

Spot Compression View

Spot compression is also known as compression mammogram, spot view, cone view or focal compression view.

Spot compression is used to evaluate focal asymmetries and any obscured areas or equivocal findings in dense breast. The basis of this technique is to spread out the breast tissue to decrease overlap so that underlying abnormality is seen well. This is done with the help of a small paddle or cone that provides localized and intense focal compression (Figs. 8A and B).

JAYPEE BROTHERS

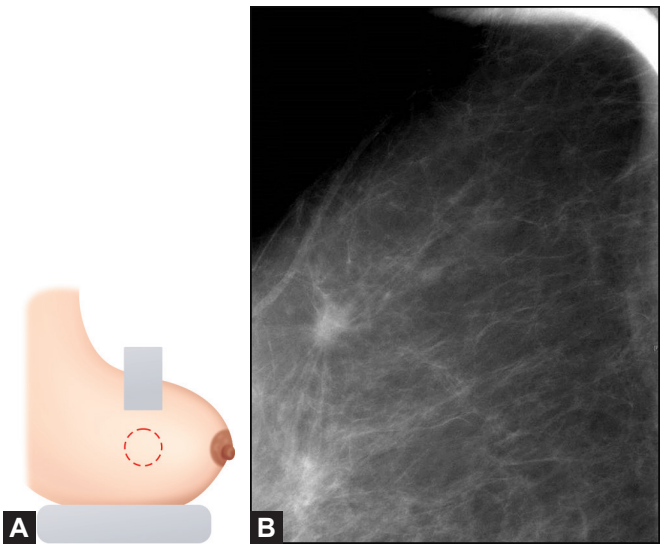

Figs. 8A and B: (A) Spot compression view showing a small paddle compressing the mass in question; (B) Mammogram with spot compression view shows a well-defined spiculated mass with morphological features appreciated well.

How to Determine the Location of the Lesion for Spot Compression?

Technique

To determine the location of lesion to take a spot compression view, it is important to decide in which standardized view (CC or MLO) has to be done. For example, if it is CC view then, on the film first draw a line posteriorly from the nipple and measure the distance of the lesion from this line. In addition, draw a line from the skin surface to the lesion that gives the depth of lesion. The patient is then repositioned and compression given with hand and the same measurements are transferred to breast and a marker put on the breast to identify the lesion location. A spot compression device is then applied over the lesion and the requisite view is taken

Magnification View

This view can be done with or without compression.

It is often used to evaluate microcalcifications to assess their number, location and morphology (Figs. 9A and B) or to delineate the margins of an irregular mass or suspicious mass/area.

Technique

To do this view, an X-ray tube with a microfocal spot to offset geometric sharpness is required along with a magnification platform. This separates the compressed breast from the image receptor for 1.5–2 times magnification.

During the exposure, the patient has to hold still for a longer time than normal mammogram.

The air gap resulting from separation of breast from image receptor reduces scattered radiation.

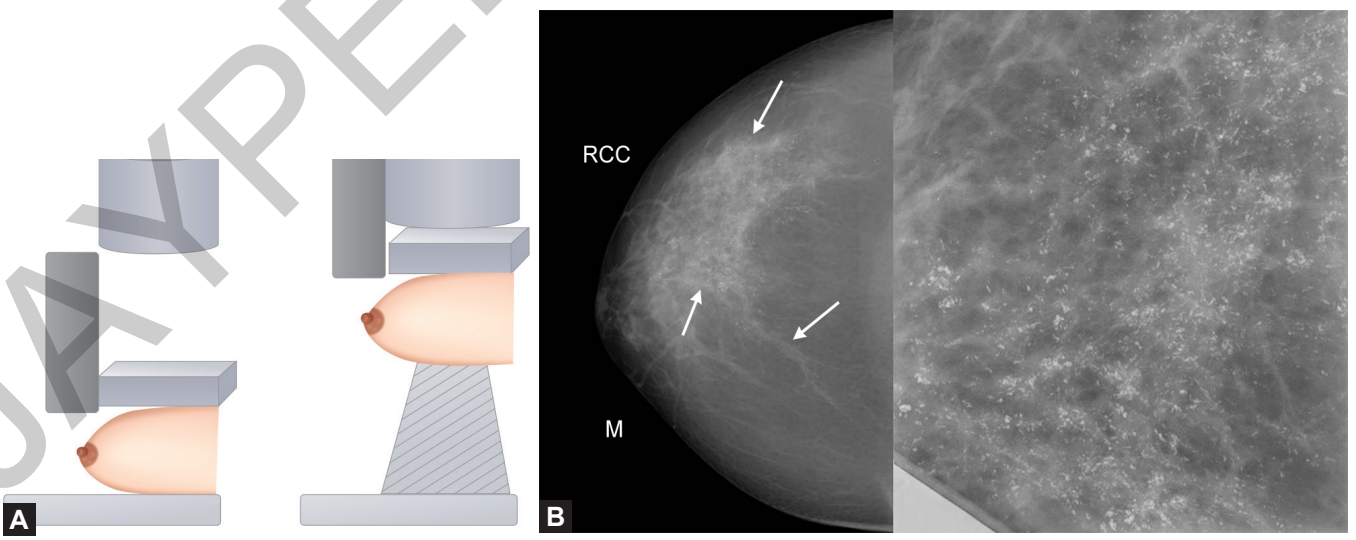

Figs. 9A and B: (A) Magnification view where the breast is positioned on top of the magnification stand, decreasing the focal spot and allowing for magnification; (B) Mammogram—magnification view showing location, morphology and the number of microcalcifications.

JAYPEE BROTHERS

Rolled View

This view is done to separate superimposed structures, to confirm the presence of an abnormality, to determine the location of a finding seen on only one standard view (Fig.10).

Uses: To confirm the presence of an abnormality.

To determine the location of a finding seen on only one standard view.

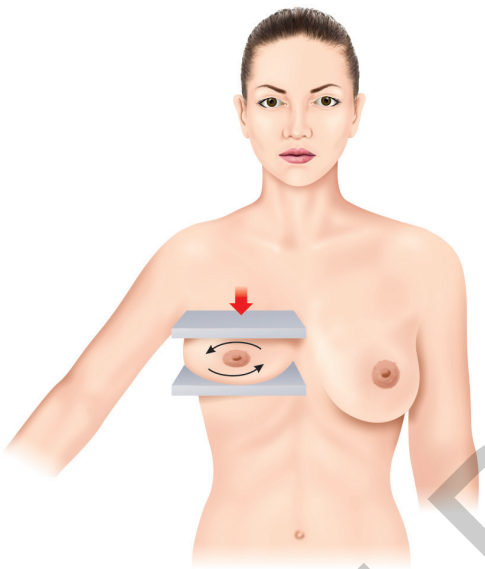

Fig. 10: Positioning for rolled view.

Technique

The patient should be repositioned in the same view in which abnormality was seen. The radiographer should put hands on either side of breast and roll the breast tissue in opposite direction applying compression at the same time. A marker should be positioned on the image receptor indicating the direction of roll.

Tangential View

This view is done mainly for lesion or calcifications which are in the skin or in superficial plane.

Technique

A lead marker is placed over the lump and X-ray beam is directed tangential to the lump so that it is seen properly (Figs. 11 and 12).

Caudocranial or from Below View

This view is performed in patients having kyphosis, patients with small breasts or male patients.

Since the compression comes from below, it does not exclude the posterior fixed tissue.

Eklund View for Implants

Imaging of breast with implants is challenging as the degree of compression is dependent upon the compressibility of

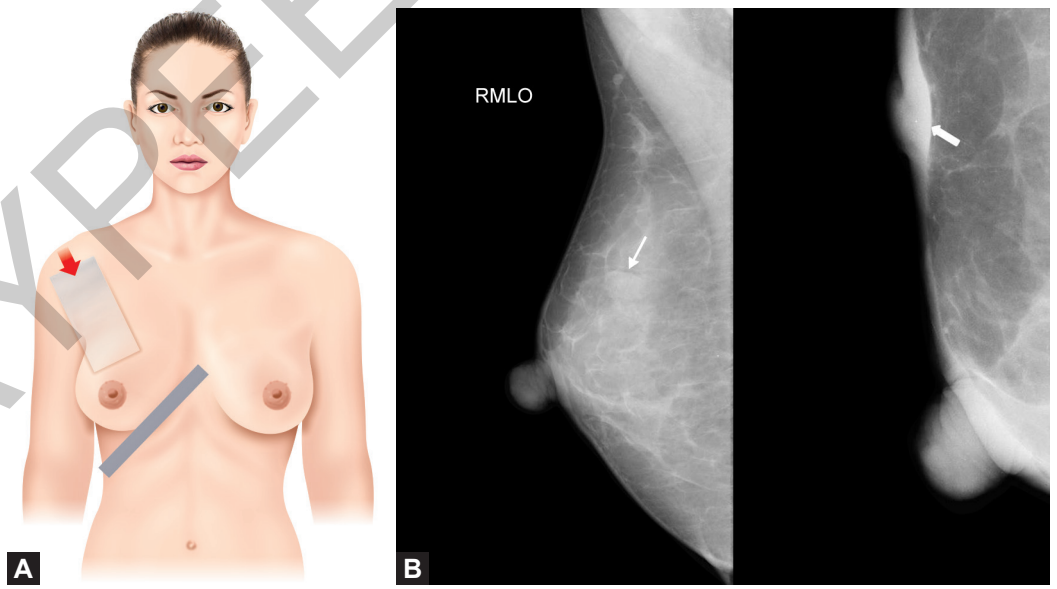

Figs. 11A and B: (A) Positioning for tangential view; (B) Mammogram MLO view showing an obscured density with a lucent halo superiorly which on tangential view was seen as arising from the skin. The patient had a skin nodule in that location. (MLO: mediolateral oblique).

JAYPEE BROTHERS

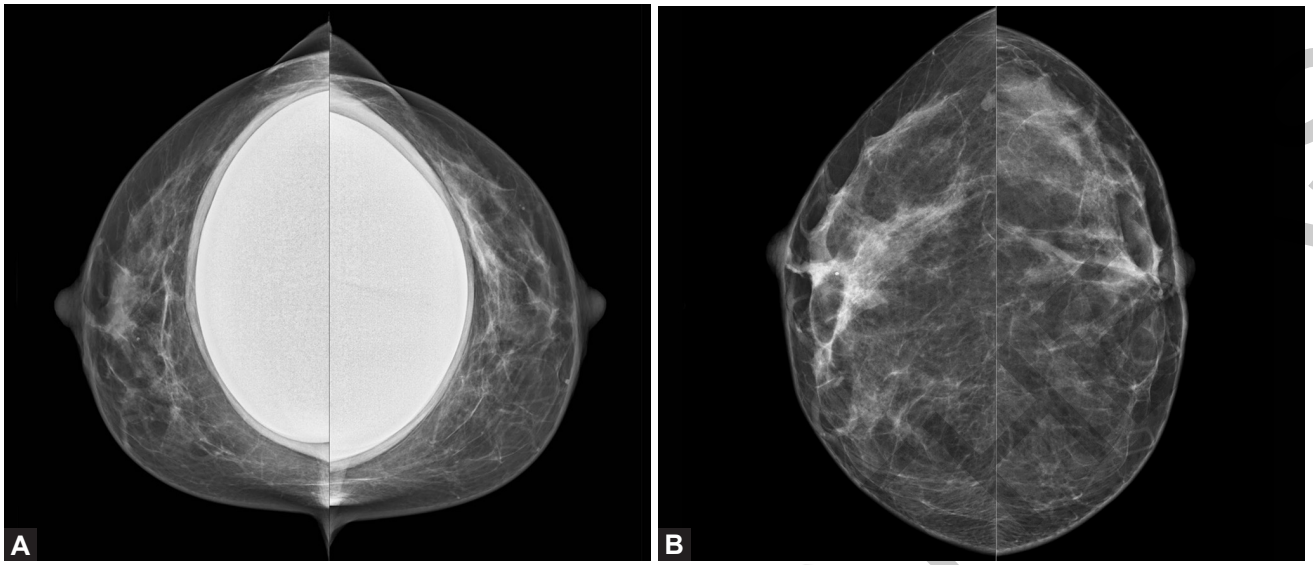

Figs. 12A and B: (A) Mammogram image showing submuscular breast implants on CC view; (B) Breast implants with Eklund view in which the breast tissue is pulled anteriorly and implant is pushed posterosuperiorly so that more of breast tissue is imaged. (CC: craniocaudal).

implants and exposure factors for CC and MLO view have to be set manually.

In this view, the implant is pushed posteriorly and superiorly against the chest wall while gently pulling the breast anterior to the prosthesis onto the image receptor and holding it in place with the compression device (Figs. 12A and B).

For a CC view with implant, the breast tissue superior and inferior to implant is pulled anteriorly.

For an MLO view with implant, the breast tissue that is superomedial and inferolateral will be pulled forward with the anterior tissue.

ARTIFACTS

Artifacts in mammography can create pseudolesions, mask abnormalities and degrade image quality leading to misinterpretation. A high-quality mammogram enhances the radiologist's skill to interpret mammograms. Familiarity with the numerous artifacts encountered while doing mammograms will enable radiologists to provide accurate diagnosis. Technologists should be able to recognize the artifacts and their causes to make corrections immediately and improve mammographic quality.

Artifacts in mammogram can be

- Patient related
- Technologist- and technique-related, including incorrect positioning
- Equipment related.

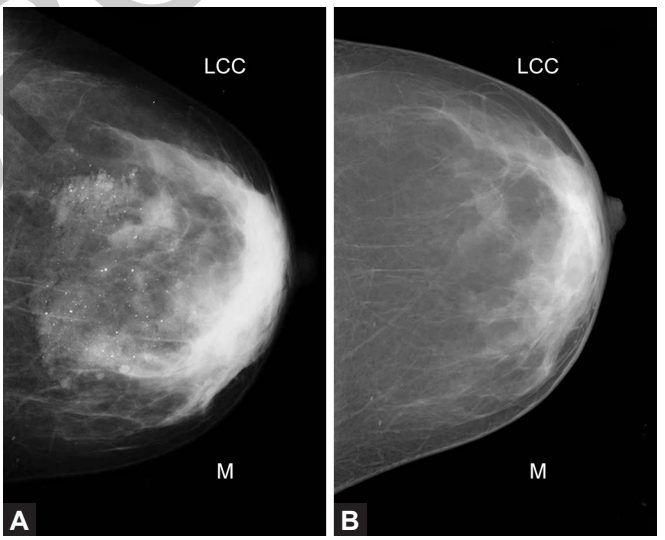

Figs. 13A and B: (A) Mammogram CC view with talcum powder which resembles microcalcifications; (B) Repeat view after cleaning the area appeared normal. (CC: craniocaudal).

Patient Related

The radiographer performing mammography should switch on the light beam during the time of positioning of patient so that overlapping shadows can be avoided.

The patient should be instructed not to apply deodorant or talcum powder before undergoing mammograms as these cause high-density foci resembling calcifications (Figs. 13A and B) because of presence of zinc or magnesium.

JAYPEE BROTHERS

Medical devices, scars and nevus on the skin may create pseudomasses; hence, the patient's skin should be examined properly by the technologist. In the elderly patients, skin-fold artifact may be produced because of trapping of loose skin (Fig. 14) in compression paddle. Blurring is produced if the patient moves during compression (Fig. 15). Sometimes, artifacts are noted when the patient comes for a mammogram after an excision biopsy and has bits of adhesive plaster remaining on skin or the technologist does a mammogram without removing dressing from the skin surface (Figs. 16 and 17). The patient's hair should be properly tied as they can also produce artifacts (Figs. 18A and B).

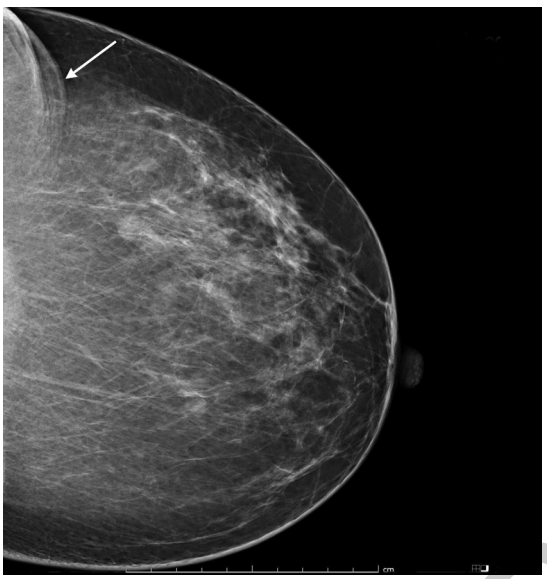

Fig. 14: Mammogram CC view of left breast showing skin fold (arrow). (CC: craniocaudal).

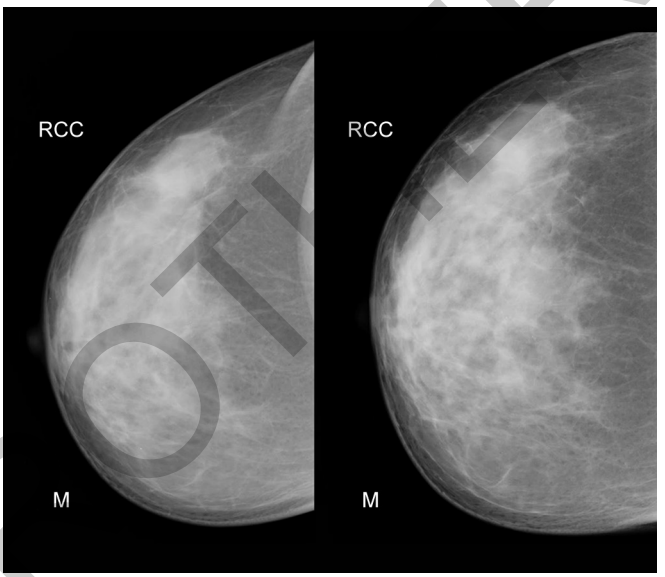

Fig. 15: Mammogram of right breast CC view—image with less compression causing unsharpness that was rectified on repeat view where the image appears sharp. (CC: craniocaudal).

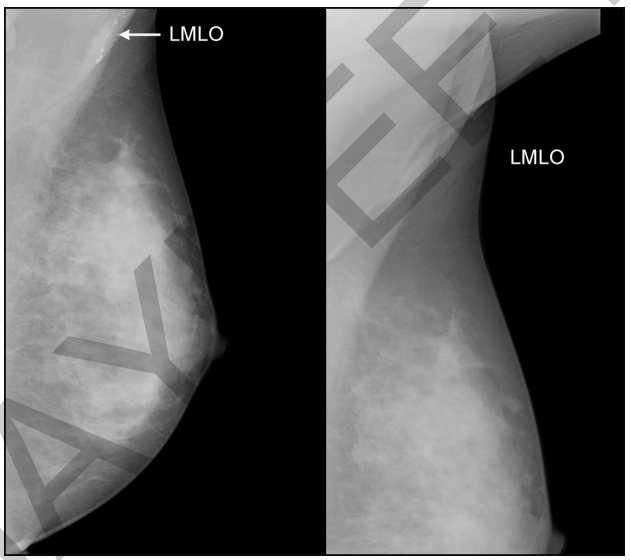

Fig. 16: Mammogram MLO view in a patient who had a lumpectomy for an axillary mass. Mammogram shows a few high-density foci arranged in a linear fashion. On examining the patient clinically, it was found that there were remnants of adhesive plaster. The view was repeated after thorough cleaning of the area. Repeat mammogram was normal. (MLO: mediolateral oblique).

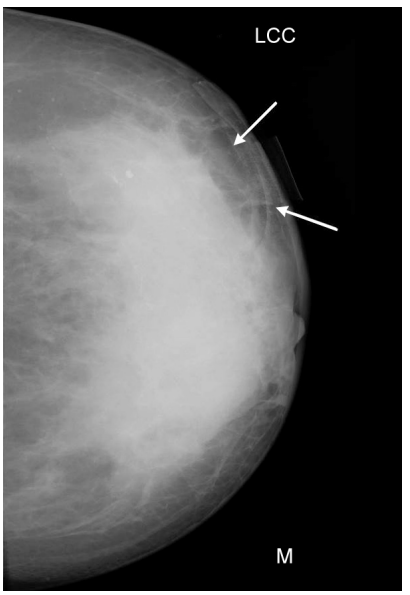

Fig. 17: Mammogram CC view shows a well-defined density (arrows) that was due to a dressing. Please note that the technologist had done the mammogram without removing the dressing. (CC: craniocaudal).

JAYPEE BROTHERS

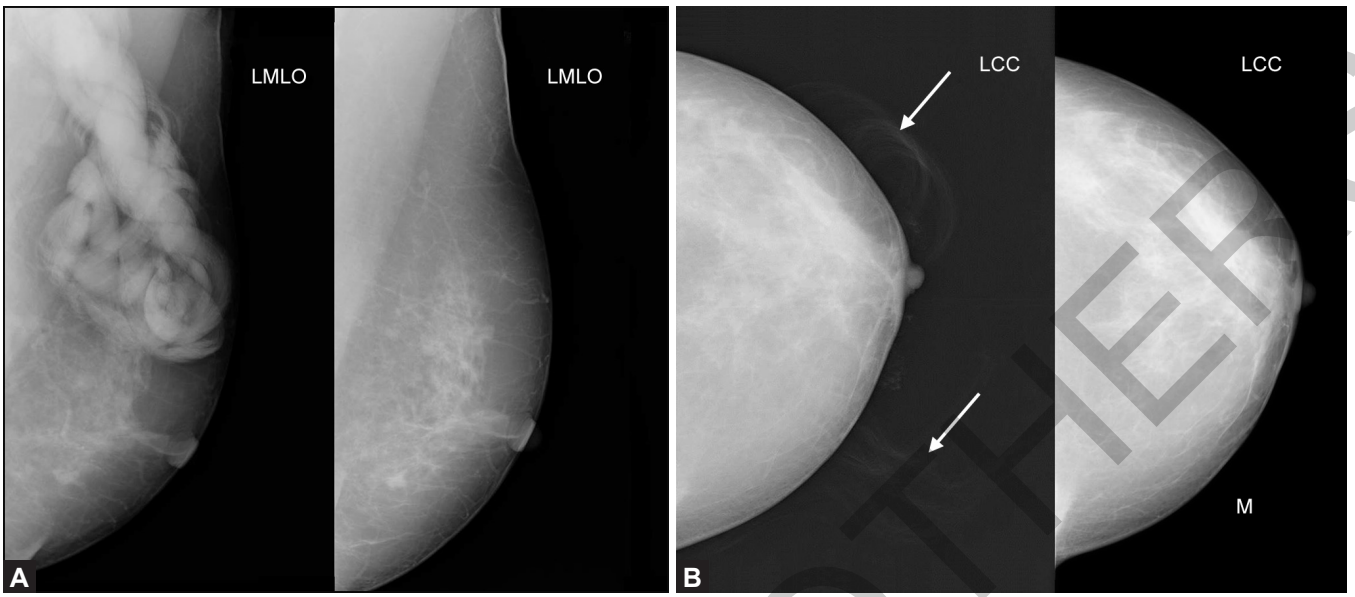

Figs. 18A and B: (A) Mammogram of left breast MLO view shows artifact due to hair (long braided plait) that was rectified on repeat view; (B) Similar artifact due to hair is seen in the CC view faint shadow (arrows). (CC: craniocaudal; MLO: mediolateral oblique).

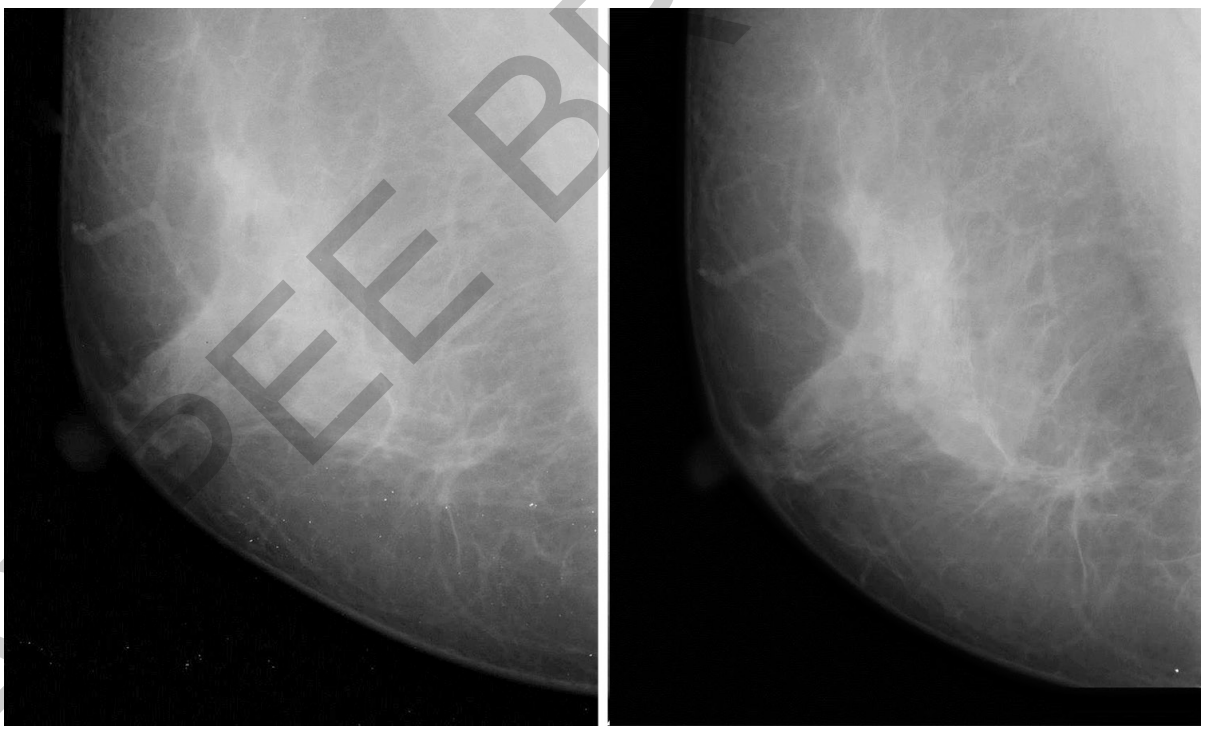

Figs. 19A and B: (A) Artifact due to dust particles on intensifying screen that disappeared on repeat view done after (B) cleaning the screen.

Technologist- and Technique-related

Proper care of the intensifying screens and cassettes should be taken and they must be cleaned at least weekly.

The most common artifacts are dust and dirt on the intensifying screen (Figs. 19A and B) that block the path of light during exposure so that there are white densities seen on the film which resemble calcifications.

JAYPEE BROTHERS

Artifacts are also seen due to improper positioning by the technologist (Figs. 20 to 22) or because of sudden movement by the patient. The common artifacts noted are shoulder and chin artifact (Figs. 23 and 24).

Equipment Related

These artifacts may be due to incorrect collimation, incomplete grid motion, bucky failure, wear and tear and compression system failure (Figs. 25A and B; 26 to 30).



Fig. 20: Mammogram showing abdominal skin fold overlying the breast tissue.



Fig. 21: Mammogram showing nipple en face on MLO. (Please note that nipple should be in profile). (MLO: mediolateral oblique).

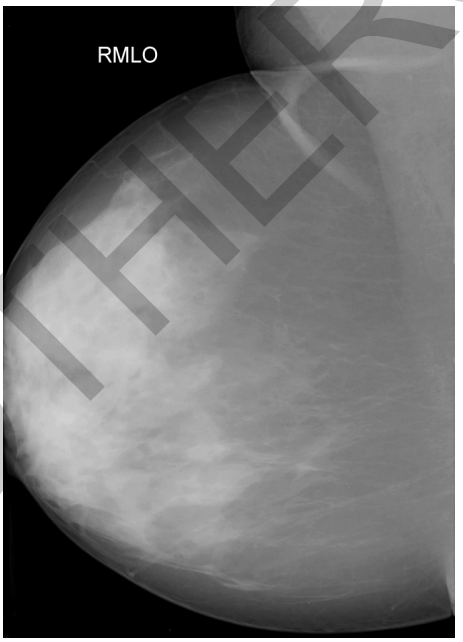

Fig. 22: The anterior portion of the breast is not included in MLO view. (MLO: mediolateral oblique).



Fig. 23: Artifact due to shoulder on the MLO view due to improper positioning. (MLO: mediolateral oblique).

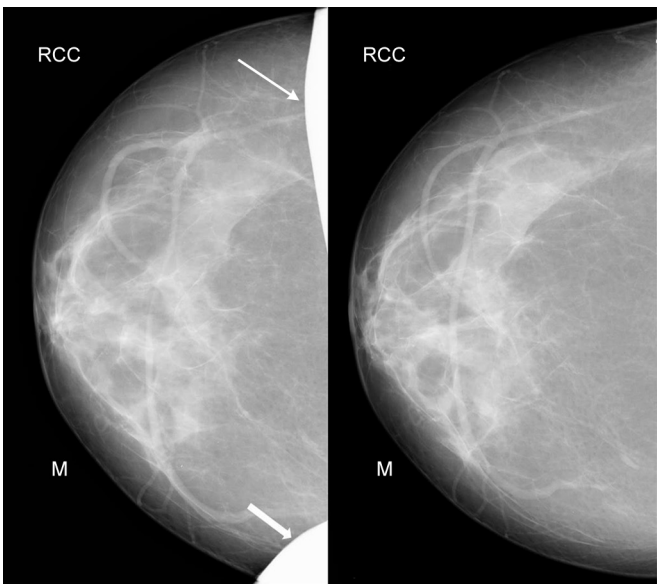

Fig. 24: Mammogram CC view showing chin (thick arrow) and shoulder (thin arrow) artifact due to improper positioning. Repeat view appears normal. (CC: craniocaudal).

JAYPEE BROTHERS

detailed information on radiology books, visit our website www.jaypeebrothers.com, for detailed information on radiology books, visit our website www.jaype

Essentials of Breast Imaging

Salient Features

- Comprehensive discussion of basic and key concepts of breast imaging
- Simplicity and clarity without compromising relevant details and essentials
- Profusely illustrated with nearly 212 line diagrams and illustrations, 684 high quality images from mammography, ultrasound and MRI, and 230 references
- Chapter on positioning addresses problems faced by radiographers and radiologists
- Exclusive chapters on postoperative mammography, breast implants, and male breast pathologies
- Chapter discussing relevance of Breast Cancer Screening in Indian scenario
- Section on Cases for Self-Evaluation discusses 56 cases in order of complexity.

Smiti Sripathi completed her MBBS (1994) from MGM Medical College, Indore and postgraduation DNB in Radiodiagnosis (2000) from JLN Hospital and Research Center, Bhilai. She joined as Radiology faculty at Manipal College of Medical Sciences, Pokhara, Nepal in 2000 and later moved to Sikkim Manipal Institute of Medical Sciences, Gangtok. She joined Kasturba Medical College, Manipal as Assistant Professor in October 2005, and rose through the ranks of Associate Professor (July 2010) and Professor (April 2014) to become the Head of Department of Radiology, KMC Manipal in April 2018. She continued at the same post till her demise in December 2018. In Radiology, her area of interest was Breast Imaging. She was awarded a travel fellowship grant for the project titled "Breast Cancer Screening Program in High Risk Females with Positive Family History" to attend the 7th European Breast Cancer Conference at Barcelona, Spain in March 2010. Later on, she won the Commonwealth Academic Fellowship in Breast Imaging at Southend University Hospital, Essex, UK in 2014. It was here that she got acquainted with Dr Aron Sraj, and with his support, her desire to write a book on Breast Imaging finally started to take shape.

Academics apart, she also worked passionately for creating breast cancer awareness among South Kannada's local population through newspaper articles, conducting interactive sessions on breast cancer and promoting breast self-examinations. A very kind hearted person, she was also a voracious reader, a great cook, and she loved to travel the world, always happy to explore mother nature. Her untimely demise has left lacunae in the field of breast imaging in India, which will be difficult to fill.

Aron Sraj obtained his medical diploma in 1990 and CCST in radiology in 1995. The same year he joined Borsod County Teaching Hospital in Miskolc, Hungary as a specialist registrar (radiology) and became a consultant radiologist at Semmelweis Teaching Hospital in Miskolc in 2001. He shifted to the UK in 2007, joining Altnagelvin Area Hospital (WHSCT) in Northern Ireland as a consultant radiologist and then continued on to Southend University Hospital, Essex from 2010 until 2015. From 2016 to present, he is the clinical lead radiologist with Specialized Medical Solutions WLL/PHCC in Doha, Qatar.

In 1995, he was one of the first radiologists to have established the US-guided breast biopsies and his breast unit pioneered starting a nationwide breast cancer screening program in Hungary. It followed the European guidelines and directive based on the Swedish Breast Imaging School. In 2007, he worked in the NHS Breast Screening Program, conducting various clinics in both screening and diagnostic breast imaging. He joined SMS WLL in Doha in 2016, from where the Qatari government initiated the Screen for Life program under the umbrella of Primary Healthcare Corporation (PHCC), which encompasses nationwide breast and bowel screening.

He has extensive experience both in general and breast radiology, a special interest in breast interventions and is a life member of European Society of Breast Imaging. He has several national and international publications and attends conferences and CMEs all over the world to keep himself updated with the recent trends and advances in breast radiology.

Available at all medical bookstores
or buy online at www.jaypeebrothers.com

JAYPEE BROTHERS
Medical Publishers (P) Ltd.
www.jaypeebrothers.com

Join us on facebook.com/JaypeeMedicalPublishers

Shelving Recommendation
RADIOLOGY

ISBN 978-93-89587-48-7