ed information on orthopedics books, visit our website www.jaypeebrothers.com, for detailed information on orthopedics books, visit our website www.jaypeebrothers.com

Celebrating 50 Passion, Quality and Innovation in Healthcare Publishing

Clinical Methods in ORTHOPEDICS

A Concise Guide





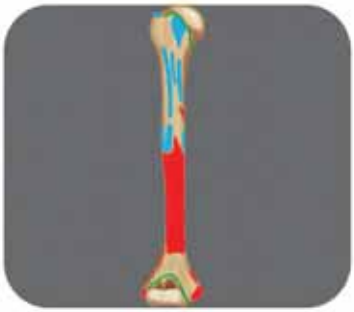





Upendra Kumar

Forewords
DK Taneja
NK Magu
VK Sinha

JAYPEE

Contents

SECTION 1: Orthopedic Cases and Viva Voce

1. Chronic Osteomyelitis 3
   Case presentation 3 • Viva voce from case 3 • Pyogenic osteomyelitis versus septic arthritis 7
2. Bony Swelling (Exostosis) 9
   Case presentation 9 • Viva voce from case 9 • Benign versus malignant bony mass 11
3. Nonunion Fracture Long Bone 12
   Case presentation 12 • Viva voce from case 12 • Fracture complications 16
4. Wrist Drop (Radial Palsy) 18
   Case presentation 18 • Viva voce from case 18 • Nerve injury pattern (Seddon classification) 23
5. Frozen Shoulder 25
   Case presentation 25 • Viva voce from case 25 • Two differentials for frozen shoulder 27
6. Cubitus Varus Deformity at Elbow (Malunited Supracondylar Fracture Humerus) 29
   Case presentation 29 • Viva voce from case 29 • Extension and flexion type of supracondylar fracture humerus 33
7. Cubitus Valgus Deformity at Elbow (Nonunion Fracture Lateral Condyle Humerus) 34
   Case presentation 34 • Viva voce from case 34 • Comparative study of lateral and medial condyle of fracture humerus 37
8. Malunited Colles' Fracture 38
   Case presentation 38 • Viva voce from case 38 • Overview of fracture around distal radius 41
9. Congenital Clubfoot 43
   Case presentation 43 • Viva voce from case 43 • Idiopathic clubfoot at a glance 47
10. Genu Varus Deformity at Knee (Osteoarthritis Knee) 49
    Case presentation 49 • Viva voce from case 49 • Comparison of tuberculous, rheumatoid, and gouty arthritis 52
11. Genu Valgus Deformity at Knee (Rickets) 55
    Case presentation 55 • Viva voce from case 55 • Different types of rickets 59
12. Nonunion Fracture Neck of Femur 61
    Case presentation 61 • Viva voce from case 61 • Fracture neck of femur vs fracture trochanter 68

SECTION 2: Some Orthopedic Appliances

13. Plaster of Paris and Different Types of Casts 73
    Plaster of Paris bandage 73 • Principle of reduction and casting 74 • **Some common plaster splintage and cast 75** • Casting in Jame's position: Radial gutter, ulnar gutter, and volar splintage with POP 75 • Scaphoid cast 75 • Thumb spica 76 • Colles' cast 76 • U-slab/cast 76 • Above elbow POP cast 76 • Shoulder spica 77 • Below knee cast and boot cast 77 • Clyindrical cast 78 • Above knee cast 78 • Patellar tendon bearing (PTB) cast 78 • Hip spica 79
14. Review of Orthopedic Tractions 80
    Bohler Braun splint (Bohler: An Austrian surgeon) 80 • Thomas splint (Robert Jones) 80 • Bohler's stirrup 81 • Steinmann pin and Denham pin 81 • Buck's pulley 82 • Traction 82 • **Some common orthopedic tractions** 85 • Bryant's/Gallow's traction 85 • Upper tibial traction 85 • Distal tibial traction 85 • Calcaneal traction 85 • Head Halter traction 86 • Pelvic traction 86 • Cervical traction by Crutchfield tong 86 • Boot and bar/derotation bar/flapper 86

JAYPEE BROTHERS

15. Some Orthosis and Prosthesis 88
Basics of orthosis 88 • Some common orthosis 89 • **Basics of prosthesis 92** • Some common prosthesis 93

SECTION 3: Some Orthopedic Instruments and Implants

16. Some Common Orthopedic Instruments 97
Periosteal elevator 97 • Bone lever 97 • Osteotome, chisel, and gouge (Stille type) 98 • Bone nibbler (Rongeur) 99 • Scoop or curette (Volksmann's type) 99 • Bone holders 99 • Orthopedic pliers 101 • Mallet 102

17. Some Common Orthopedic Implants 103
Kirschner's wire 103 • Stainless steel wire 103 • Orthopedic screw 104 • Bone plates 105 • Intramedullary nails 106 • Cannulated cancellous hip screw 108 • Dynamic hip screw (DHS) plate 109 • Unipolar hip prosthesis: Austin-Moore and Thompson prosthesis 109 • Talwalkar's bipolar prosthesis 110

SECTION 4: Some Common Orthopedic Radiographs

18. Radiographs from Trauma 113
• X-ray: Fracture patterns and mechanism of injury 113 • X-ray: Stress fracture 114 • X-ray: Pathological fractures 115 • X-ray: Pediatric fracture 115 • **Review of common fractures and dislocations 116** • X-ray: Fracture clavicle 116 • X-ray: Anterior shoulder dislocation 117 • X-ray: Fracture proximal humerus 118 • X-ray: Fracture shaft humerus 118 • X-ray: Fracture supracondylar and intercondylar humerus 119 • X-ray: Posterior dislocation of elbow 119 • X-ray: Fracture radial head 120 • X-ray: Fracture olecranon process 121 • X-ray: Fracture radius and ulna 121 • X-ray: Fracture distal radius (Colles fracture) 122 • X-ray: Fracture scaphoid 123 • X-ray: Fracture base of 1st metacarpal 124 • X-ray: Dislocation of hip 124 • X-ray: Fracture neck femur 125 • X-ray: Fracture trochanter femur 126 • X-ray: Fracture shaft femur 126 • X-ray: Fracture supracondylar and intercondylar femur 127 • X-ray: Fracture patella 127 • X-ray: Fracture proximal tibia 128 • X-ray: Fracture shaft tibia and fibula 129 • X-ray: Fracture malleoli 129 • X-ray: Fracture calcaneus (Lover's fracture) 130 • X-ray: Fracture base of 5th metatarsal (Jones fracture) 130

19. Radiographs of Common Bone Tumors 132
• Description of a tumor radiograph 132 • X-ray: Osteochondroma/exostosis 134 • X-ray: Simple bone cyst and aneurysmal bone cyst 134 • X-ray: Fibrous dysplasia 135 • X-ray: Giant cell tumor 136 • X-ray: Osteosarcoma 136 • X-ray: Ewing sarcoma 137

20. Radiographs of Common Infective, Rheumatic and Metabolic Disorders 138
X-ray: Chronic osteomyelitis 138 • X-ray: Osteoarticular tuberculosis 139 • X-ray: Degenerative arthritis 139 • X-ray: Rheumatoid arthritis 140 • X-ray: Ankylosing spondylitis 141 • X-ray: Nutritional rickets 142 • X-ray: Osteomalacia 142 • X-ray: Osteoporosis 143 • X-ray: Scurvy 143 • X-ray: Loose bodies of knee 144

SECTION 5: Bones Catalogue

Bones Catalogue 147
• 1. Clavicle 147 • 2. Scapula 148 • 3. Humerus 150 • 4. Radius and ulna 152 • 5. Pelvic bone 154 • 6. Femur 157 • 7. Patella 159 • 8. Tibia and fibula 160 • 9. Typical spine 163

Bibliography 165

Index 167

JAYPEE BROTHERS

Chapter

8

Malunited Colles' Fracture

JAYPEE BROTHERS

CASE PRESENTATION

- **History**: My patient, a 55-year-old lady presented with complaint of deformity at her right wrist for last 5 months. She fell down on a slippery surface with her outstretched hand. She sustained an injury in her left wrist that produces a peculiar attitude of her hand. She was carried to a local bonesetter who applied some bandaging for 4 weeks. After removal of bandaging patient noticed a deformity in her left hand which was associated with pain and stiffness. For this she took some physiotherapy and her stiffness was resolved partially but deformity and pain persisted. There is no history of any fever, weight loss, or multiple joint pain.
- **Examination**: Patient is of average built and of average nutrition. Her general physical and systemic examination is within normal limit. Local examination showed an outward deviation of hand (manus valgus) with prominent ulnar styloid process. There is irregularity at lower end of radius and mild tenderness at distal radioulnar joint. The tip of radial styloid process is at same level of the tip of ulnar styloid process. All movement, such as palmar flexion, dorsiflexion, supination, and pronation are restricted. There is no limb length discrepancy. Distal neurovascular examination is also normal.

VIVA VOCE FROM CASE

Q. What is your case?

Ans. This is a case of right-sided malunited Colles' fracture (Fig. 8.1).

Q. What deformity you are getting at wrist?

Ans. Manus valgus deformity.

Two deformity at wrist of attention.

- Madelung deformity
- Malunited Colles' fracture.

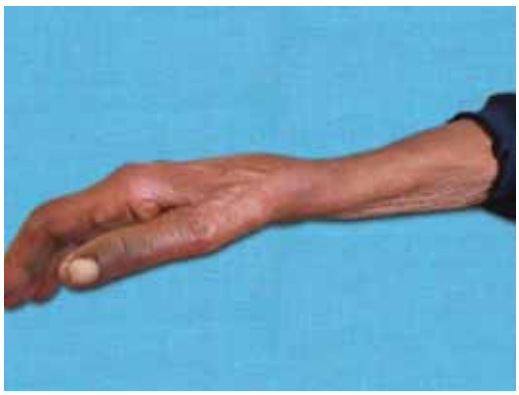

Fig. 8.1: A case of malunited Colles' fracture.

Q. Why you say that this deformity is due to malunited Colles' fracture?

Ans. The points favoring this statement are as follows:

- History of trauma in past.
- Treatment history by a bone setter in form of bandaging.
- Peculiar deformity at wrist (manus valgus).
- Irregularity at lower end of radius.
- Tenderness at distal radioulnar joint.
- Tip of radial styloid process is at same level of the tip of ulnar styloid process (Fig. 8.2).
- Range of motion at wrist is restricted.

Correlation between tip of radial styloid process and tip of ulnar styloid process.

- Normally the tip of radial styloid process lies approximately 1 cm (11–12 mm) distal to the tip of ulnar styloid process.
- This difference is also known as radial height.
- After Colles' fracture, both styloid processes come at same level or tip of radial styloid process goes higher due to proximal impaction of fracture fragment.

Q. Any other clinical finding you like to search in this case?

Ans. I will try to search any involvement of **distal radioulnar joint**. It could be identified by two ways:

1. Restricted and painful pronation and supination.
2. Instability at distal radioulnar joint (ballottment of ulnar head antero-posteriorly—piano-key sign).

Q. What investigation you like to get in this case?

Ans. X-ray of the wrist, AP and lateral view (Fig. 8.3).

- Manus valgus deformity
- Healed fracture (in healing fracture there is presence of varying amount of callus)
- Both radial and ulnar styloid processes tips are at same level.

Q. What is your treatment plan?

Ans. Here the main problem is pain and stiffness and there is no functional loss in wrist and hand, hence I will go for conservative treatment in form of:

- Analgesics
- Activity restriction like lifting heavy weight, etc.
- Physiotherapy and electrotherapy (ultrasound) for improvement of wrist movement and hand function.

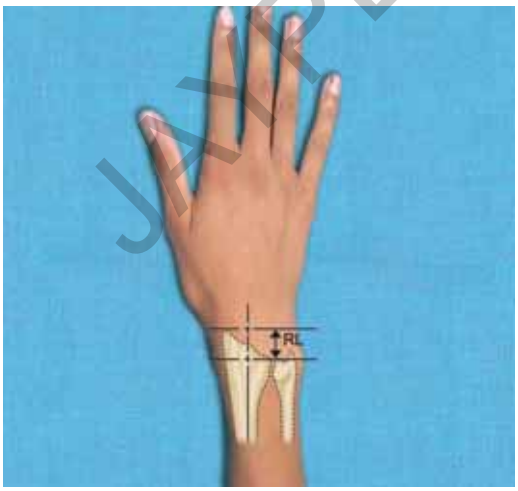

Fig. 8.2: Relationship between radial and ulnar styloid process.

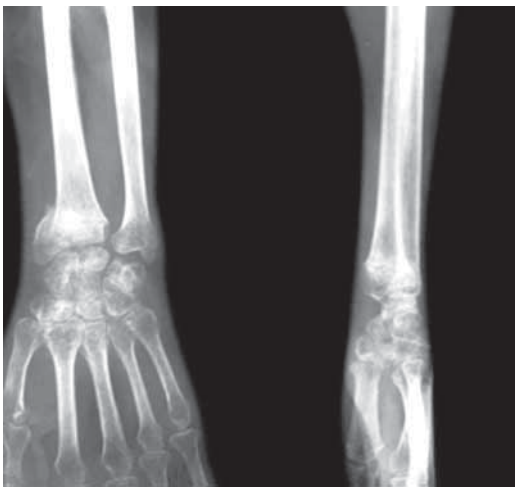

Fig. 8.3: X-ray of malunited Colles' fracture.

JAYPEE BROTHERS

Q. About which function of hand you are talking about?

Ans. I am quoting about basic functions of hands; these are (Fig. 8.4):

- Grip
- Hook
- Pinch.

Q. What is Colles' fracture?

Ans. It is a fracture at distal end of radius within 2 cm of wrist joint. It is named in respect of sir Abraham Colles from Ireland.

Q. What is mechanism for Colles' fracture?

Ans. A fall in outstretched hand with wrist in slight dorsiflexion mode. Here a bending force acts at corticocancellous junction and fracture happen.

Q. Is there any relation between age and sex with this fracture?

Ans. Yes, it is common in elderly female with osteoporotic bone mainly after menopause.

Q. What special deformity you get at wrist after Colles' fracture?

Ans. It is known as dinner fork deformity (Fig. 8.5).

Q. What are different injuries associated with fracture distal radius?



Fig. 8.4: Grip, hook, and pinch.



Fig. 8.5: Dinner fork deformity.

Ans. These are as:

- Fracture distal ulna
- Fracture ulnar styloid process
- Distal radioulnar joint injury.

Q. What are the classical displacements you get in radiographs of Colles' fracture?

Ans. These are as (Fig. 8.6):

- Lateral tilt
- Lateral shift
- Dorsal tilt
- Dorsal shift
- Proximal impaction
- Supination.

Q. How will you treat this fracture?

Ans. I will go for close reduction and Colles' cast application.

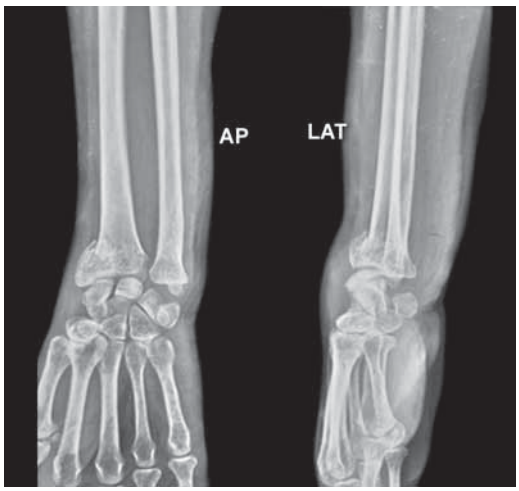

Fig. 8.6: Colles' fracture showing displacements in AP and lateral view.

JAYPEE BROTHERS

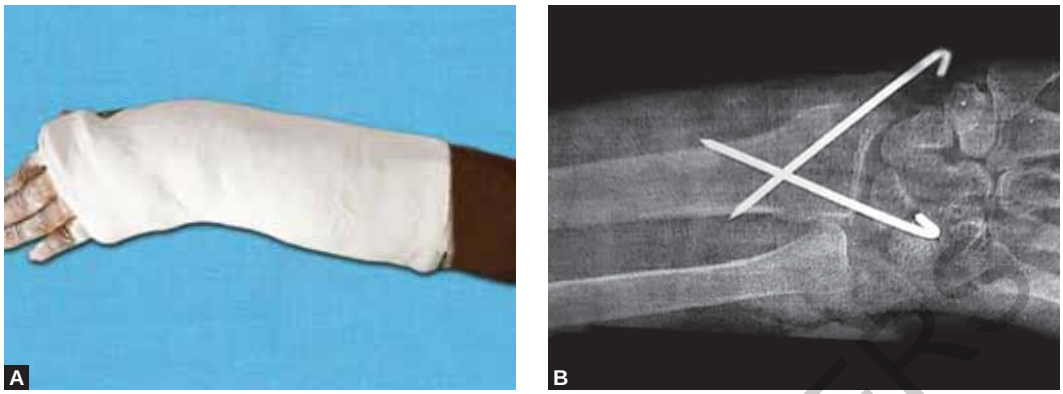

Figs. 8.7A and B: A. Colles' cast and; B. Colles' fracture fixed with K-wire.

Q. What is Colles' cast?

Ans. Colles' cast is a below elbow cast with a special position to counteract the displacements of Colles' fractures.

- Forearm position: Pronated
- Palmar flexion
- Ulnar deviation.

Note: Traction forces reduce the proximal impaction and maintain radial height.

Q. Is there any indication of surgical fixation in Colles' fracture?

Ans. Yes. If there is unacceptable or unstable reduction, fracture should be fixed with K-wire or distal radius plate (Figs. 8.7A and B).

Q. What are the complications of Colles' fracture?

Ans. These are as:

- Stiffness of wrist and hand
- Malunion (manus valgus)
- Carpal tunnel syndrome
- Reflex sympathetic dystrophy
- Distal radioulnar joint instability
- Rupture of extensor pollicis longus
- Shoulder hand syndrome (due to cast application).

OVERVIEW OF FRACTURE AROUND DISTAL RADIUS (FIGS. 8.8 TO 8.10)

Smith Fracture (Fig. 8.8)	Barton Fracture (Fig. 8.9)	Chauffeur Fracture (Fig. 8.10)
• Reverse of Colles' fracture is called smith fracture. • Mechanism: Fall on dorsum of wrist in palmar flexion attitude. • Displacement: Volar tilt and volar shift. • Deformity: Garden spade deformity. • Treatment: Close reduction and above elbow cast. In unstable reduction cases surgical fixation is done with K-wires or distal radius plate.	• Intra-articular vertical split fracture of distal radius in coronal plane extending from joint to dorsal cortex (dorsal Barton) or ventral cortex (volar Barton). • Mechanism: Fall on outstretched hand under effect of shearing forces. • Displacement: Displacement of entire carpals bones with dorsal fragment. • Treatment: Close reduction and below elbow cast with wrist palmar flexion and dorsiflexion. Unstable reduction cases are surgically fixed with distal radius plating.	• Intra-articular radial styloid fracture. • It occurs due to backfire of handle during genset starting. • Treated by a below elbow cast in Colles' position.

CBS PUBLISHERS



Fig. 8.8: Smith fracture.



Fig. 8.9: Dorsal and volar Barton fracture.



Fig. 8.10: Chauffeur fracture.

JAYPEE BROTHERS

for detailed information on orthopedics books, visit our website www.jaypeebrothers.com, for detailed information on orthopedics books, visit our website www.jaypeebro

Clinical Methods in ORTHOPEDICS
A Concise Guide

Salient Features

- First book of its kind on practical orthopedic for undergraduate students
- Includes over 200 self-explanatory photographs and line diagrams and many boxes for quick revision of important topics
- Includes orthopedic cases in viva voce manner
- Provides good details of orthopedic instruments, appliances like traction, plasters and common orthosis, and also provides their uses
- Includes comprehensive and reproducible description of orthopedic radiographs and related facts
- Provides brief account of bones
- Is a ready reckoner before entering the undergraduate examination.

Upendra Kumar D Ortho DNB Ortho is working in Government Medical College, Bettiah, Bihar, India, and also serving the humanity as private orthopedic consultant in his Bone and Joint Hospital Orthocare under RJ Memorial Trust, Bettiah, Bihar. He has completed his postgraduate diploma from Patna Medical College, Patna and DNB from Deen Dayal Upadhyay Hospital, Delhi. He has also gained experience in orthopedic rehabilitation from National Institute for the Orthopedically Handicapped, Kolkata, West Bengal, India. He has worked with the most famous orthopedic surgeon of India, Dr John Mukhopadhyay, son of so called Father of Indian Orthopedics, Dr B Mukhopadhyay.

He has presented several papers in various national conferences. His students are getting success in prestigious DNB practical examinations at different centers throughout the country. He is also teaching postgraduate students (DNBs and Masters) in various PG courses. His online group discussion is also helpful for remote students too. He used to visit PG courses led by Dr Deven Kumar Taneja in Indore and run by Dr Alok C Agrawal in Jabalpur, Madhya Pradesh, India.

Available at all medical bookstores
or buy online at www.jaypeebrothers.com



JAYPEE BROTHERS
Medical Publishers (P) Ltd.
www.jaypeebrothers.com

Join us on facebook.com/JaypeeMedicalPublishers

Shelving Recommendation
ORTHOPEDICS

