Contents

Section 1: General

1. **Surgical Anatomy of Anterior Abdominal Wall** 3
   CS Ramesh Babu, Aruna Arya
2. **Overview of Laparoscopic Entry** 12
   Artin Ternamian

Section 2: Established Alternate Entry Point

3. **Palmer's Point** 41
   Parima Jain, Prateek Gupta, Nutan Jain
4. **Lee-Huang Point** 47
   Rhythm Bhalla, Nutan Jain
5. **Hasson Open Entry Technique** 53
   Swati Dubey, Nutan Jain
6. **Nonumbilical Midline Entry: A Modified Hasson Technique** 57
   Rooma Sinha, Rupa B
7. **Establishment of Pneumoperitoneum through the Left Ninth Intercostal Space** 63
   Harry Reich, Jonathan M Reich

Section 3: Challenges in Entry

8. **Hazards of First Blind Port Umbilical Entry** 69
   Anadeep Chandi, Nutan Jain
9. **Limitations and Contraindications of Palmer's Point** 76
   Nutan Jain, Vandana Jain

Section 4: Introduction of Jain Point

10. **What is Jain Point: The Technique** 87
    Nutan Jain, Vandana Jain, Swati Kanawa
11. **Evolution of Jain Point** 102
    Nutan Jain, Shivam Vatsal, Monika Ranwa
12. **Rationale of Jain Point** 107
    Nutan Jain, Aruna Arya, Swati Varshney, Sonam Singh
13. **Ergonomics of Jain Point** 114
    Nutan Jain, Bhumika Bansal, Kaustubh Srivastava

00 Prelims.indd 25 21-01-2020 15:10:12

Section 5: Application of Jain Point

14. Role of Jain Point in Previous Surgery Cases **125**
Nutan Jain, Swati Kanawa, Sonika Mann, Sunil Gupta

15. Jain Point in Thin Patients **142**
Kiran Kumari Mandal, Anadeep Chandi, Nutan Jain

16. Jain Point in Obese Patients **151**
Kiran Kumari Mandal, Anadeep Chandi, Nutan Jain

17. Laparoscopic Entry in Large Pelvic Masses **164**
Vandana Jain, Nutan Jain

18. Jain Point in Genital Tuberculosis **186**
Nutan Jain, Sonil Srivastava, Anshu Gupta

19. Jain Point in Upper Abdomen Scar **198**
Chetna Agarwal, Nutan Jain, Priyanka Bansal

20. Surgeries Deep in the Pelvis using Jain Point Pelvic Floor Repair **207**
Nutan Jain, Gunjan Saxena

21. Jain Point: Fellow's Experience **224**
Anadeep Chandi, Kiran Kumari Mandal

22. Direct Trocar Entry through Jain Point **234**
Barış Mulayim

Section 6: Jain Point in the Practice of General Surgery

23. Jain Point Port in Ventral Hernia Repair **243**
Siddharth Gupta, Nutan Jain

24. Jain Point in the Practice of General Surgery **254**
Siddharth Gupta, Prateek Gupta, Nutan Jain

Section 7: Complications

25. Entry-related Complications and their Management **277**
Kiran Kumari Mandal, Nutan Jain

26. Extrocation **294**
Nutan Jain, Vandana Jain

Index *299*

Videos Title*

- What is Jain point
- Direct trocar entry through Jain point
- Jain point entry in a case of previous cesarean section
- Jain point entry in flabby abdomen
- Jain point entry in obese patient with previous cesarean sections
- Jain point entry in thin patients
- Jain point entry in a very thin patient with large broad ligament myoma
- Jain point entry in very large myomas
- Jain point entry in a large dermoid cyst
- Laparoscopic management of endometriotic rectovaginal nodule
- Laparoscopic management of extensive endometriosis
- Jain point usage in Burch colposuspension
- Jain point entry in case for paravaginal defect repair
- Laparoscopic pectopexy
- Laparoscopic management of cesarean scar ectopic
- Laparoscopic isthmocele repair
- Tubo-tubal reanastomosis
- TLH with extensive endometriosis
- TLH with extensive adhesions
- TLH with large broad ligament myoma.

**The videos are available on www.emedicine360.com.*

00 Prelims.indd 27 21-01-2020 15:10:12

CHAPTER

2

Overview of Laparoscopic Entry

Artin Ternamian

INTRODUCTION

Endoscopy allows optically guided procedures to be performed within the body, through surgically created temporary ports (laparoscopy, thoracoscopy, and arthroscopy) or through natural conduits, without requiring an entry wound (hysteroscopy, bronchoscopy, natural orifice transluminal endoscopic surgery—NOTES).

These minimally invasive measures are practiced in most specialties and have become a preferred method for diagnosis and treatment of several surgical conditions. Endoscopy is a technology driven dynamic discipline that challenges conventional open surgery and introduces innovative advances that renders robotic surgery, telesurgery, remote telepresence, high-resolution imaging, and surgical macrorobots and makes frameless stereotactic surgery possible.

Principal difference between open and laparoscopic surgery is size of surgical wound. The most important and potentially hazardous first step in laparoscopy is safe and successful insertion of a primary port. As more surgical specialties practice laparoscopy, conventional methods of blind umbilical peritoneal entry may not be uniformly acceptable.

Recently, the US Food and Drug Administration (FDA) in a Laparoscopic Trocar Injuries report recommended surgeons performing sophisticated endoscopic operations to be well-versed in alternate laparoscopic access methods and instruments to address evolving patient expectations and societal safety requirements.[1]

Publication of the USA Institute of Medicine Committee Report on Patient Safety suggests that over 90% of unintended medical mishaps are human error related. Accordingly, surgeons and industry now recognize the need for less hazardous laparoscopic access options especially in high-risk situations.[2]

Moreover, entry methods that can anticipate, avoid, or at the very least recognize error are advocated, where error recovery is possible, before

JAYPEE BROTHERS

permanent patient harm occurs.[3] Ultimately, surgeons must use those access methods and instruments that they are schooled in, feel comfortable using and are safest in their hands. In this chapter, several access instruments and their safe deployment techniques will be reviewed.

ACCESS INSTRUMENTS

Laparoscopic ports perform several important functions, including administration of distending gas, maintenance of operative envelope, placement of optical and operating instruments, safe retrieval of tissue, and preservation of port competence.

Conventional first generation laparoscopic access instruments generally consist of two parts—(1) a removable central trocar and (2) an encasing outer sheath or cannula **(Fig. 1)**. Once placed inside a body cavity, the central trocar is removed to accommodate a laparoscope or various operating instruments. Trocars have a proximal end to accommodate the surgeons' dominant palm and transmit penetration force (PF) generated to the instrument-tissue interface. The distal end is traditionally designed to have a pointed sharp conical, beveled pyramidal, or cutting bladed tip.

Cutting pyramidal or bladed trocars are the most commonly employed devices; as extremely sharp bladed tips render trajectory propulsion, require less PF. These trocars, with the outer casing cannula mounted, transect different myofascial abdominal tissue layers, en route to the intended body cavity.[4]

Extremely sharp disposable access instruments make insertion less forceful and more controlled. However, risk of inadvertent bowel or vessel injury because of extreme sharpness and blind insertion cannot be denied. In some



Fig. 1: Conventional first-generation laparoscopic access instrument with a central trocar and encasing outer sheath or cannula.

JAYPEE BROTHERS

series, risk of bowel injury with disposable access trocars is three times that previously reported for reusable trocars while blunt-tipped trocars present less access risk to vascular or tissue injury.

Disposable bladed access trocars with automatic extending shields were designed to decrease the risk of inadvertent injury. However, as injuries continued to occur, the FDA ordered all device manufacturers and distributors of shielded access trocars to remove all claims of added "safety".

Leibl showed that incisional hernia risk is 10 times greater when disposable cutting pyramidal trocars are used instead of reusable conical trocars (1.83 versus 0.17%).[5]

Conical trocars have pointed nonbladed sharp tips with no cutting edges; these recruit considerably more PF as tissue layers are not transected, but radially parted to accommodate cannulas' outer diameter.[6]

These would have to inflict a "direct hit" on vessels to cause injury as only the tip is sharp, whereas a same sized cutting pyramidal or bladed trocar can do exact significant injury to any vessel along its path.[7] Clearly, trocar tip design is very important when evaluating entry accident causation and port competence **(Figs. 2A to D)**.

The cannula portion of access devices has a proximal valve section to allow insertion and removal of optics or laparoscopic instruments without losing insufflated gas. They may also have a CO_2 insufflation stopcock, particularly those used at primary port site.

The shaft's outer surface is usually smooth or serrated and ends either horizontally or in an oblique slant with a small venting window at their distal end. Recently, threaded shafts have gained popularity as they anchor cannulas at entry site and discourage unintended intraoperative displacement.

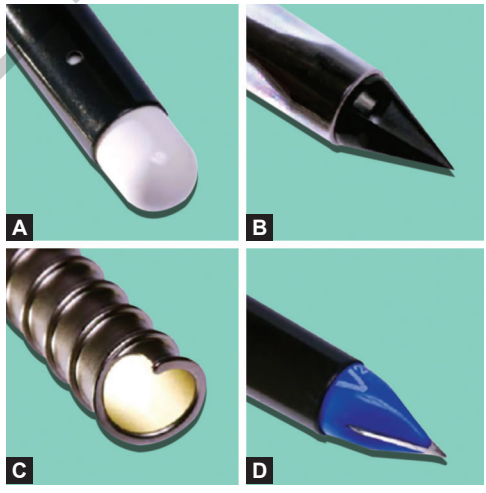

Figs. 2A to D: Different trocar and cannula tips.

JAYPEE BROTHERS

Laparoscopic access instruments are either intended for single or multiple use. Environmental and societal concerns in addition to mounting healthcare costs generally encourage use of reusable instruments.[8]

Moreover, multiple use of single-use designated instrument, especially trocars and cannulas are generally not recommended.[9] Unfortunately, surgeons world over, have less say in operating room purchasing decisions and are called upon to defend outcomes only when mishaps are publicized.

Since exposure of a primary port is not possible unless when using visual access systems, it is always advisable to inspect the parietal peritoneal aspect of primary ports, through an ancillary port, at the end of each laparoscopy.[10] Most gynecologists use a Veress needle to preinsufflate the peritoneal cavity with a noncombustible and easily absorbable gas, usually CO_2, prior to insertion of the primary laparoscopic port. This is intended to further minimize inadvertent access injury during placement of sharp blind trocars; though complications related to their use are rare and well-documented.[11]

Concern regarding their safety, especially at primary port has been expressed as considerable axial PF is applied blindly to thrust a sharp trajectory into the abdomen, resulting in inevitable overshoot. Despite significant advances in endoscopic techniques and instrumentation; potentially avoidable access injuries continue to occur. Several publications indicate that inadvertent trauma to major vessels and bowel remains underreported.[12]

Many of these serious injuries are related to closed laparoscopy, where insertion of the Veress needle during preinsufflation or a sharp trocar and cannula are generally blind steps.

Alternatively, during open laparoscopy, peritoneal entry through a mini cutdown is first secured, followed by insertion of the Hasson trocar and finally the peritoneal cavity is insufflated **(Fig. 3)**. This method is intended to avoid major vessel and bowel injury; however, inadvertent large vessel or bowel injury is not entirely eliminated.[13-16]

Given continued incidence of serious access complications, "visual access" trocars were introduced in 1994 to mitigate access injury by allowing visually guided layered entry.

Two disposable "optical access" trocars are available—one has a conical crystal tip at the distal end of a hollowed trocar that accommodates a sheathed 0° laparoscope to display entry images on the monitor (OptiView XCEL; Ethicon Endo-Surgery, Cincinnati, OH) **(Fig. 4)**; while the other trocar has a spherical crystal tip at the end of a hollowed trocar with an embedded wire blade at the equator that transects anterior abdominal tissue layers at the strike of a trigger. The optical trocar with a 0° laparoscope mounted, is pushed down toward the CO_2 distended peritoneum to display access sequences on the monitor (VisiPort; COVIDIEN, TYCO, Norwalk, CT) **(Fig. 5)**.

Despite their ability to optically display entry tissue layers on the monitor, these instruments retain a conventional trocar and cannula insertion

JAYPEE BROTHERS



Fig. 3: Hassons' open entry trocar and cannula with cone.



Fig. 4: OptiView XCEL, Ethicon, Endo-Surgery. Disposable visual trocar and cannula.

dynamics where entry is achieved by palming the access device and applying considerable perpendicular PF to propel the trajectory into the peritoneal cavity, with no means to control overshoot. Although the degree of risk or serious complications compared to conventional blind sharp trocar and cannula systems remains uncertain, serious access injury can still occur with their use. Moreover, extreme caution has to be exercised, especially when surgeons fail to interpret or recognize displayed entry images.

Some endoscopists advocate gasless laparoscopy where visualization is achieved by suspending the anterior abdominal wall by a mechanical lifting device instead of CO_2 insufflation. Specialized valveless threaded ports with a scored side are used to accommodate conventional open surgical instruments.

JAYPEE BROTHERS



Fig. 5: VisiPort, COVIDIEN, TYCO. Disposable visual trocar and cannula.

The primary access site is dissected down to peritoneum through a mini cutdown and then a lifting device is suspended through the umbilical primary port site to create a tented operating compartment. This method has limited clinical application but may be of value especially in patients who have cardiovascular compromise.[17]

More recently, a radially expanding trocar system has been introduced to decrease the incidence of unintended access injury by sharp trocars (VersaStep trocar; COVIDIEN, TYCO, Norwalk, CT). This disposable instrument retains a conventional trocar design and method of application. It comprises an expandable polymeric outer sleeve that covers a Veress like needle. Following insertion of the sleeve a dilating trocar is deployed for the sleeve to accommodate a laparoscope **(Fig. 6)**.[18]

Better optics, miniaturization and advances in instrument design allowed improvements in rigid and flexible narrow caliber microlaparoscopes that require very small diameter access ports with potential advantages. Some have introduced a visual access system that requires a 1.2 mm semirigid 0° microlaparoscope that fits into a modified Veress type needle (Optical Veress Entry System; Karl Storz Endoscopes GMBH, Tuttlingen, Germany).

This reusable system offers excellent optics. However, it is expensive, has a very short focal point, is very delicate, and can easily fracture given its narrow diameter and heavy top end camera. They can be used through the left upper quadrant in high-risk cases, during diagnostic conscious pain mapping and in critical care or outpatient diagnostic units **(Fig. 7)**.[19]

Second generation laparoscopic access instruments are a more recent addition and consist of only a cannula, where no trocar is required and access is visually monitored in real-time. The reusable bladeless cannula has a

JAYPEE BROTHERS



Fig. 6: VersaStep, COVIDIEN, TYCO. Disposable radially dilating trocar and cannula.

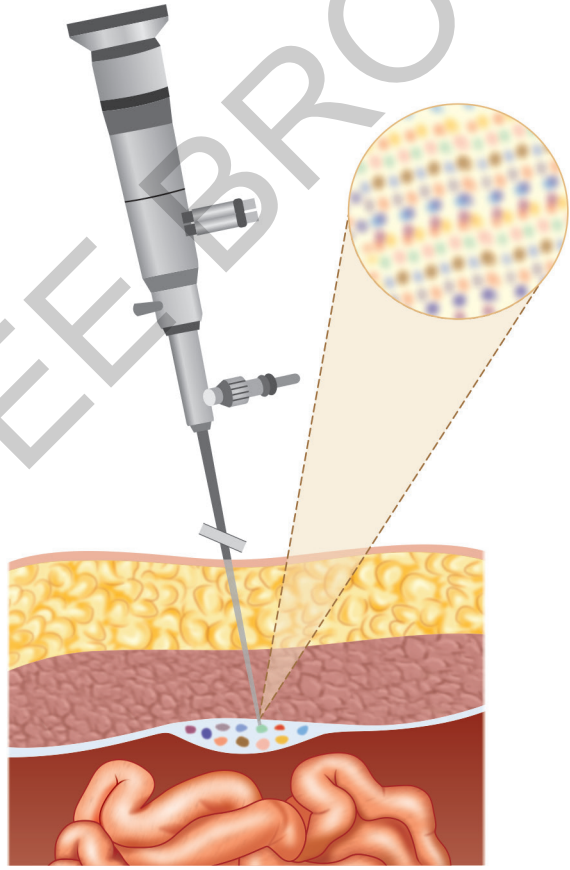

Fig. 7: Microlaparoscopy optical Veress access system.

JAYPEE BROTHERS

conventional valve section at one end to allow insertion and removal of optics or laparoscopic instruments without losing insufflated gas and may house a CO_2 insufflation stopcock. The shaft's outer surface has a single diagonal thread that ends distally in a blunt notched tip **(Fig. 8)**.

During deployment, a 0° laparoscope is sheathed into the cannula and held 1 cm short of the cannulas' distal end by a telescope stopper (TS). Cannulas' rotation engages the myofascial tissue with the notched tip to lift successive anterior abdominal wall layers using the Archimedes' principle **(Fig. 9)**.

As the cannula has no cutting or sharp end, tissue planes are not transected, instead are parted. This preserves port competence as it is shown to result in a smaller fascial entry wound area with less muscle damage compared to pyramidal trocar wounds.[20]



Fig. 8: Endoscopic threaded imaging port (EndoTIP) reusable visual access cannula with telescope stopper.

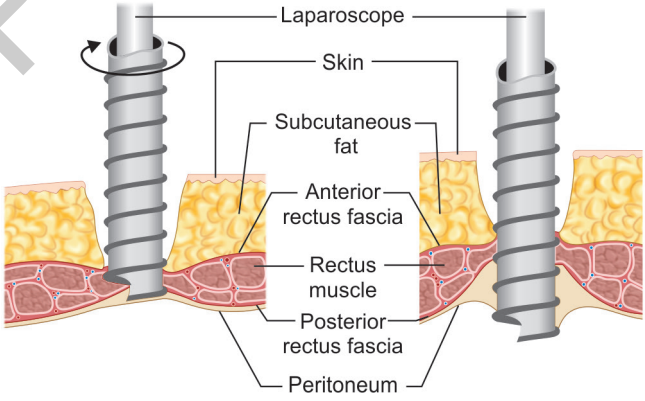

Fig. 9: Layered access with EndoTIP.

JAYPEE BROTHERS

This bladeless visual access cannula system (Endoscopic Threaded Imaging Port, EndoTIP; Karl Storz Endoscopy GMBH, Tuttlingen, Germany) has no crystal tip compressing and distorting monitor images at tissue—cannula interface. Therefore, interpretations of monitor images are easier and layered entry more interactive.

Endoscopists agree that visual and controlled access systems, that deploy less axial PF, require no sharp trocars and allow real-time error analysis, recognition and recovery are preferred. Intuitively, these systems are less dangerous, infer added safety, improve understanding of entry complications, and reduce recurrent inadvertent error.[21,22]

Port Dynamics during Laparoscopy

Like all surgical methods, laparoscopy is associated with some inadvertent patient risk. Serious peritoneal entry complications, such as bowel and vascular injury, continue to occur despite innovative port creation techniques and well-trained surgeons.

Laparoscopic access injury is best understood when tissue dynamics at port site is studied in real-time. Careful error analysis is essential to unravel interaction between surgeon, instrument and tissue. It is known that a minimum of 25% of practicing gynecologists have experienced Veress needle or cannula injuries.[23,24]

Two primary access methods are available in laparoscopy—(1) first-generation conventional access method where a push-through spike principle is applied and (2) second-generation access method where an Archimedean spin principle is employed **(Table 1)**.

Irrespective of instrument make or model, conventional access requires two components, a central trocar with a sharp, cutting, or pointed distal end and an encasing cannula. Surgeons palm the access instrument by their dominant hand and apply PF, generated through the upper arm muscles, axially at port site. This propels the spike across different tissue layers toward the intended

TABLE 1: Laparoscopic access techniques.

First generation spike principle	*Trocar and cannula design*
Insufflated access	Closed conventional T and C high-pressure T and C radially expanding T and C visual T and C
Noninsufflated	Visual Veress mini-laparoscope open Hassons' T and C access direct T and C access gasless laparoscopy
Second generation spin principle	*Visual cannula design*
Endoscopic threaded	Imaging port
EndoTIP	Closed preinsufflated access Open direct access Extraretroperitoneal access

JAYPEE BROTHERS



Fig. 10: EndoTIP with laparoscope mounted and held in position with telescope stopper.

body cavity. Several versions, modifications, and models have attempted to render this access system less perilous while maintaining the spike and cannula design principle intact.

A more contemporary second generation access method uses the spin principle where the entry instrument comprises a reusable bladeless threaded cannula that ends in a notched, blunt tip. No central trocar is required; instead a zero degree laparoscope is mounted into the cannula during insertion and removal. No axial PF is deployed; tissue layers part radially and the visually guided cannula pulls tissue up along its outside thread **(Fig. 10)**.[25]

FIRST-GENERATION INSUFFLATED ACCESS METHODS

A primary port is the first access conduit through which a lens, camera, and light are introduced. Its insertion is a critical step during laparoscopy when most serious unintended injuries occur.

Veress or trocar placement is particularly perilous, as considerable uncontrolled axial PF is applied blindly to sharp instruments. Moreover, all practitioners agree that subsequent ancillary ports must be inserted under direct vision; consequently some endoscopists favor insertion of the primary port under visual control as well, since intuitively, this can further mitigate inadvertent access complications.[26]

Most gynecologists prefer insufflating the peritoneal cavity prior to primary port insertion. Available evidence demonstrates that vascular injuries are seven times more likely to be caused by either the primary or ancillary trocar placement than by the Veress needle.[10]

In a nationwide prospective multicenter Dutch study, Jansen reviewed 25,764 laparoscopies. Five complications were caused by Veress and 68 by trocar insertion.[27]

JAYPEE BROTHERS

In another survey, Veress was implicated in only 2% of Medical Device Reports (MDR) to the US FDA primary access injury reports.[28,29] However, Veress injury was associated with 18% of reported cases in the Physician Insurers Association of America (PIAA) statistics.

Inspection of the supine nondraped abdomen, notation of previous surgical scars, careful abdominopelvic examination, and palpation of the bony landmarks must precede every laparoscopic insufflation and primary port insertion. Patients must remain horizontal until insufflation and primary access is successfully achieved.

The umbilical skin incision should be larger than the diameter of the primary cannula used, to avoid "skin dystocia" and obviate use of excessive PF. Clearly CO_2 leak around a cannula has very little to do with skin incision size and everything to do with the anterior rectus fascial incision size, relative to the cannula's diameter, and tissue recoil.

The Veress needle is then inserted to distend the peritoneal cavity with CO_2 gas. This gas cushion, interposed between an advancing sharp trocar and abdominal viscera compensates for inevitable trocar overshoot and may avert unintended injury.

The braced abdominal wall and distended peritoneum offer counter pressure against the considerable axial PF applied during accessing. In addition, a gas filled spacious cavity allows unobstructed visualization of pelvic-abdominal organs during surgery.

The Veress needle is first inspected, spring mechanism tested and CO_2 stopcock kept open to allow room air to stream into the sealed abdominal cavity as soon as the peritoneal membrane is penetrated. The needle held at the hub by the dominant hand, like a dart, is advanced toward the pelvic hollow in the midline sagittal plane, where there are no large vessels and nonadherent bowel generally moves out of harm's way.

Some advocate lifting the relaxed abdominal wall with the nondominant hand to offer counter pressure against the advancing Veress needle. Two distinct "pops" are usually felt, as it first punctures through anterior rectus fascia, followed by the posterior fascia and peritoneum. Once a second pop is felt, the needle insertion is stopped. When insertion is intraumbilical, only one pop will be felt.[30]

Determining correct placement prior to insufflation has always been a very important step, as failure to achieve and maintain adequate pneumoperitoneum is a common cause of procedural failure. Earlier, correct needle placement was verified with the saline drop and other confirmatory tests; only then the insufflator was connected, set to 15 mm Hg and total instilled CO_2 volumes measured.

It is now accepted that by far the most reliable indicator of correct peritoneal placement is an intraperitoneal pressure reading less than 10 mm Hg (range 4–10 mm Hg). More recently, investigators described a Veress needle

JAYPEE BROTHERS

insertion technique where the Veress tubing is connected and insufflator flow rate set to deliver 1 L/minute during needle insertion.

Only when intraperitoneal needle placement is secure and the pressure reading is less than 10 mm Hg, the insufflation flow rate is safely cranked to high flow and target pressure is raised to 25 mm Hg.[31-33]

More importantly, as soon as the desired intraperitoneal pressure is achieved, the Veress is retrieved, primary and ancillary ports inserted and insufflation pressure dropped to 15 mm Hg. Remember that inadvertent improper Veress needle placement and a high-flow rate may lead to serious complications. The accepted intraperitoneal pressure during laparoscopic surgery is about 15 mm Hg.

When high initial peritoneal insertion pressures are encountered, needles' position may be carefully changed by drawing out or moving it gently sideways, to dislodge the tip that may be resting against a viscus. Alternatively, the abdominal wall can be manually elevated with similar results. Injecting a few milliliters of saline could also be tried.

It is important to make sure that the patient is well-anesthetized with relaxed anterior abdominal muscles, as bucking could record similar elevated readings. When all fails, it is better to remove, inspect for malfunction and then reinsert the Veress anew. If Veress insertion fails on three consecutive attempts for whatever reason, it is recommended to resort to open, visual, or left upper quadrant entry.

Manual abdominal palpation remains a preferred method of determining degree of distention, as measurement of total instilled gas volume is unreliable. Having attained adequate insufflation, the Veress needle is removed and conventional trocar and cannula is inserted toward the distended peritoneal cavity. This basic entry principal has not changed much, since its inception several decades ago and remains a common access method.

Higher intraperitoneal pressure CO_2 gas insufflation is a variation on the conventional closed insertion technique, where insufflation to an intraperitoneal pressure of 25–30 mm Hg is attained using a Veress needle. This splints the anterior abdominal wall and braces the parietal peritoneum against the axial PF of the advancing trocar.

The larger interposes CO_2 gas cushion reduces tenting of peritoneal membrane between the advancing trajectory and great vessels or abdominal viscera.[34-36]

Bowel adherent to parietal peritoneal wall remains susceptible to injury, as insertion is blind and sharp. Once a primary cannula is placed and correct insertion is verified, intraperitoneal pressure must be lowered to about 10–15 mm Hg.

It is recognized that obesity does not adversely affect insufflation volume for a given intra-abdominal pressure. The actual intra-abdominal volume is a

JAYPEE BROTHERS