MEE books, visit our website www.jaypeebrothers.com, for detailed information on PGMEE book

Gold Standard Book

GMEE books, visit our website www.jaypeebrothers.com, for detailed information on PGMEE book

JAYPEE

Gold Standard Book
for PGMEE Preparation

Volume 1

Part A

Includes Special AIIMS Pattern Questions

AIIMS ESSENCE

2019–2018

Authentic Questions of AIIMS PG Entrance Examination with Finest Explanations and References from Standard Textbooks



Pritesh Singh

6th Edition

Contents

Special AIIMS Pattern Questions *xvii-xxxii*

PART A

1. AIIMS November 2019 Questions **1-A–24-A**
Explanations *25-A–255-A*

2. AIIMS May 2019 Questions **257-A–276-A**
Explanations *277-A–450-A*

3. AIIMS November 2018 Questions **1–16**
Explanations *17–183*

4. AIIMS May 2018 Questions **193–208**
Explanations *209–376*

PART B

5. AIIMS November 2017 Questions **377–392**
Explanations *393–573*

6. AIIMS May 2017 Questions **577–600**
Explanations *601–802*

7. AIIMS November 2016 Questions **807–830**
Explanations *831–1003*

8. AIIMS May 2016 Questions **1007–1022**
Explanations *1023–1211*

9. AIIMS November 2015 Questions **1215–1230**
Explanations *1231–1414*

10. AIIMS May 2015 Questions **1415–1430**
Explanations *1431–1596*

AIIMS NOVEMBER 2018

Multiple Choice Questions

ANATOMY

1. What is the action of marked muscle in the given image?



a. Elevation
b. Depression
c. Protraction
d. Retraction

2. Occlusion of the artery supplying the marked area will cause all of the following except:



a. Rectal incontinence
b. Urinary incontinence
c. Apraxia
d. Perianal anesthesia

3. Identify the marked nerve in the given section of cranial cavity:

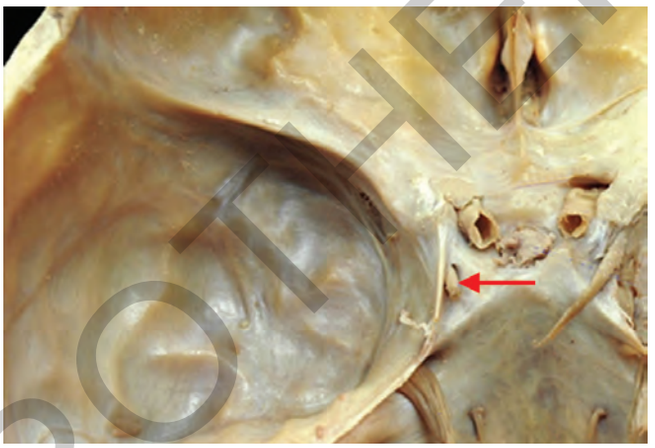

a. Oculomotor
b. Trochlear
c. Trigeminal
d. Abducent

4. Identify the marked layer in the given histological section:

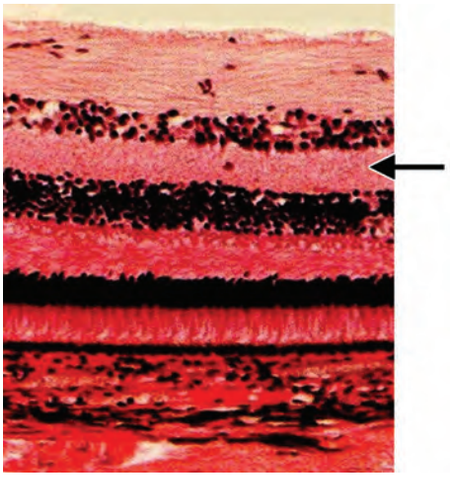

a. Inner plexiform layer
b. Outer plexiform layer
c. Inner limiting layers
d. Outer limiting layer

5. Which of the following is normally seen in the lumbar spine?

a. Scoliosis
b. Lordosis
c. Kyphosis
d. Recurvatum

6. What is the location of Meissner's corpuscles?

a. Lucidum
b. Basale
c. Reticular dermis
d. Papillary dermis

JAYPEE BROTHERS

7. Type of connective tissue present in the arrow marked area is:

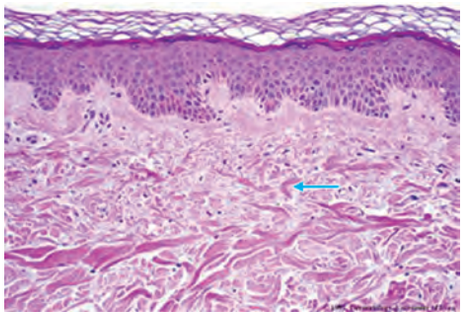

a. Loose and irregular
b. Specialized
c. Dense regular
d. Dense irregular

8. Correct pairing regarding lymph node and their anatomical boundaries is:

a. Level 3: Cricoid to clavicle
b. Level 4: Hyoid to cricoid
c. Level 5: Base of skull to cricoid
d. Level 6: Hyoid to suprasternal notch

9. All of the following muscles help in inversion of foot except:

a. Tibialis anterior
b. Tibialis posterior
c. Peroneus longus
d. Extensor halluces longus

10. Which of the following cranial nerve is not associated with olfaction?

a. V
b. IX
c. X
d. XII

11. All of the following bones are involved in the formation of wrist except:

a. Scaphoid
b. Radius
c. Ulna
d. Triquetral

12. Ligamentum flavum consists of:

a. Type-I collagen
b. Type-II collagen
c. Reticulin
d. Elastin

13. Patient with syphilis developed imbalance on walking with eyes closed and had to lift up foot and stamp on ground to walk. Name the tract involved in the given condition:

a. Spinocerebellar tract
b. Dorsal column tract
c. Lateral spinothalamic tract
d. Vestibulospinal tract

14. Golgi apparatus in serous acinar cells is located at:

a. Supranuclear
b. Apical
c. Adjacent to nucleus
d. Basal

15. Left superior intercostal vein drains into:

a. Azygous vein
b. Hemi azygous vein
c. Brachiocephalic vein
d. Internal thoracic vein

PHYSIOLOGY

16. Erythropoietin acts on:

a. Burst forming unit (BFU)
b. Colony forming unit (CFU)
c. Normoblast
d. Late erythroblast

17. Integrin connects actin to which macromolecule in extracellular matrix?

a. Laminin
b. Collagen
c. Fibronectin
d. Vitronectin

18. According to Weber-Fechner's Law, strength of stimulus perceived is directly proportional to:

(AIIMS November 2018, May 2016)

a. Number of muscle fibers
b. Number of nerve Fibers
c. Number of stimulus
d. Intensity of stimulus

19. Maximum area in homunculus signifies:

a. Low control and skilled movements
b. More muscle fibers are present
c. Increased preciseness of movements
d. None of the above

20. In the histology section given, which marked area is involved in relieving pain in response to massage:



a. A
b. B
c. C
d. D

21. Fibers reaching directly to Purkinje cell of cerebellum arise from which of the following?

a. Vestibular nucleus
b. Inferior olivary nucleus
c. Raphe nucleus
d. Locus ceruleus

22. Calculate net filtration with the following data:

P_{GC} = 42 mm Hg
π_{GC}= 12 mm Hg
P_{BC} = 12 mm Hg
Assume that no proteins were filtered:

a. 14 mm Hg
b. 28 mm Hg
c. 34 mm Hg
d. Data not sufficient

23. Hormones which is/are under inhibitory control of hypothalamus:

a. Prolactin
b. Prolactin only
c. Growth hormone
d. Both growth hormone and prolactin

24. Which of the following hormones has a permissive action at the onset of puberty?

a. Leptin
b. GnRH
c. Insulin
d. Growth Hormone

25. Which of the following heart sound may be a normal finding during pregnancy?

a. Fixed splitting of S2
b. S3
c. S4
d. Pericardial knock

JAYPEE BROTHERS

26. Which cell organelle is absent in cardiac muscle in the region marked by arrow?

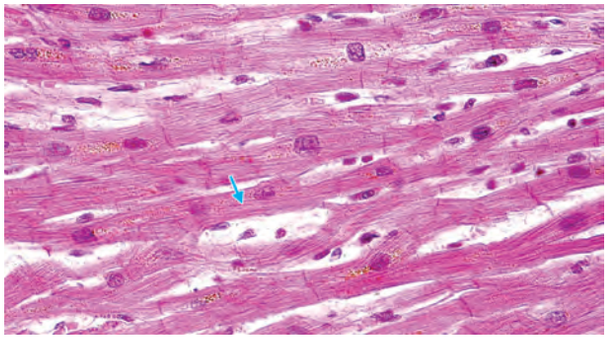

a. Mitochondria
b. Golgi body
c. Smooth endoplasmic reticulum
d. Lysosome

27. Compliance curve of the lung given below: Curve A signifies which of the following:

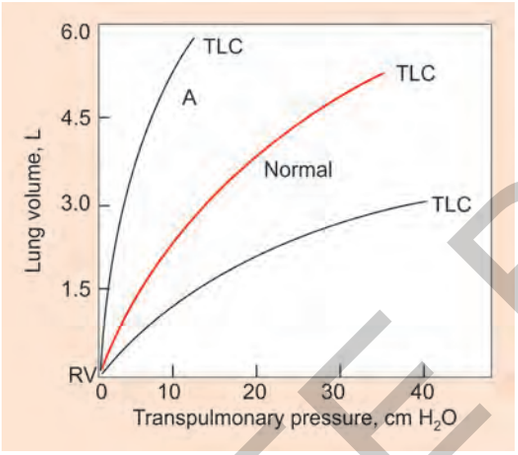

a. Pulmonary fibrosis b. Atelectasis
c. Emphysema d. ARDS

BIOCHEMISTRY

28. Which of the following is rapid source of energy by resynthesizing ATP for exercising muscles is? *(AIIMS November 2018, November 2016)*

a. Glycolysis b. TCA cycle
c. Phosphocreatine d. Glycogenolysis

29. In a child with cerebrohepatorenal syndrome and with hypotonia and hepatomegaly, the probable biochemical defect is accumulation of:

a. Pyruvate b. Acetyl Co-A
c. Short-chain fatty acid
d. Very long-chain fatty acid

30. Respiratory quotient after heavy carbohydrate meal is: *(AIIMS November 2018, November 2016)*

a. 0.7 b. 0.8
c. 1 d. 1.2

31. Northern blot is used for:

a. RNA b. DNA
c. Protein d. DNA protein interaction

32. Biomarker of alcoholic hepatitis is:

a. ALP b. GGT
c. AST d. LDH

33. Method of transport of glucose in the intestine is:

a. Simple diffusion
b. Secondary active transport
c. Primary active transport
d. Counter transport

34. In noncompetitive antagonism which of the following is correct?

a. K_m decreases b. V_{max} decreases
c. No change in V_{max}
d. Both K_m and V_{max} increases

35. Which of the following will occur normally in the body of the patient with type 1 diabetes mellitus having complains of polyuria?

a. Glycogenesis in muscle
b. Increased protein synthesis
c. Decreased cholesterol synthesis
d. Increased conversion of fatty acid to acetyl CoA

PATHOLOGY

36. Which of the following tubes contain Sodium fluoride as anticoagulant?

a. 

b. 

c. 

d. 

JAYPEE BROTHERS

37. Identify the inheritance pattern in the given pedigree:

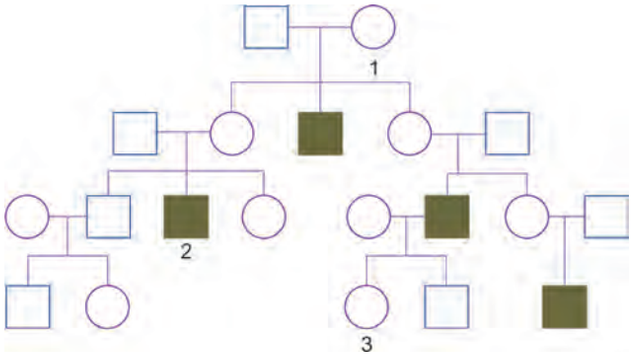

a. X-linked dominant b. X-linked recessive
c. Y-linked dominant d. Y-linked recessive

38. Naive T-cell gets activated by:

a. NK cell b. Dendritic cell
c. Macrophage d. B-lymphocyte

39. Macrophage engulfs different cells as shown in the image, the process is called:

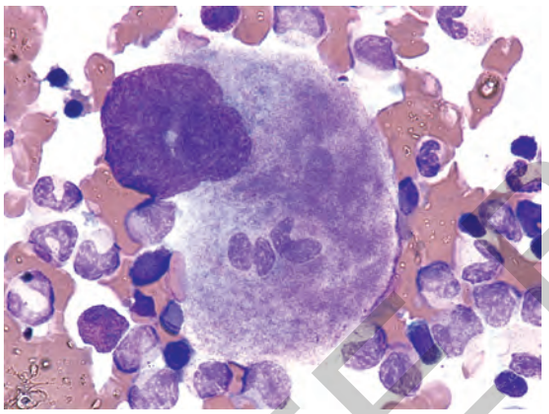

a. Phagocytosis b. Emperipolesis
c. Killing d. Cytotoxicity

40. Which of the following are involved in antibody dependent killing?

a. NK cell b. NK cell only
c. Macrophage
d. NK cell, neutrophils and macrophage

41. Immune privilege site is:

(AIIMS November 2018, November 2015)

a. Optic nerve b. Seminiferous tubule
c. Area postrema d. Spinal cord

42. Which of the following can recognize dead material?

a. NET b. Inflammasome
c. Necrosis d. Toll like receptor

43. A patient comes with chronic diarrhoea with normal D-xylose test and abnormal schilling test. Duodenal biopsy is normal. What is the probable diagnosis?

a. Celiac disease b. Ulcerative colitis
c. Ileal disease
d. Intestinal lymphangiectasia

44. Which is false about apoptosis?

a. No inflammation
b. Plasma membrane intact
c. Organelle swelling
d. Affected by dedicated genes

45. A trauma patient presents at emergency department. There is no time for cross matching. FFP of which group can be transfused safely?

a. O Rh D + b. O Rh D –
c. AB Rh D + d. AB Rh D –

46. Identify the marked structure in given below image:

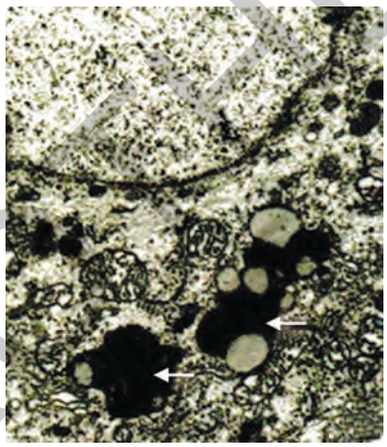

a. Lipofuscin granules
b. Lysosomes
c. Secondary lysosomes
d. Phagolysosome

47. An intern while collecting blood spill it over the floor. What should be done next?

a. Mop the floor
b. Put some absorbable material over it
c. 1% sodium hypochlorite
d. Inform the infection control board of hospital

48. Immunofluorescence staining pattern from a kidney biopsy from a 35-year-old patient presenting with proteinuria has been shown below. What is the most probable cause?

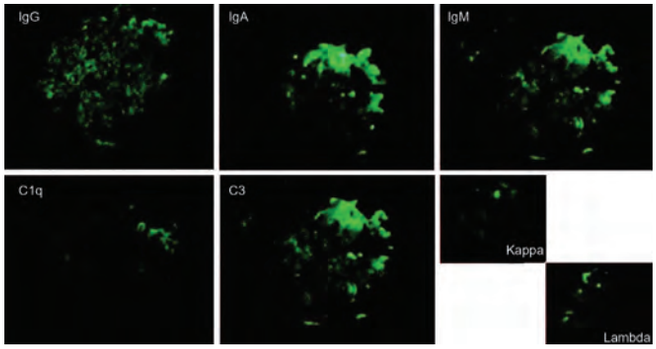

a. PSGN b. FSGS
c. Lupus nephritis
d. Goodpasture's syndrome

JAYPEE BROTHERS

49. Anti-centromere antibodies are seen in which of the following conditions?

a. SLE b. Drug induced lupus
c. Sjögren syndrome d. Scleroderma

50. A patient presented with intermittent fever, no weight loss, no anorexia, but with a retroperitoneal mass. Peripheral smear findings were normal. Gross and microscopy of the mass is given. What's the diagnosis?

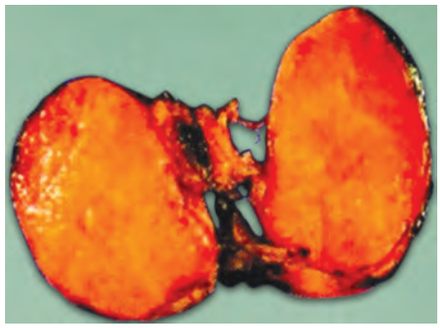

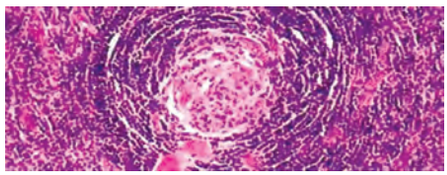

a. NHL b. Castleman's disease
c. Angiolymphoid hyperplasia
d. IgG4 disease

51. How will you differentiate a mediastinal mass being a thymoma or ALL?

a. CD1a b. Cd3
c. Tdt d. Cytokeratin

PHARMACOLOGY

52. Side-effects of salbutamol are all *except*:
(AIIMS Nov 2018, May 2018)

a. Hypokalemia b. Hypoglycemia
c. Tachycardia d. Tremor

53. Loading dose of a drug depends on:
(AIIMS Nov 2018, May 2018)

a. Volume of distribution
b. Bioavailability
c. Half-life d. Clearance

54. Low apparent volume of distribution indicates:

a. Low bioavailability
b. Low $t_{1/2}$
c. Very low efficacy
d. Drug is not extensively distributed in organs and tissues

55. Diamox is given for glaucoma, which is a noncompetitive antagonist of carbonic anhydrase. The effect is due to:

a. Increase in K_m and V_{max}
b. Decrease in K_m
c. Decrease in V_{max}
d. No change in V_{max}

56. Which of the following drug is used to prevent acute mountain sickness?

a. Acetazolamide b. Dexamethasone
c. Diltiazem d. Digoxin

57. Which of the following drug is gametocidal for all species of Plasmodium?

a. Quinine b. Chloroquine
c. Primaquine d. None

58. A male with insulin dependent diabetes having macular edema develops glaucoma. Which drug should be used as the least resort to treat?

a. Alpha agonist b. Prostaglandin analogue
c. Pilocarpine d. Beta blocker

59. Abnormality to check if lithium is given to a pregnant female:
(AIIMS November 2018, November 2010)

a. Cardiac anomaly b. Urogenital defect
c. Neural tube defect d. Facial defects

60. If carbamazepine is added to valproate, which of the following side effects increases?

a. Thrombocytopenia b. Hepatotoxicity
c. Hyperammonemia d. Pancreatitis

61. Antitubercular drug causing ophthalmic toxicity is:

a. Rifampicin b. Isoniazid
c. Ethambutol d. None of above

62. All of the following drugs increase bleeding when given to a patient on warfarin except:

a. Isoniazid b. Amiodarone
c. Carbamazepine d. Cimetidine

63. Primary action of nitrates in patient of angina:

a. Coronary vasodilation b. Decreases preload
c. Decreases afterload d. Decreases heart rate

64. The technique given in the picture is used for:

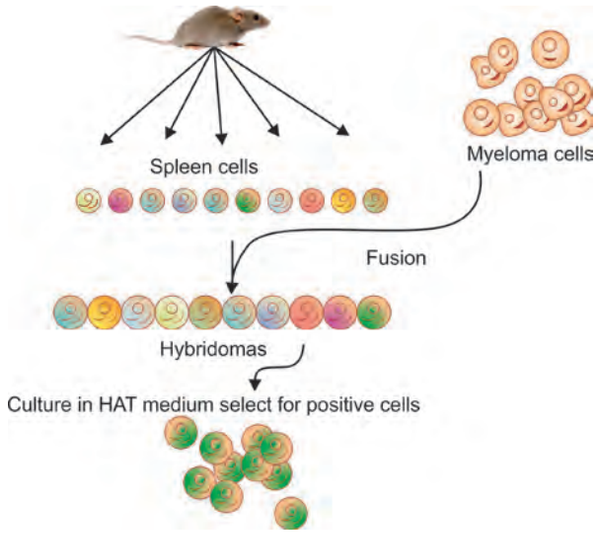

a. Synthesis of monoclonal antibodies
b. Preparing cell lines for viral culture
c. Synthesis of vaccine
d. Process of genetic engineering

JAYPEE BROTHERS

65. Store a drug in a cool place refers to storing at the temperature of:
a. Below freezing point of water
b. 0°
c. 2°– 4°
d. 8°–15°

66. A 16 years old girl was on antiepileptic for treatment of seizure episodes while asleep. She had no seizure for 6 months and NCCT and EEG was normal. What is further management?
a. Stop treatment
b. Continue for 2 years
c. Life-long treatment
d. Stop treatment and follow-up with 6 monthly EEG

67. A patient is on indinavir, zidovudine, lamivudine and ketoconazole. He developed breast hypertrophy, nephrolithiasis, hyperlipidemia and central obesity; identify the drug causing these side effects amongst all:
a. Lamivudine
b. Indinavir
c. Ketoconazole
d. Zidovudine

68. Which of the following is correct regarding T3 and T4 acting on TRH?
a. It activates phospholipase A
b. It acts on transcription factor
c. It acts by increasing cAMP
d. It is a tyrosine kinase receptor

69. Morphine should not be given in a patient with:
a. Ischemic pain
b. Cancer pain
c. Biliary colic
d. Postoperative pain

70. Dapsone is used as antibacterial, antifungal and as immunomodulator. What is the mechanism behind all these actions?
a. Inhibition of cell wall synthesis
b. Inhibition of sterol of the cell wall
c. Inhibition of protein synthesis in ribosomes
d. Competes with PABA in folic acid synthesis

71. Schedule of drug to be sold only on prescription is: *(AIIMS November 2018, November 2015)*
a. Schedule H
b. Schedule P
c. Schedule G
d. Schedule X

72. In a rheumatic heart disease pregnant female with prosthetic valve, when should we switch to heparin?
a. 32 weeks
b. 36 weeks
c. 37 weeks
d. 40 weeks

73. Phase 1 trial is done to test:
a. Safety
b. Efficacy
c. Dose
d. Pharmacokinetics

74. Mechanism by which acetylcholine decreases heart rate is by:
a. Delayed diastolic depolarization
b. Increase in plateau
c. Decrease preload
d. Increase afterload

75. Nitroprusside active metabolite acts by:
a. Phosphokinase 1.2
b. Guanylyl cyclase
c. Phospholipase A
d. Phospholipase B

76. Pediatrician attended infant with unconjugated serum bilirubin level of 33 mg/dL. Which drug mother might have taken in 3rd trimester?
a. Azithromycin
b. Chloroquine
c. Ampicillin
d. Cotrimoxazole

77. Dose reduction is required in renal failure with all *except*:
a. Amphotericin B
b. Vancomycin
c. Doxycycline
d. Gentamicin

78. For a patient of hypertension on metoprolol, verapamil was given; this will result in:
a. Atrial fibrillation
b. Bradycardia with AV block
c. Torsades de pointes
d. Tachycardia

MICROBIOLOGY

79. Post-renal transplant patient presents with diarrhea after 3 months; it was showing organism measuring 2-6 micron meter and Kinyoun stain positive. Most likely it is caused by:
a. Balantidium coli
b. Clostridium difficile
c. Cystoisospora belli
d. Cryptosporidium hominis

80. A patient was brought to the emergency with history of passage of small amounts of repeated thin stools with mucus, subjective feeling of fever and lower abdominal pain, with leukocytes in stool. Which of the following is organism is most likely responsible?
a. Giardia
b. Entamoeba
c. Staph. aureus
d. Clostridium perfringens

81. A patient is having thick, gray coating on the throat and tonsils, followed with fever, chills and swollen glands in the week. Microscopic examination of nasopharyngeal or pharyngeal swab showed gram-positive organism with a special stain. The constitutes of the stain are:
a. Crystal violet, Gram's iodine
b. Toluidine blue, malachite green, glacial acetic
c. Carbol fuchsin, acid alcohol, and methylene blue
d. Methylene blue

82. IFN-beta is stimulated by:
a. Bacterial infection
b. Viral infection
c. Fungal infection
d. Mycoplasma infection

83. Patient with history of kidney transplantation presenting with diarrhoea. (Video of worms was given). The motility of the worms was given in the figure. Correct statement about the organism is:



JAYPEE BROTHERS

a. Monoecious and the organism related with parthenogenesis
b. Transmitted by intake contaminated food and water
c. Loffler's pneumonia is not caused by the same organism
d. Body gets this infection through filariform larvae

84. The causative agent of bacterial meningitis in a 1-year child is:

a. Neisseria meningitides b. Pneumococcus
c. H. influenzae d. Listeria

85. 200 people attended a party and some of them had diarrhea after 24 hours. They ate oyster, hamburger, ice-cream and potato salad. What's the most likely cause?

40 ill from 50 who consumed oyster
50 ill from 135 who consumed hamburger
60 ill from 140 who consumed salad
49 ill from 115 who consumed ice cream

a. V. parahaemolyticus b. Salmonella enteritidis
c. Yersinia enterocolitis d. Staph aureus

FORENSIC MEDICINE

86. All of the following are included in aggravated penetrative sexual assault under POCSO act 2012 except:

a. Threatening b. Gang
c. During communal or secular violence
d. By police officer

87. In case of professional misconduct, patient's records on demand should be provided within?

a. 36 hours b. 48 hours
c. 72 hours d. 7 days

88. Bullet fingerprinting is:

a. Human fingerprints on bullet
b. Primary markings
c. Secondary markings d. Distorted bullet

89. Identify the post-mortem lividity of the image:



a. Tattooing b. Suggillation
c. Putrefaction d. Decomposition

90. A female was found dead in her bedroom. The room was not locked from inside. Blood value of alcohol was 350 mg/dL with image of face, open neck and viscera. Picture was given of bruises on neck (likely 6 penny bruises), cyanosed lip. Dissected neck was showing soft tissue ecchymosis. What is the cause of death?



a. Traumatic asphyxia b. Throttling
c. Café coronary d. Bansdola

91. In the given below image, the hands present with hyperpigmentation. It occurs due to:



a. Chronic $CuSO_4$ poisoning
b. Application of Calotropis
c. Long-term ingestion of arsenic water
d. Application of mercury ointment

92. Within how many days a vaginal swab can be taken from a rape victim?

a. 2 days b. 3 days
c. 4 days d. 7 days

93. In the case of concentric teeth bite mark on forearm, what should be done next?

a. 2 swab technique for saliva collection
b. Keep scale for measuring below the mark and take photo in the plane of bite
c. Complete description of injury as seen
d. Prepare cast using vinyl polysiloxane

94. An 18 years old girl was brought to OPD, labia majora separated, labia minora flabby, fourchette tear present and vagina is roomy but hymen is intact. What could be possible?

a. Virgin b. False virgin
c. Premenstrual stage d. Molestation

95. Identify the fracture given in the below image:



JAYPEE BROTHERS

a. Pond b. Gutter
c. Comminuted d. Hinge

96. Identify the lesions in the given below image:



a. Abrasion b. Laceration
c. Imprint d. Grazes

PSM

97. The depicted image below represents the symbol of:



a. Biomedical waste b. Cytotoxic waste
c. Radiation hazard d. Bioterrorism

98. All of the following vaccine given under universal immunization program of India except:

a. Rotavirus b. Influenza
c. Adult JE d. Measles and Rubella

99. Following blood transfusion, blood bags are disposed in which colour coded bin?

a. Red b. Yellow
c. Blue d. White

100. Period of isolation for measles is from:

a. Onset of catarrhal symptoms to 3 days after
b. Onset of catarrhal symptoms to 7 days after
c. Onset of catarrhal symptoms to 6 days after
d. Onset of catarrhal symptoms to 8 days after

101. TB is transmitted through droplets mode of transmission; which other disease also has droplet mode of transmission and isolation is done?

a. Pertussis b. Atypical pneumonia
c. Faucial diphtheria d. Hepatitis B

102. A health center reports 40 to 50 cases in a week in the community. This week there are 48 cases normally. This kind of occurrence is called:

a. Epidemic b. Sporadic
c. Endemic d. Outbreak

103. The test used to identify frozen vaccine is:

a. Shake test b. Habel test
c. Shick test d. Twist test

104. Supplementary nutrition provided in the Mid-day meal program should satisfy:

(AIIMS November 2018, November 2017)

a. 1/3 of the total protein requirement + 1/2 of the total energy requirement
b. 2/3 of the total protein requirement + 1/2 of the total energy requirement
c. 1/2 of the total protein requirement + 1/3 of the total energy requirement
d. 1/2 of the total protein requirement + 2/3 of the total energy requirement

105. All of the following related with the following image is right except:

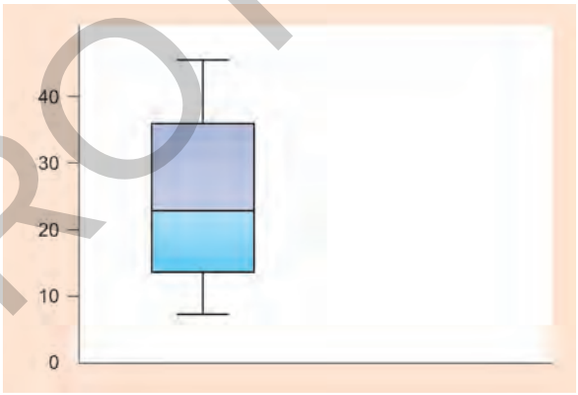

a. Negatively skewed
b. Positively skewed
c. 75% values are above 25 mg
d. Median in 50 mg

106. The below picture indicated the life cycle of:



a. Japanese encephalitis b. Influenza
c. Nipah virus d. Chandipura virus

107. Pick the right answer when 2 screening tests are done in series:

a. Increased sensitivity and decreased specificity
b. Increased specificity and decreased sensitivity
c. Increased sensitivity and increased specificity
d. Decreased sensitivity and decreased specificity

JAYPEE BROTHERS

108. In a clinical trial, blood pressure was measured in a group of patients before and after treatment. Which of the following test will be suitable as at test of significance?

a. Paired t-test
b. Mann Whitney U test
c. Student test
d. ANOVA

109. In a clinical trial, blood pressure was measured between 2 independent groups following treatment, which of the following test will be suitable as at test of significance?

a. Paired t-test
b. Unpaired t-test
c. ANOVA
d. Chi-square

110. Which of the following true regarding the following images?

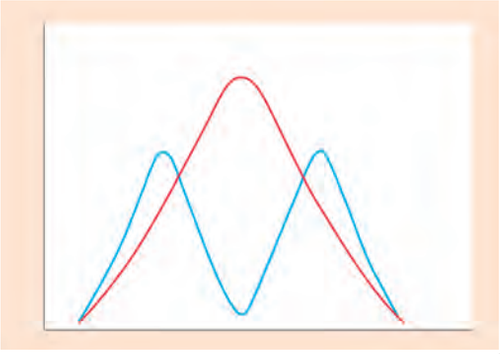

a. Mean = Median = Mode
b. Mean = Median, not equal to Mode
c. Mean = Mode, not equal to Median
d. Mean, Median and Mode are not equal

111. A known case of TB is now resistant to rifampicin and isoniazid. Which of the following would be most appropriate in treating this patient?

a. 6 drugs for 4 months; 4 drugs for 12 months
b. 6 drugs for 6 months; 4 drugs for 18 months
c. 4 drugs for 4 months, 6 drugs for 12 months
d. 5 drugs for 2 months; 4 drugs for 1 month; 3 drugs for 5 months

112. The kit in the picture is used for treatment of:

(AIIMS November 2018, November 2015)



a. Influenza
b. Leprosy
c. Kala Azar
d. TB

113. A newly introduced vaccine include all of the following except:

a. Rota virus
b. Influenza
c. Dengue
d. Malaria vaccine

MEDICINE

114. Nobel prize for medicine/physiology in 2018 was given for the discovery of:

a. Apoptotic pathway
b. Crispr-Cas9
c. Negative immune regulation
d. Molecular mechanisms controlling circadian rhythm

115. Which of the following cannot be diagnosed without positive ANA?

a. SLE
b. Drug induced lupus
c. Sjögren
d. Scleroderma

116. Infertility in Kartagener's syndrome is due to:

(AIIMS Nov 2018, May 2018)

a. Oligospermia
b. Blockage of epididymis
c. Asthenozoospermia
d. Undescended testes

117. ECG with "mean" axis of 90°; In which lead there would be the maximum voltage of R wave?

a. I
b. III
c. aVF
d. aVL

118. Which of the following is not done before ABG?

a. Allen's test
b. Heparin to rinse the syringe
c. Flexion of wrist
d. Poking at 45° angle

119. Patient had recurrent optic neuritis of both eyes with extensive transverse myelitis. Visual acuity in right eye is 6/60 and visual acuity in left eye 6/18. Patient showed 50% response to steroids. Diagnosis is:

a. Neuromyelitis optica
b. Neurosyphilis
c. Posterior cerebral artery stroke
d. Subacute combined degeneration of spinal cord (SACD)

120. A patient who is a known case of CKD has complaints of vomiting. His ABG reports are as follows: pH – 7.40, pCO_2 – 40, HCO_3 – 25, Na – 145, chloride-100. The findings are suggestive of:

a. Normal anion gap met acidosis
b. High anion gap met acidosis
c. No acid base abnormality
d. High anion gap metabolic acidosis with metabolic alkalosis

121. Death due to smoke inhalation is due to:

a. Hypoxemia
b. Anemic hypoxia
c. Ischemic hypoxia
d. All of the above

122. Patient who is known case of thalassemia major already on repeated blood transfusions with history of iron overload previously treated with chelating agents. She also has a history of cardiac arrhythmia. She came for BT now. During BT patient complained of backache and looks extremely anxious. What is next management?

a. Observe for a change in colour of the urine
b. Continue BT, do ECG
c. Stop BT and wait for patient to get normal and start
d. Stop BT and do clerical check

JAYPEE BROTHERS

123. Relative bradycardia is uncommon in:
a. Brucellosis b. Typhoid
c. Malaria d. Factitious fever

124. Which of the following is not useful in measuring cardiac output?
a. Transthoracic echocardiogram
b. Central venous catheter
c. Thermodilution pulmonary catheter
d. Continuous cardiac output pulmonary catheter

125. What is the best marker in KDIGO criteria to differentiate renal from pre-renal acute kidney injury?
a. U_{osm} b. Urinary Na
c. Urinary NGAL d. U_{Na} x Scr / SNa x Ucr

126. While measuring blood pressure of a cardiac tamponade patient, what advice will you give him?
a. Hold breath b. Breathe normally
c. Long and deep breathing
d. Short and shallow breaths

127. A 60 years old female patient has left sided weakness since 1 hour and left sided facial weakness with BP, 160/100 mm Hg. The CT scan is normal, what is the next best step?
a. Start thrombolysis
b. Give loading dose of aspirin and clopidogrel
c. Manage BP alone
d. No interventions needed

128. Patient presents with recent onset breathlessness and ECG is taken. ECG is shown below. What is the diagnosis?

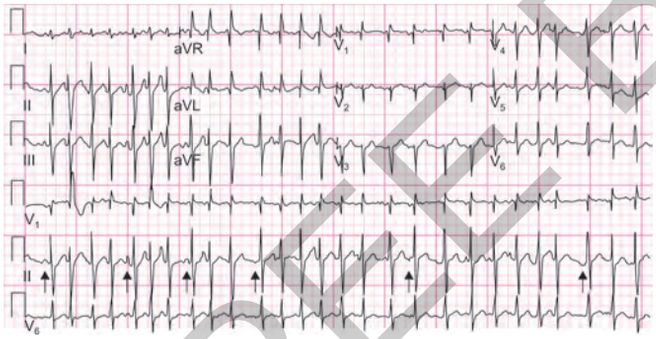

a. AF b. PSVT
c. AMI d. MAT

SURGERY

129. How to differentiate cardiac tamponade from tension pneumothorax? *(AIIMS November 2018, November 2015)*
a. Raised JVP b. Breath sounds
c. Raised heart rate
d. Not improving after initial fluid resuscitation

130. While doing emergency laparotomy for an intestinal obstruction, which organ should you first visualize to say whether it is small bowel or large bowed obstruction?
a. Ileum b. Cecum
c. Sigmoid colon d. Rectum

131. A patient underwent thyroidectomy for hyperthyroidism. Two days later he presented with features of thyroid storm. What is the most likely cause? *(AIIMS November 2018, November 2015, ComedK 2007)*
a. Infection
b. Inadequate preoperative preparation
c. Thyroiditis
d. Rough handling of thyroid at surgery

132. Patient with massive hemorrhage presents to the ER after RTA. What's not to be done?
a. Massive transfusion of fluid challenge
b. IV crystalloid 2L, within few minutes
c. Early tranexamic acid recommended
d. Check coagulation with thromboelastography, if available

133. Following a RTA, a young man was brought to ER. Due to massive blood loss, 2 units of PRBC and 4 platelets obtained from blood bank. Only one IV line was accessible. What will you do?
a. Start PRBC 1st and store platelet in room temperature
b. Start platelet and store PRBC in room temperature
c. Only transfuse PRBC
d. Transfuse PRBC and store platelet at 2-6 degrees

134. Patient had a RTA and put on mechanical ventilation, he is opening his eyes on verbal command, moves all his 4 limbs spontaneously. What will be his GCS score?
a. 9 b. 10
c. 11 d. 12

135. A young patient has been admitted with RTA and had massive hemorrhage. He needs to be transfused with large amounts of fluids. Which IV cannula is preferred?
a. Grey b. Green
c. Pink d. Blue

136. A patient came with profuse diarrhea and dehydration reaches OPD. For examination flow of fluids which cannula can be inserted:
a. Grey b. Green
c. Blue d. Violet

137. What is the colour of 16F Foley's catheter?
a. Orange b. Blue
c. Yellow d. Black

138. A patient came with a chest trauma and tachypnea (Respiratory rate >40/minute) and after checkup he had hypertension (BP- 90/60 mm Hg) and hyperresonant note on involved side. What will be the next step?
a. Intubate b. Chest X-ray
c. IV fluids
d. Wide bore needle insertion on 2nd intercostal space

139. What is the method of breast examination depicted in the video? (The clinician was palpating with tips of finger except thumb started from 2 o'clock posterior palpated at 3 points on line joining periphery to nipple. Then again went to 3 o'clock point directly and came back centripetally while palpating at 3 points again on the line joining periphery and nipple).

JAYPEE BROTHERS

a. Vertical strip method b. Concentric method
c. Dial of Clock method d. Quadrant method

140. Which is the most conspicuous sign in breast cancer?
a. Nipple retraction b. Peau d'orange
c. Puckering
d. Both nipple retraction and puckering

141. What technique has been depicted in the image?



a. Brachytherapy
b. USG
c. Sentinel lymph node biopsy
d. Lateral pectoral nerve block

142. Sentinel lymph node biopsy is most useful for:
a. Carcinoma cervix
b. Carcinoma endometrium
c. Carcinoma vulva
d. Carcinoma vagina

143. What is the name of the given instrument is used for harvesting the graft from healthy area in split thickness skin graft?



a. Dermatome
b. Silver's knife
c. Catlin amputating knife
d. Humby knife

144. Name of the given instrument:



a. Gamma camera b. Chemoport
c. IVC filter d. Pacemaker

145. Which flap-based procedure is used for pilonidal sinus surgery?
a. Rhomboid flap b. Circular flap
c. Free flap d. Rotational flap

146. The given below device is:



a. Pneumatic compression stocking to prevent the DVT
b. Varicose vein
c. Hypothermia d. Cellulites

OBS AND GYNAE

147. Which of the following is not included in quadruple test for antenatal detection of Down syndrome?
a. AFP b. β- hCG
c. Estradiol d. Inhibin-B

148. Dose of levonorgestrel used for emergency contraception is:
a. 1–3 mg within 72 hours
b. 1.5 mg within 72 hours
c. 1.5 µg within 72 hours
d. 3 µg within 72 hours

149. A postmenopausal female with biopsy report as endometrial hyperplasia with atypia. Next line of management is:
(AIIMS November 2018, November 2017)
a. Hysterectomy b. Mirena
c. Oral progestins
d. Dilatation and curettage

150. Maternal mortality rate is expressed in:
a. Maternal death per 10,000 lives
b. Maternal death per 100 lives
c. Maternal death per 100,000 lives
d. Maternal death per 1,000,000 lives

151. A 40 years old female was diagnosed with CIN-3. What will be the management?
a. Trachelectomy b. Hysterectomy
c. Conization d. Colposcopy + LEEP

152. What should be the time of termination of pregnancy of a female with insulin dependent diabetes?
a. 34 weeks b. 37 weeks
c. 38 weeks d. 40 weeks

153. Active management of third stage of labor includes all except:
a. Uterine massage b. Cord traction
c. Oxytocin infusion
d. Ergometrine after anterior shoulder delivery

JAYPEE BROTHERS

154. Investigation of choice for vesicovaginal fistula is:
a. IVP b. Cystoscopy
c. 3 swab test d. X-ray

155. Before ovulation, development of granulosa cell is dependent on:
a. Estrogen b. Progesterone
c. FSH d. LH

156. All of the following are reversible long acting contraceptives except:
a. Copper-T
b. Laparoscopic tubal ligation
c. LNG-IUS d. Implanon

157. Possible manifestations of choriocarcinoma after hydatidiform mole is all except:
a. Rising hCG b. More theca lutein cysts
c. Increased uterus size d. Suburethral nodule

158. Young female history spontaneous abortion and secondary amenorrhea since then. FSH 6 IU/ml. What is the most probable cause of amenorrhea?
a. Ovarian failure b. Pituitary failure
c. Fresh pregnancy d. Uterine synechiae

159. Placenta grade 3, 35+3 weeks pregnancy, and absent end diastolic flow in Doppler; next management is:
a. Dexamethasone and terminate after 48 hours
b. Terminate after 37 weeks
c. Talk with pediatrician and termination
d. Monitor and do nothing

PAEDIATRICS

160. Identify the instrument:



a. Swan-Ganz catheter
b. NAVA catheter
c. Esophageal temperature probe
d. None of the above

161. A 5 years old boy has peculiar facial features, enlarged head, hepato-splenomegaly, protuberant abdomen, breathing difficulty with obstructive sleep apnea and cardiac valve thickening. What is the likely diagnosis?
a. Hurler's disease b. Hunter's disease
c. Fragile X syndrome d. Tay-Sachs disease

162. BCG is maximally protective against:
a. Pulmonary tuberculosis
b. Pulmonary and CNS tuberculosis
c. CNS and disseminated tuberculosis
d. Extrapulmonary TB

163. Maximum steroid produced by fetal adrenal:
a. DHEA-S b. Cortisol
c. Corticosterone d. Progesterone

164. Which of the following is true statement regarding Turner's syndrome?
a. Turner syndrome with webbed neck is 3 times more likely to develop CVS defects than non-webbed neck
b. Coarctation of aorta is more likely in non-webbed neck
c. Male turner (Noonan syndrome) is much more likely to have CVS defects
d. Turner syndrome with webbed fingers and toes is likely to be associated with visceral anomalies

165. Video of a child having respiratory distress with audible grunting and asked about the Silverman Anderson Score: (It is a video presented at a conference jointly held by AIIMS and PGI under The Queen Elizabeth Diamond Jubilee Trust and almost same video is available on YouTube and other resource forums.):
a. 7 b. 8
c. 9 d. 10

166. A video of sick intubated neonate having bilateral jerks of both right and upper limbs with some occasional twitching of neck as well. Likely seizures:
a. Focal clonic b. Multifocal clonic
c. Multifocal tonic clonic d. Focal tonic

ORTHOPEDICS

167. Identify the well circumscribed osteolytic lesion in an 8 years old child in the calcaneum with pigmented deposition with histopathological image:

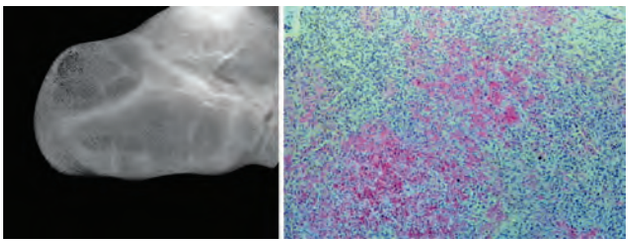

a. Ochronosis
b. Hemophilic pseudotumor
c. Pigmented villonodular synovitis
d. Eumycetes/mycetoma

168. Earliest sign of compartment syndrome of leg:
a. Skin color changes b. Loss of pulse
c. Tingling numbness
d. Pain on passive stretching of toes

169. Patellar clunk syndrome is interposition of soft tissue or hypertrophied scar at:
a. Superior pole of patella and impinging on femoral component during flexion
b. Superior pole of patella and impinging on femoral component during extension
c. Inferior pole of patella and impinging on femoral component during flexion
d. Inferior pole of patella and impinging on femoral component during extension

JAYPEE BROTHERS

for detailed information on PGMEE books, visit our website **www.jaypeebrothers.com,** for detai

AIIMS ESSENCE

Salient Features

- Authentic questions of AIIMS with exact language and options including all image-based questions
- Fully coloured, thoroughly revised, updated from 20th edition of Harrison, 27th edition of Bailey & Love, 9th edition of Robbins, 12th edition of Goodman & Gilman, 11th edition of Schwartz, 20th edition of Sabiston, 41st edition of Gray's Anatomy, 25th edition of Park, 30th edition of Harper, 25th edition of Ganong
- Thoroughly verified answers from subject specialist, faculty members of Dr Pritesh Institute and PG aspirants
- Explanations in tabulated form
- Explanations incorporating only high yielding and relevant facts
- Highlighted important, golden facts and previously asked questions
- Controversial questions and image-based questions are handled with special care to clear the concept
- Explanations from latest editions of standard and most authentic text books
- Line diagrams to minimise tedious efforts
- Mnemonics for faster learning

Students' Review

Sir I read your Surgery Essence & AIIMS Essence book. Both books are fabulous and are must for every PG Aspirant. All topics are explained very nicely in great manner, keeping it simple & yet not missing the very basics and essentials of every subject. The AIIMS Essence book is the best book for AIIMS Pattern, all subjects are comprehensively covered. Image based questions are especially taken care of, for AIIMS. Sir, would be looking for the new editions of both the books. Hats off to your both books.

—Aditya Sood, GMC Amritsar, AIR-2278, State Rank-39

Sir I have just gone through your beautiful endeavour in the form of AIIMS Essence, wonderful job sir. The most striking feature of this book is the large number of diagrammatic explanations in full details especially of Anatomy, as visual explanations are always easy to grasp and memorize. This special feature I don't think is available in any of the books in the market. Hope you will come with more beautiful editions for benefitting PG Aspirants.

—Khusru Nomani

Sir I secured Rank 288 in AIIMS. I just wanted to thank you for your book AIIMS Essence it is a very good book sir. The way you have covered the topics is just commendable. I really like the simplified manner of presentation and to the points notes of the book. I look forward to your guidance and support in future. Once again thank you for the book.

—Lovepriya Sharma

Namaste sir, I am from Nepal. I bought your AIIMS book and I personally loved the book. Answers of the book are so much concept clear.

—Prakash Khadka

Ambition is the first step towards success, the second is action. The action should be smart enough that can make you reach your goal. This book can help you achieve your dreams as the preparation is lacking if you don't know the correct answers to previous year's papers. AIIMS Essence is an attempt to provide you with the authentic questions and accurate answers with appropriate explanation of the topics asked. The confidence you gain from knowing the repeat questions will surely get you ahead in the race. The book has been updated from the most recent editions of Robbins, Harrison, Goodman & Gilman, Schwartz, Sabiston, Gray's Anatomy, Park, Harper and Ganong. The answers have been meticulously revised by the subject specialists, faculty members of Dr Pritesh Institute as well as PG aspirants. Explanations incorporate high yielding and relevant facts. Explanations are presented in tabulated form along with line diagrams and mnemonics which makes the learning efficient and interesting. While writing this book, special emphasis has been given to controversial and image-based questions as they are the ones which really make the difference. There is no secret routine, the intelligence go in drain if it is not combined with consistent hard work. Make the right choices to build a better future. All the best…



Dr Pritesh Singh
Director Dr Pritesh Institute
MBBS (MAMC), MS (Surgery)
FMAS, FIAGES

Dr Pritesh Singh, graduate from Maulana Azad Medical College and postgraduate from Lady Hardinge Medical College, New Delhi, India, is an excellent teacher and has been taking awe inspiring classes in various countries since 2009. He is amongst the best faculty and is very popular with students because of his spellbinding classes. He is a renowned educationist and author of SURGERY ESSENCE, which needs no introduction and AIIMS ESSENCE and DPG entrance examination books. The students all over the country admire the way he teaches. He is not just a source of inspiration for his pupils rather he is their role model, as he is young and dynamic. He sets a positive example with his style of teaching, courtesy, cooperation and professionalism. Some students say he is a magician who keeps his students spellbound throughout his class. His performance speaks volumes about his knowledge and precision.

Available at all medical bookstores
or buy online at www.jaypeebrothers.com

JAYPEE BROTHERS
Medical Publishers (P) Ltd.
www.jaypeebrothers.com
Join us on facebook.com/JaypeeMedicalPublishers

ISBN 978-93-89776-52-2
9 789389 776522