

63rd All India Congress of Obstetrics and Gynaecology

29th Jan - 2nd Feb 2020

Smriti Upvan, Lucknow

We Pledge for Women's Health

Manual of

Imaging in Obstetrics and Gynecology

Visualizing the Inner Problem

Editors

Narendra Malhotra
PK Shah
Archana Baser

Co-Editors

PK Srivastava
Seema Mehrotra

Celebrating 50 Years
Passion, Quality and Innovation in Healthcare Publishing
JAYPEE

Contents

1. **First-trimester Ultrasound 1**
   Prachi Singh

2. **Liquor Assessment.....12**
   PK Srivastava, Seema Mehrotra

3. **Placental Imaging: Newer Classification.....18**
   (Col) Madhusudan Dey, (Col) Sanjay Singh, (Lt Col) Abhijeet Kumar

4. **Growth Scan with Application of Percentile Charts.....26**
   Latika Chawla

5. **Growth Scan with Application of Percentile Charts and Doppler in Third Trimester.....31**
   Chander Lulla, Pooja Vyas

6. **Understanding Doppler Indices with Doppler in Special Situations 43**
   Deepti Verma

7. **Soft Markers 49**
   Archana Baser, Mumtaz P, Anshu Baser

8. **Screening the Fetal Heart: Basics of Fetal Echo.....58**
   Payal Saxena

9. **3D Ultrasound in Gynecology.....70**
   Narendra Malhotra, Neharika Malhotra Bora, Jaideep Malhotra

10. **Evaluation of Abnormal Uterine Bleeding: IETA Model.....86**
    TLN Praveen, P Surekha

2

CHAPTER

Liquor Assessment

PK Srivastava, Seema Mehrotra

INTRODUCTION

Amniotic fluid provides an ideal setting for the developing fetus by providing an environment that protects from trauma, provides a source of water, allows for normal fetal movements essential for anatomic development, and contributes to the development of the fetal lungs.

The amniotic fluid volume (AFV) can reflect fetal well-being, and changes in the volume may indicate maternal or fetal disease processes. Therefore, the assessment of the AFV is an essential component to the sonographic evaluation of the gravid patient.

Determination of amniotic fluid volume:

- Dye-dilution techniques utilizing amniocentesis—not practical for routine clinical use.
- Direct measured at the time of cesarean section.
- *Ultrasound techniques*: 4 techniques are described
  1. AFI (amniotic fluid index)
  2. Single deepest pocket (SDP)/Deepest vertical pocket (DVP)/Maximal vertical pocket (MVP)
  3. Two-diameter pocket
  4. Subjective assessment

As described by Phelan and associates, in order to calculate the AFI, the abdomen is divided into four quadrants in which the umbilicus divides the upper and lower halves and the linea nigra divides the right and left halves **(Fig. 1)**. With the patient supine, the linear or curvilinear transducer is placed along the maternal anterior abdominal wall and held perpendicular to the floor. The maximum vertical pocket of fluid (usually reported in centimeters) is measured in each of the four quadrants, and the AFI (in centimeters) equals the sum of these four measurements.

The DVP is simply the largest single vertical pocket of fluid that is at least 1 cm in width, obtained following the same criteria described above **(Fig. 2)**.

Traditionally, pockets filled with umbilical cord have not been used in measurement of the AFV.

JAYPEE BROTHERS

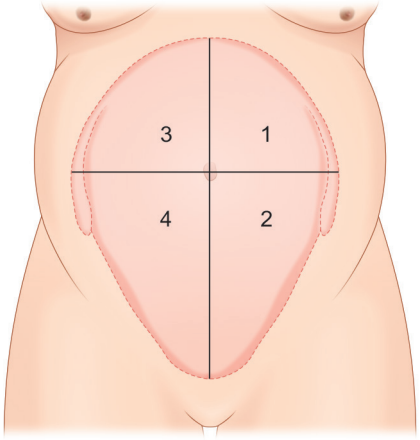

Fig. 1: Division of the uterus into 4 equal quadrants for amniotic fluid evaluation.

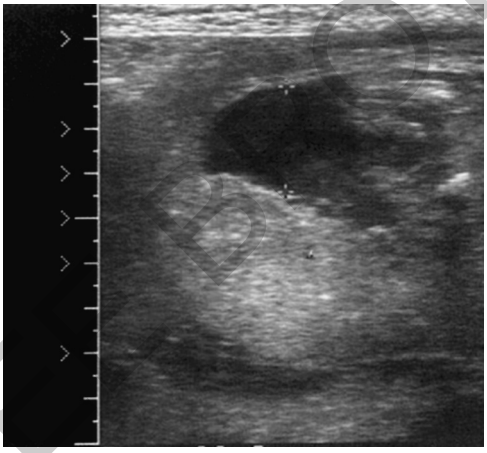

Fig. 2: Measurement of single largest pocket.

The two-diameter pocket measurement (horizontal and vertical dimensions of the maximum vertical pocket are multiplied together to obtain a single value, in cm^2) was shown to not be a better predictor of AFV than the AFI and is no longer widely used.

POTENTIAL DIFFICULTIES IN AMNIOTIC FLUID VOLUME ESTIMATION USING ULTRASOUND

- Maternal positioning, whether supine or at a 45° semi-erect position, does not appear to influence the measurement of the AFV.
- Fetal positioning can influence the calculation of the AFI, although it does not appear to influence the DVP measurement.[1]

JAYPEE BROTHERS



Fig. 3: USG of obese women showing artifactual echoes in amniotic fluid.

- Fetal movements do not appear to alter the assessment of AFV, nor does the choice of the transducer.
- Excessive pressure with the transducer while scanning can negatively influence the estimation of AFV resulted in a 21% decrease in calculated AFI measurement.[2]
- Maternal obesity may result in artificial echoes suggested within pockets of amniotic fluid. Thus, obese women may appear to have reduced volume of amniotic fluid as a result of these artefactual echoes **(Fig. 3)**. It may help to use a lower frequency transducer when assessing the AFV in these patients.
- Also, measurements of amniotic fluid pockets may be made in varying locations by different examiners; this too can lead to variation in estimates of AFV.

ASSESSMENT OF AMNIOTIC FLUID VOLUME IN THE HIGH-RISK PATIENT

Frequency of AFV measurement:[3,4]

- For patients at less than 41 weeks of gestation undergoing antepartum testing, weekly assessment of AFI is probably adequate if the initial measurements in the normal range (≥8 cm) because the risk of developing oligohydramnios within 4 days is only 1.7% and within 7 days only 2.2%.
- For patients at less than 41 weeks of gestation whose initial AFI measurement is in the low-normal range (5–8 cm), twice-weekly assessment is justified on the basis of a higher risk for an AFI 5 cm or less within 4 days (12.3%).
- For all patients at 41 or more weeks of gestation, twice-weekly AFI assessments are recommended regardless of the initial measurement.

JAYPEE BROTHERS

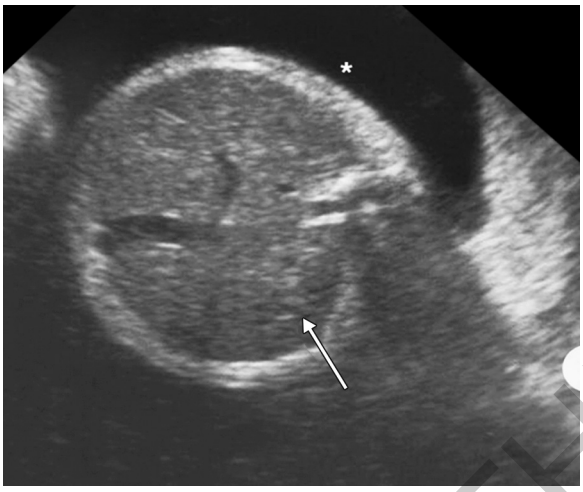

Fig. 4: Sonogram of a patient with esophageal atresia and polyhydramnios showing absence of the fetal stomach (arrow) and increased amniotic fluid (asterisk).

- These evaluations were done using AFI calculations, and no similar data are available using DVP measurements.

POLYHYDRAMNIOS

The incidence of polyhydramnios (also referred to as hydramnios) ranges from 0.2–2.0%.

- *Mild polyhydramnios:* AFI of 25–30 cm or a DVP of 8 cm or greater
- *Moderate polyhydramnios*: AFI of 30.1–35 cm or a DVP of 12 cm or greater
- *Severe polyhydramnios*: AFI of 35.1 cm or greater or a DVP of 16 cm or greater

Causes

- Idiopathic polyhydramnios—50–60% of cases
- Congenital anomalies and genetic disorders (8–45%)
- Maternal diabetes (5–26%)
- Multiple gestations (8–10%)
- Fetal anemia (1–11%)
- Other (e.g., hydrops fetal is, Bartter syndrome, and congenital viral infections)

Increasing severity of polyhydramnios correlates with an increased risk of perinatal death and congenital abnormalities. The most common structural anomalies associated with polyhydramnios are central nervous system (28%), cardiac (22%), or gastrointestinal malformations (14%).

The most common aneuploidies associated with polyhydramnios are trisomy 21, trisomy 18, and trisomy 13.

JAYPEE BROTHERS

Difficulties in Sonographic Evaluation of Polyhydramnios

- Excessive fetal movement, due to the large amount of intrauterine fluid, may make it very difficult to obtain the necessary images.
- The fetus may be positioned deep within the uterus and thus far from the maternal anterior abdominal wall and far from the transducer.
- The uterus expands because of increasing fluid volume, the placental thickness may appear to decrease. Thus, an abnormally thickened placenta (e.g., related to fetal hydrops) may measure within normal limits.

FETAL GROWTH RESTRICTION AND AMNIOTIC FLUID VOLUME

In case of fetal growth restriction (FGR) due to uteroplacental insufficiency, it is hypothesized that hypoxemia leads to decreased perfusion of the fetal kidneys, due to shunting of fetal blood flow to the brain, heart, and adrenal glands, thus resulting in decreased urine output and oligohydramnios. It has been shown that when oligohydramnios is present in the setting of FGR, the perinatal mortality rate is increased 47-fold.

The FGR complicates approximately 3– 6% of cases with polyhydramnios. The finding of polyhydramnios with FGR has been referred to as an "ominous combination" and raises high suspicion for underlying major fetal anomalies, chromosomal abnormalities, or both.

AMNIOTIC FLUID VOLUME IN TWIN PREGNANCIES

Different Techniques

- *Summated AFI technique*: This technique estimates AFV by identifying and measuring the single DVP in each of the four quadrants of the maternal abdomen [divided vertically into right and left by the linea nigra and horizontally into upper and lower by the umbilicus (the same technique used to estimate AFV in singletons)] and summing those four measurements to determine the AFI in centimeters. This calculation is done without taking membrane placement into consideration.
  Thus, this technique fails to identify many twin pregnancies complicated by discordant or abnormal AFVs.
- Identify the dividing intertwin membrane and then measured the largest pocket of amniotic fluid in each sac, both above and below the level of the fetal diaphragm (a two-quadrant measurement).
- Hill and coworkers located the dividing membrane and used the longitudinal axis of the fetus to divide each amniotic sac into right and left

JAYPEE BROTHERS

halves and the horizontal axis of the fetal diaphragm into upper and lower halves (a four-quadrant measurement).

- Magann and associates[5] identified the dividing membrane by ultrasound and measured the DVP of fluid in each of the four quadrants of the maternal abdomen as used for AFI calculation in singleton pregnancies (another two-quadrant measurement). Only this study was comparable to dye-dilution technique.
- The subjective estimation of AFV in twins (visual assessment without measurements) was found to be as accurate as objective numeric determination (with use of AFI or DVP) in correctly identifying those with normal fluid, oligohydramnios, or polyhydramnios confirmed by dye-dilution technique.

Using DVP technique, DVP of 2 cm or less is defined as oligohydramnios and greater than 8 cm is defined as polyhydramnios, with measurements in between deemed normal AFV.

CONCLUSION

Assessment of amniotic fluid is used as a vital sign for fetal wellbeing. AFV evaluation is an essential component of the BPP in antenatal testing. Abnormalities in AFV may be a reflection of the status of the uteroplacental unit. Thus, an obstetric ultrasound examination must include attention to amniotic fluid.

REFERENCES

1. Fok WY, Chan LY, Lau TK. The influence of fetal position on amniotic fluid index and single deepest pocket. Ultrasound Obstet Gynecol. 2006;28:162–5.
2. Flack NJ, Dore C, Southwell D, Kourtis P, Sepulveda W, Fisk NM. The influence of operator transducer pressure on ultrasonographic measurements of amniotic fluid volume. Am J Obstet Gynecol. 1994;171(1):218–22.
3. Wing DA, Fishman A, Gonzalez C, Paul RH. How frequently should the amniotic fluid index be performed during the course of antepartum testing? Am J Obstet Gynecol. 1996;174:33-6.
4. Lagrew DC, Pircon RA, Nageotte M, Freeman RK, Dorchester W. How frequently should the amniotic fluid index be repeated? Am J Obstet Gynecol. 1992;167:1129-33.
5. Magann EF, Chauhan SP, Martin JN, Jr, Whitworth NS, Morrison JC. Ultrasonic assessment of the amniotic fluid volume in diamniotic twins. J Soc Gynecol Investig. 1995;2(4):609–13.

JAYPEE BROTHERS

Available at all medical bookstores
or buy online at www.jaypeebrothers.com

JAYPEE BROTHERS
Medical Publishers (P) Ltd.
www.jaypeebrothers.com

Join us on facebook.com/JaypeeMedicalPublishers

Shelving Recommendation
OBSTETRICS & GYNECOLOGY

ISBN 978-93-89776-73-7