ite www.jaypeebrothers.com, for detailed information on surgery books, visit our website www.jaypeebrothers.com, for detailed information on surgery books, visit our website www.jaypeebrothers.com

diginerve
A Jaypee Initiative
Your Guide at Every Step
Video Lectures | Notes | Self-Assessment
Scan code to check out courses

Access the Videos by Scanning the QR Code Inside

Textbook of Laparoscopy *for* Surgeons and Gynecologists

(Previously known as Textbook of Practical Laparoscopic Surgery)



FOURTH EDITION

RK Mishra

Foreword
Steven D Wexner

JAYPEE

Contents

SECTION 1 ♦ Essentials of Laparoscopy

1. Chronological Advances in Minimal Access Surgery 3
2. Laparoscopic Imaging Systems 9
3. Laparoscopic Equipment and Instruments 34
4. Sterilization of Laparoscopic Instruments 57
5. Anesthesia in Laparoscopic Surgery 63
6. Abdominal Access Techniques 75
7. Principles of Laparoscopic Port Position 99
8. Laparoscopic Dissection Techniques 109
9. Laparoscopic Tissue Approximation Techniques 127
10. Hand-assisted Laparoscopic Surgery 149
11. Tissue Retrieval Technique 157
12. Laparoscopic Port Closure Technique 165

SECTION 2 ♦ Laparoscopic General Surgical Procedures

13. Laparoscopic Cholecystectomy 177
14. Laparoscopic CBD Exploration 198
15. Laparoscopic Appendicectomy 208
16. Laparoscopic Repair of Inguinal Hernia 219
17. Laparoscopic Repair of Ventral Hernia 239
18. Laparoscopic Repair of Hiatus Hernia 255
19. Laparoscopic Repair of Duodenal Perforation 263
20. Laparoscopic Fundoplication 269
21. Laparoscopic Bariatric Surgery 283

JAYPEE BROTHERS

22. Laparoscopic Splenectomy 302
23. Laparoscopic Management of Hepaticopancreatic Diseases 310
24. Diagnostic Laparoscopy 322
25. Laparoscopic Small Bowel Surgery 334
26. Laparoscopic Colorectal Surgery 340
27. Laparoscopic Adhesiolysis 376

SECTION 3 ♦ Laparoscopic Gynecological Procedures

28. Laparoscopic Sterilization 385
29. Laparoscopic Ovarian Surgery 392
30. Laparoscopic Tubal Surgery 403
31. Laparoscopic Management of Ectopic Pregnancy 411
32. Laparoscopic Surgery in Pregnancy: Precautions and Complications 417
33. Laparoscopic Management of Endometriosis 423
34. Laparoscopic Hysterectomy 430
35. Laparoscopic Myomectomy 445
36. Laparoscopic Management of Stress Incontinence 453
37. Minimally Invasive Sling Operation for Stress Incontinence 459
38. Laparoscopic Repair of Pelvic Organ Prolapse 470
39. Essentials of Hysteroscopy 481

SECTION 4 ♦ Laparoscopic Urology

40. Ureteral Injury and Laparoscopy 495
41. Laparoscopic Urological Procedures 509

SECTION 5 ♦ Pediatric Laparoscopy

42. Laparoscopic Pediatric Surgery 519

JAYPEE BROTHERS

SECTION 6 ♦ Miscellaneous

43. Other Minimal Access Surgical Procedures 533
44. Minimal Access Bariatric Surgery 556
45. Complications of Minimal Access Surgery 564
46. Role of Training in Minimal Access Surgery 582
47. Minimal Access Robotic Surgery 591
48. Transanal Endoscopic Microsurgery 618
49. Future of Minimal Access Surgery 625
50. Troubleshooting and Checklist 629

Index *637*

JAYPEE BROTHERS

CHAPTER 16

Laparoscopic Repair of Inguinal Hernia

INTRODUCTION

Inguinal hernia results from a hole or defect in the muscles, through which the peritoneum protrudes, forming the sac **(Figs. 1 to 5)**. Inguinal herniorrhaphy is one of the most common operations that general surgeons perform. Minimally invasive surgical approaches are increasingly popular because they offer the potential for less postoperative pain and a quick return to normal activities. Laparoscopic herniorrhaphy is being done at a time when laparoscopic cholecystectomy has shown definite benefits over the open technique. Laparoscopic repair of inguinal and femoral hernia is no exception, with laparoscopic approach. The laparoscopic approach to inguinal hernia repair is theoretically possible in nearly all inguinal hernias. However, the precise role of laparoscopy in inguinal hernia repair remains somewhat controversial given the increased costs and greater technical demands.

Ger in 1982 attempted minimal access groin hernia repair by closing the opening of an indirect inguinal hernial sac using Michel clips. Bogojavlensky in 1989 modified the technique by intracorporeal suture of the deep ring after plugging a polypropylene mesh (PPM) into the sac. Toy and Smoot in 1991 described a technique of intraperitoneal onlay mesh (IPOM) placement, where an intra-abdominal piece of polypropylene or expanded polytetrafluoroethylene (e-PTFE) was stapled over the myopectineal orifice without dissection of the peritoneum.



Fig. 1: Bilateral direct hernia.

The present day techniques of laparoscopic hernia repair evolved from Stoppa concept of preperitoneal reinforcement of fascia transversalis over the myopectineal orifice with its multiple openings by a prosthetic mesh. In the early 1990s, Arregui and Doin described the transabdominal preperitoneal (TAPP) repair, where the abdominal cavity is first entered, peritoneum over the posterior wall of the inguinal canal is incised to enter into the avascular preperitoneal plane which is adequately dissected to place a large (15 × 10 cm) mesh over the hernial orifices. After fixation of the mesh, the peritoneum is carefully sutured or stapled. TAPP approach has the advantage of identifying missed additional direct or femoral hernia during the first operation itself.

Around the same time, Phillips and McKernan described the totally extraperitoneal (TEP) technique of endoscopic hernioplasty where the peritoneal cavity is not breached and the entire dissection is performed bluntly in the extraperitoneal space with a balloon device or the tip of the laparoscope itself. An advanced knowledge of the posterior anatomy of the inguinal region is imperative. Once the dissection is complete, a 15 × 10 cm mesh is stapled in place over the myopectineal orifice. It appears to be the most common endoscopic repair today.

In both these repairs, the mesh in direct contact with the fascia of the transversalis muscle in the preperitoneal space, allows tissue in growths leading to the fixation of the mesh as opposed to being in contact to the peritoneum as in IPOM repair where it is prone to migrate.

TOTALLY EXTRAPERITONEAL REPAIR

Totally extraperitoneal repair is performed in the preperitoneal space and was developed to avoid the risks associated with entering the peritoneal cavity **(Fig. 2A)**. The surgeon develops a space between the peritoneum and the anterior abdominal wall so that the peritoneum is never violated. In experienced hands and smaller direct hernia, this approach has the advantage of eliminating the risk of intra-abdominal adhesion formation.

JAYPEE BROTHERS

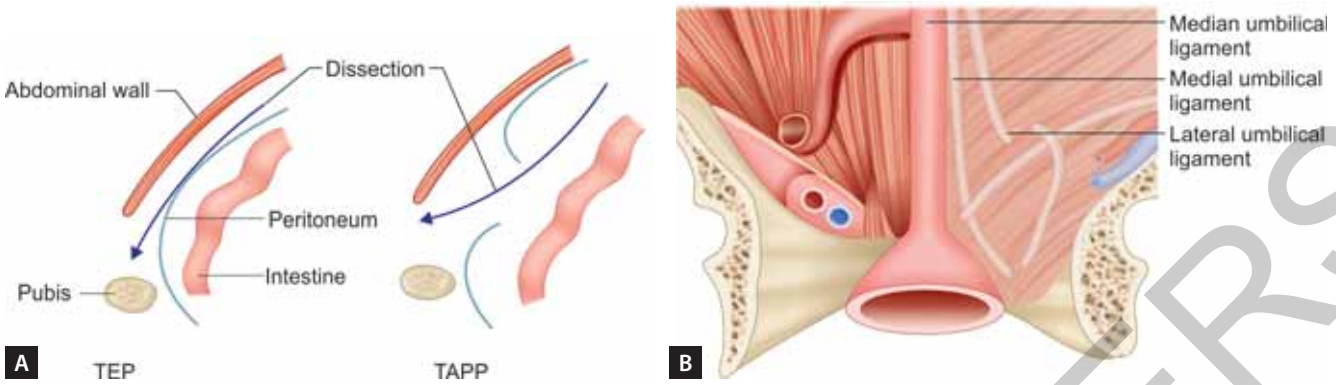

Figs. 2A and B: (A) Totally extraperitoneal (TEP) versus transabdominal preperitoneal (TAPP) hernia repair; (B) Diagrammatic representation of ligaments.

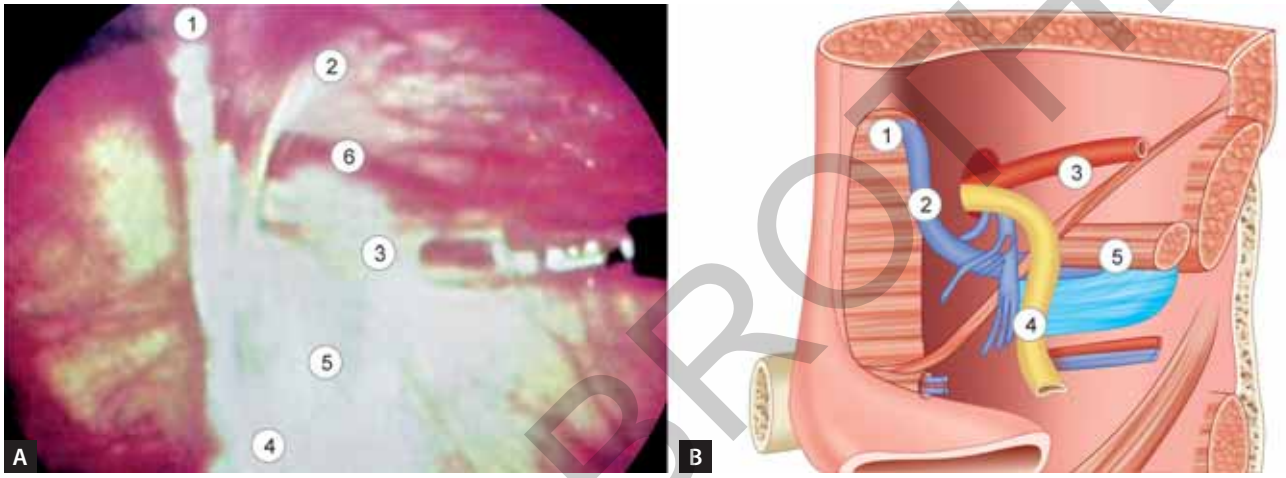

Figs. 3A and B: Important landmarks in laparoscopic hernia repair: (1) Medial umbilical ligament; (2) Inferior epigastric vessels; (3) Spermatic vessels; (4) Vas deferens; (5) External iliac vessels in "triangle of doom"; (6) Indirect defect.



Fig. 4: Left side indirect hernia.

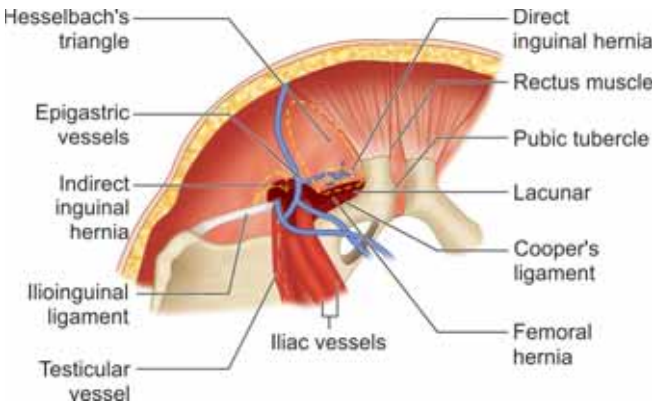

Fig. 5: Triangle of doom.

TRANSABDOMINAL PREPERITONEAL REPAIR

Transabdominal preperitoneal repair involves the placement of mesh in a preperitoneal position, but peritoneal incision is given after entering in abdominal cavity, which is covered by peritoneum to keep the mesh away from the bowel **(Fig. 2A)**. Because TAPP is performed transabdominally, it has a larger working space than TEP, with ready access to both groins, and can be attempted in patients with prior lower abdominal surgery. However, TAPP rarely results in injuries to adjacent intra-abdominal organs, adhesions resulting in intestinal obstruction, or bowel herniation.

JAYPEE BROTHERS

For patients in whom the TEP technique is not appropriate or fails due to inability to develop the preperitoneal space, conversion to a TAPP approach can be performed. On occasion, conversion to an open surgical approach may be necessary. Larger hernias, especially huge scrotal hernias, are probably best repaired open. In female patients with indirect inguinal hernia, a TAPP approach may be easier. Indirect inguinal hernia sacs are frequently much more intimately attached to the round ligament in women than are indirect sacs to the cord structures in males.

LAPAROSCOPIC ANATOMY

A clear understanding of the anatomy of the groin and its anatomic approaches is important for successful laparoscopic hernia repair. In the lower abdomen, there are five peritoneal folds or ligaments which are seen through the laparoscope in umbilicus. These ligaments are generally overlooked at the time of open surgery.

One Median Umbilical Ligament

In the midline, there is median umbilical ligament which extends from the mid of urinary bladder up to the umbilicus. Median umbilical ligament is obliterated urachus **(Fig. 2B)**.

Two Medial Umbilical Ligament One on Either Side

The paired medial umbilical ligament is obliterated umbilical artery except where the superior vesical arteries are found in the pelvic portion. The medial umbilical ligaments are the most prominent fold of the peritoneum. Sometimes, it hangs down and obscures the vision of lateral pelvic wall. These ligaments are important landmarks for the lateral extent of the urinary bladder **(Figs. 3A and B)**.

Two Lateral Umbilical Ligaments

Lateral to the medial umbilical ligament, the less prominent paired lateral umbilical fold contains the inferior epigastric vessels. The inferior epigastric artery is lateral border of Hesselbach's triangle and hence is a useful landmark for differentiating between direct and indirect hernia. Any defect lateral to the lateral umbilical ligament is in direct hernia and medial to it is direct inguinal hernia **(Fig. 4)**.

The femoral hernia is below and slightly medial to the lateral inguinal fossa, separated from it by the medial end of the iliopubic tract internally and the inguinal ligament externally.

Important landmarks for extraperitoneal hernia dissection include the musculoaponeurotic layers of the abdominal wall, the bladder, Cooper's ligament, and the iliopubic tract. The inferior epigastric artery and vein, the gonadal vessels, and vas deferens should also be recognized. The space of Retzius lies between the vesicoumbilical fascia posteriorly and the posterior rectus sheath and pubic bone anteriorly. This is the space first entered in extraperitoneal repair of hernia.

Three dangerous areas where stapling and electrosurgery should be avoided are described below.

Triangle of Doom (Fig. 5)

The triangle of doom is defined by vas deferens medially, spermatic vessels laterally, and external iliac vessels inferiorly. This triangle contains external iliac artery and vessels, the deep circumflex iliac vein, the genital branch of genitofemoral nerve, and, hidden by fascia, the femoral nerve. Staple should not be applied in this triangle otherwise chances of mortality are there if these great vessels are injured.

Triangle of Pain

Triangle of pain is defined as spermatic vessel medially, the iliopubic tract laterally, and inferiorly the inferior edge of skin incision. This triangle contains lateral femoral cutaneous nerve and anterior femoral cutaneous nerve of thigh. The staple in this area should be less because nerve entrapment can cause neuralgia.

Circle of Death

This is also called as corona mortis and refers to vascular ring form by the anastomosis of an aberrant obturator artery with the normal obturator artery arising from a branch of the internal iliac artery. At the time of laparoscopic hernia if this vessel is torn, both ends of vessel can bleed profusely, because both arise from a major artery.

The surgeon should remember these anatomic landmarks and the point of mesh fixation should be selected superiorly, laterally, and medially.

INDICATIONS OF LAPAROSCOPIC REPAIR OF HERNIA

The indications for performing a laparoscopic hernia repair are essentially the same as repairing the hernia conventionally. There are, however, certain situations where laparoscopic hernia repair may offer definite benefit over conventional surgery to the patients. These include:

- Bilateral inguinal hernias
- Recurrent inguinal hernias

In recurrent hernia, surgery failure rate is as high as 25–30%, if again repaired by open surgery. The distorted anatomy after repeated surgery makes it more prone to recurrence and other complications such as ischemic orchitis. In recurrent hernia, the laparoscopic approach offers repair through the inner healthy tissues with clear anatomical planes and thus, a lower failure rate. In laparoscopic bilateral repair with three ports technique, there is simultaneous

JAYPEE BROTHERS

access to both sides without any additional trocar placement. Even in patients with clinically unilateral defect after entering inside the abdominal cavity, there is 20–50% incidence of a contralateral asymptomatic hernia being found which can be repaired, simultaneously, without any additional morbidity of the patient.

CONTRAINDICATIONS OF LAPAROSCOPIC REPAIR OF HERNIA

- Nonreducible, incarcerated inguinal hernia
- Prior laparoscopic herniorrhaphy
- Massive scrotal hernia
- Prior pelvic lymph node resection
- Prior groin irradiation
- Inability to tolerate general anesthesia (GA)
- Prior pelvic surgery in the preperitoneal space
- Incarcerated inguinal hernia
- Large scrotal hernia
- Ascites
- Active infection

ADVANTAGES OF LAPAROSCOPIC APPROACH

- Tension-free repair that reinforces the entire myopectineal orifice
- Less tissue dissection and disruption of tissue planes
- Three ports are adequate for all type of hernias.
- Less pain postoperatively
- Low intraoperatively and postoperative complications
- Early return to work

DISADVANTAGES OF OPEN METHOD

- Requires 4–6 inches of incision at the groin
- Generally very painful, because of muscle spasm
- Considerable postoperative swelling of tissues in groin, around the wound
- Requires cutting through the skin, fat, and good muscles in order to gain access for repair, which in itself causes damage
- Frequent complications of wound hematomas, wound infection, scrotal hematomas, and neuroma
- Usually takes 6–8 weeks for recovery.
- Sometimes long-term disability may follow, e.g., neuralgia, neuroma, and testicular ischemia.
- Whether a flat mesh or a plug is used from the front, they do not hold themselves in place; what holds them in place are stitches, so the strength of the repair still depends on the stitches, not so much on the mesh or plug.
- Bilateral inguinal hernias require two incisions, doubling the pain; or two operations.
- Recurrent inguinal hernias are very difficult to operate open, and more liable to complications.
- The size of mesh used in open methods is limited by natural fusion of muscles.
- All meshes and plugs shrink with time, and this works against all open methods.

Any method of repair must achieve two fundamental goals—removal of the sac from the defect and durable closure of the defect. In addition, the ideal method should achieve these with the least invasion, pain, or disturbance of normal anatomy. Laparoscopic repair in expert hands is now quite safe and effective, and is an excellent alternative for patients with inguinal hernia. It is confusing that laparoscopic repair is more complex and is not widely available. The public needs to be educated as to its advantages. All surgeons agree that for bilateral or recurrent inguinal hernias, laparoscopic repair is unquestionably the method of choice. The argument against its use for unilateral or primary inguinal hernias is unfounded if it is the best for bilateral or recurrent hernias.

TYPES OF LAPAROSCOPIC HERNIA REPAIR

Many techniques were used to repair hernia such as:

- Simple closure of the internal rings
- Plug and patch repair
- IPOM repair
- TAPP mesh repair
- TEP repair

The technique of TAPP repair was first described by Arregui in 1991. In the TAPP repair, the peritoneal cavity is entered, the peritoneum is dissected from the myopectineal orifice, mesh prosthesis is secured, and the peritoneal defect is closed. This technique has been criticized for exposing intra-abdominal organs to potential complications, including small bowel injury and obstruction.

The TEP repair maintains peritoneal integrity, theoretically eliminating these risks while allowing direct visualization of the groin anatomy, which is critical for a successful repair. The TEP hernioplasty follows the basic principles of the open preperitoneal giant mesh repair, as first described by Stoppa in 1975 for the repair of bilateral hernias.

Both approaches (TAP or TEP) are acceptable, and one approach may be preferred over the other under specific clinical circumstances. TAPP was the original approach, and TEP evolved to minimize some of the problems associated with TAPP, but TEP repair is technically more challenging because of the limited working space, which may explain higher conversion rates. TAPP approach is more popular and commonly used procedure all over the world for inguinal hernia repair. Although surgeons should learn both techniques, they should use the technique with which they are most familiar.

JAYPEE BROTHERS

Patient Selection

The GA and the pneumoperitoneum required as part of the laparoscopic procedure do increase the risk in certain groups of patients. Most surgeons would not recommend laparoscopic hernia repair in those with pre-existing disease conditions. Patients with cardiac diseases and chronic obstructive pulmonary disease (COPD) should not be considered good candidates for laparoscopy. The laparoscopic hernia repair may also be more difficult in patients who have had previous lower abdominal surgery. The elderly may also be at increased risk for complications with GA combined with pneumoperitoneum.

If the patient is young or the hernia is small, it does not matter how the hernia is repaired. Many surgeons agree that for bilateral or recurrent inguinal hernias, laparoscopic repair is unquestionably the method of choice.

Laparoscopic surgery is not recommended for big irreducible and incarcerated hernia. Hernia repair like many other laparoscopic procedures should not be performed under local anesthesia. Small direct hernia can be performed under spinal anesthesia if TEP is planned, but best anesthesia for laparoscopic hernia repair is GA.

TRANSABDOMINAL PREPERITONEAL REPAIR OF INGUINAL HERNIA

As with most laparoscopic procedures, the peritoneal cavity is entered during TAPP hernia repair. The major advantage of the TAPP approach to groin hernias is that all three hernia defects (direct, indirect, and femoral) are well visualized and in close proximity to each other, allowing easy repair of any type of groin hernia.

Position of Surgical Team and Patient

Surgeon stands toward the opposite side of the hernia, near the shoulder. Camera assistant should stand either right to the patient or on the opposite side of the patient **(Fig. 6)**. The patient is usually placed in 15–20° of Trendelenburg position to improve exposure of the hernia defect, which is particularly important with TAPP hernia repair to move the small bowel or omentum away from the area of dissection.

Port Position

The position of port in a laparoscopic repair of transabdominal hernia repair should be again according to baseball diamond concept **(Figs. 7A to C)**. Please refer Chapter 6: Abdominal Access Techniques.

The telescopic port should be in umbilicus. A 30° telescope is a better choice for laparoscopic hernia surgery. A 10 mm umbilical port is used. Two other ports, usually 10 mm for dominant hand and 5 mm for nondominant hand, are placed lateral to the umbilicus **(Figs. 8A to C)**. In a left-sided hernia, the right lateral port should be in right iliac fossa and left port in left hypochondrium so that both the instruments should make a manipulation angle of 60°. In right-sided hernia surgery, right port should move up toward hypochondrium and left port will come down to make the triangle.

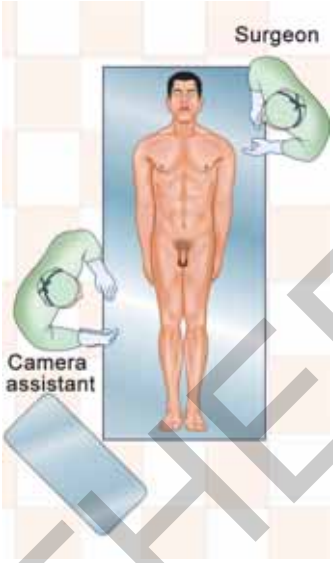

Fig. 6: Position of surgeon in right-sided hernia.

PROCEDURE OF TRANSABDOMINAL PREPERITONEAL REPAIR

After access, diagnostic laparoscopy is performed to rule out any adhesion or other intra-abdominal lesion. All the important anatomical landmarks of hernia surgery are identified with the help of telescope and one atraumatic grasper. The important landmarks of laparoscopic hernia repair are the pubic bone and inferior epigastric vessels. The defect should be seen carefully and if any content is present inside the sac, it should be reduced gently **(Figs. 9A to D)**. A sliding hernia of colon should be carefully reduced because chances of perforation of large bowel are more than other viscus so the assistant should reduce the hernia by pressing it from outside. Any adhesion between bowel and omentum should be divided carefully using harmonic scalpel or bipolar and scissors.

The next step of TAPP repair of hernia is the creation of preperitoneal space. Many surgeons like to do hydrodissection to create this preperitoneal space just by injecting normal saline into preperitoneal space. Some surgeons think that it is easy to create preperitoneal space with sharp dissection as well. The peritoneum is cut at a distance of minimum 4 cm lateral to the outer margin of deep ring at 2 o'clock position if the hernia is right side and 10 o'clock position for the left side of hernia. Medial dissection of peritoneal incision should continue up to medial umbilical ligament **(Figs. 9E and F)**. Going medial to medial umbilical ligament is risky because there is risk of injury of the urinary bladder. The flap

JAYPEE BROTHERS

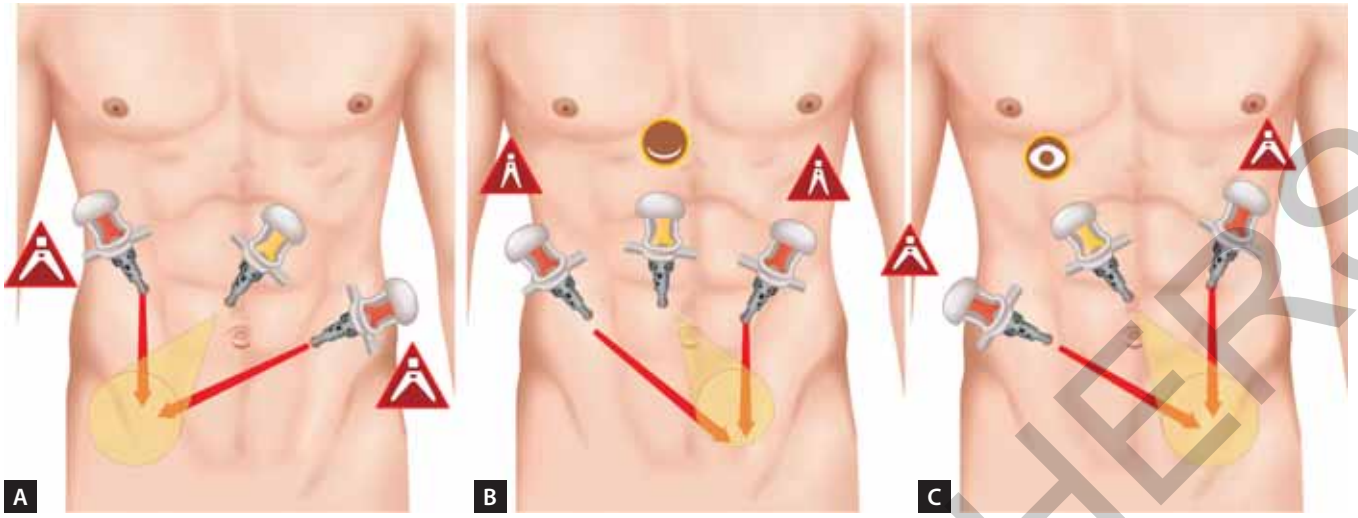

Figs. 7A to C: (A) Port position of right-sided hernia; (B) Port position of bilateral hernia; (C) Port position of left-sided hernia.



Figs. 8A to C: (A) Port position of right-sided hernia; (B) Port position of surgical team; (C) Port position right hernia (1—Camera; 2 and 3—Instruments).

of peritoneum is separated from above downward as soon as it reaches the site of internal ring, the hernia sac will be encountered.

Dissection should be started with opening the peritoneum lateral to the medial umbilical fold in order to identify Cooper's ligament. Stoppa's parietalization technique should be used for dissection of the spermatic cord from the peritoneum by separating the elements of the spermatic cord from the peritoneum and peritoneal sac **(Figs. 10A to E)**.

In case of indirect defect, the hernial sac has to be either gently dissected free or inverted or else if it is completely adhered with the transversalis fascia and cord structures, it can be transected. Surgeons should use both blunt and sharp dissection and the sac is dissected off the anterior abdominal wall. After being reduced partially, it is ligated using an endoloop and then transected with scissors. In case of bilateral hernias, the procedure is repeated on the other side. The vas and spermatic vessels also need to be separated from the sac. The next step is separation of the sac from cord structures and dissection for creation of proper lateral space for the placement of mesh. Lateral limit of dissection is the anterosuperior iliac spine, while inferior limit laterally is the psoas muscle. Dissection should be avoided in the "triangle of doom" which is bounded medially by the vas deferens and laterally by the gonadal vessels. A large hernial sac creates multiple planes and it is easy for the beginners to get disoriented with sac, vas, and vessel. The best way to avoid this confusion is that surgeon should keep himself as close as possible to the outer surface of peritoneum. If the spermatic vessels are injured accidentally, it can be clipped. Even if the testicular vessel is injured, the testes will get the blood supply from collateral vessels developed through cremasteric vessels.

In direct hernias, the creation of preperitoneal space is comparatively easy as there is no chance of injury of spermatic vessels and vas. The bulge in the transversalis fascia may be repaired by suturing or stapling.

The tacker application and application of electrosurgery should be done very carefully in the triangle of doom, triangle of pain, and trapezoid of disaster. In case of massive complete indirect scrotal hernias, no attempt should be made to reduce the sac completely as it may increase the risk of testicular nerve injury and hematoma formation.

JAYPEE BROTHERS

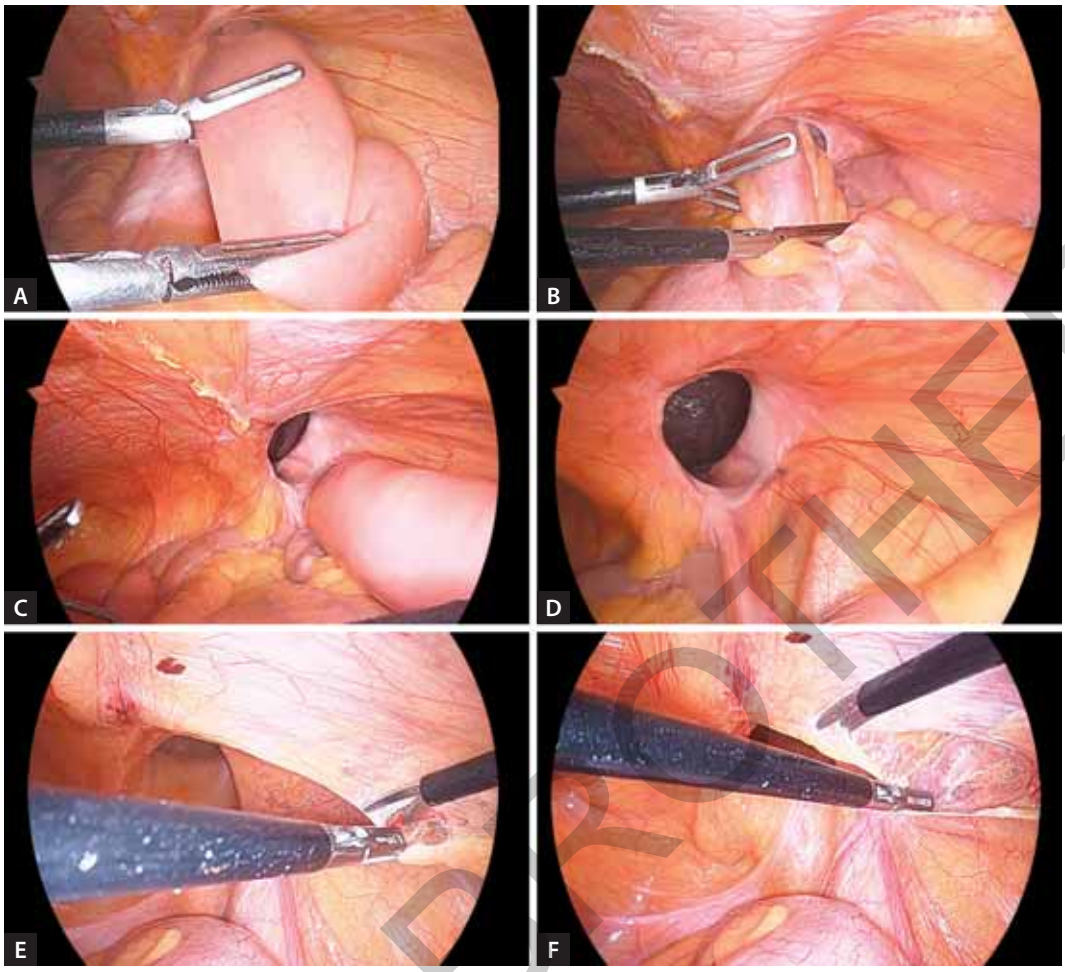

Figs. 9A to F: (A to D) Reduction of the content of hernia sac; (E and F) Incision over peritoneum.

Placement of the Mesh

Mesh is a necessary element of laparoscopic inguinal hernia repair to provide a tension-free hernia repair, which is the recommended method. Preformed mesh that conforms to the preperitoneal space is available and is preferred by some surgeons over a flat piece of mesh that needs to be trimmed to accommodate the patient's anatomy.

Criteria for laparoscopic mesh are as follows:

- Nonabsorbable
- Adequate size
- Adequate memory

Polypropylene woven mesh (e.g., Marlex, Prolene, and SurgiPro) has been used in laparoscopic inguinal hernia repair and is preferred over other prosthetic materials. e-PTFE is another material that is also used extensively for incisional hernias, but it has not been used for the laparoscopic inguinal and femoral hernia repair, except for the IPOM technique. PPM is commercially available in light, medium, or heavy weight. Light weight mesh is associated with a lower incidence of chronic groin pain, groin stiffness, and foreign body sensations without any increased risk for hernia recurrence.

A Prolene mesh of appropriate size, usually 15 × 15 cm should be taken and one corner of mesh should be tailored **(Fig. 11)**. Mesh is placed inside the abdominal cavity through 10 mm port. Mesh should be rolled and loaded backward in this port. If surgery is being performed by 10 mm port only the port should be removed and rolled mesh should be introduced though the port wound directly **(Fig. 12)**. After introduction of mesh, it is unrolled when it reaches in the peritoneal cavity. The mesh is fixed medially over the Cooper's ligament and pubic bone using a tacker or anchor **(Figs. 13A and B)**. The tailored corner of the mesh should be positioned inferomedially. No lateral slit should be made in the mesh and it should not be fixed lateral to cord structures to prevent injury to lateral cutaneous nerve of thigh. The mesh in this position covers the direct, indirect, and femoral defects. It is essential that mesh should extend below the pubic tubercle so that it covers the femoral orifice. Mesh should also extend medially to cover all the possible orifices of hernia. Laterally mesh should project at least 2–3 cm beyond the margin of deep ring. If mesh is not of appropriate size, the chances of recurrence increase. Sometimes, the surgeon may be disoriented and mesh is placed with its long axis vertical

JAYPEE BROTHERS

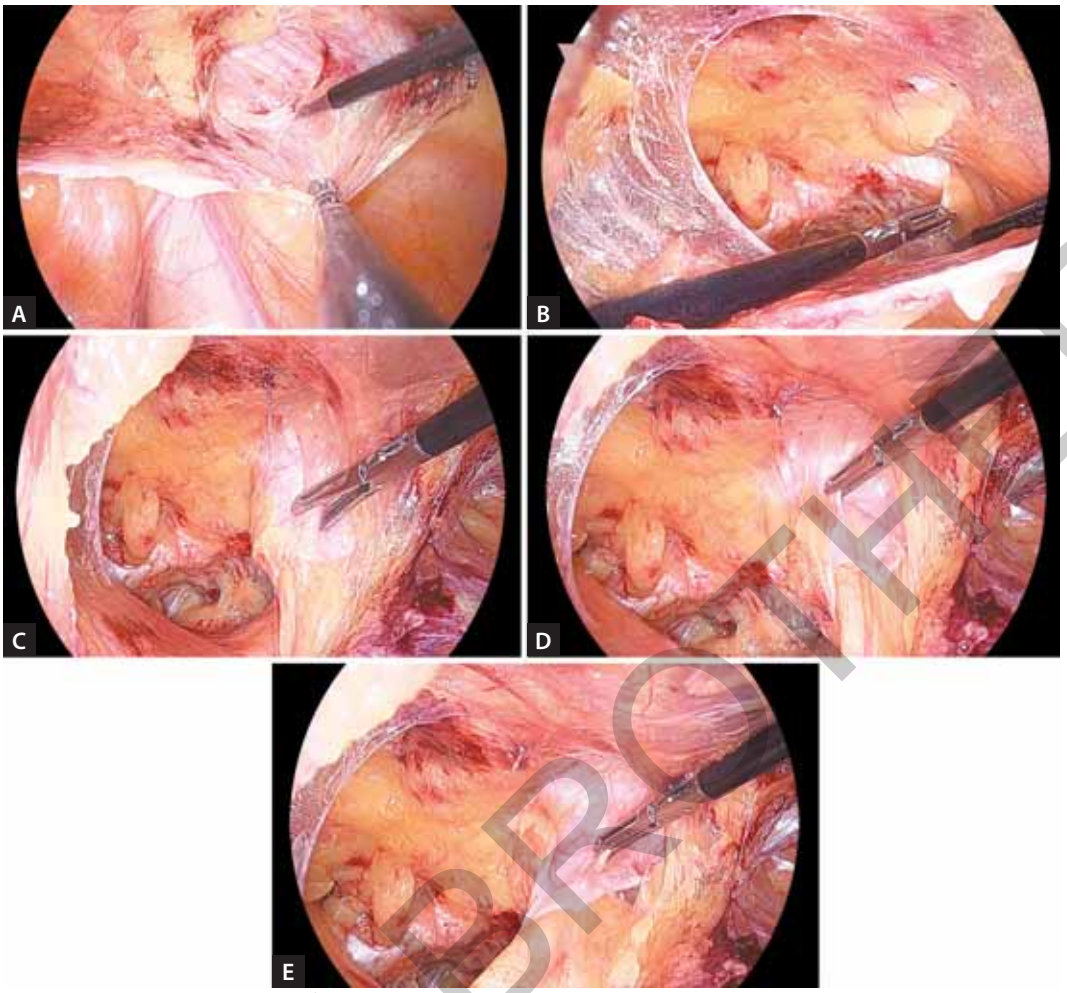

Figs. 10A to E: Creation of preperitoneal space.

instead of transverse. If the mesh is cut at one of the corners, chances of this disorientation are minimum.

Implant for Fixing Mesh

Many preloaded devices are available for fixing mesh in hernia surgery. Mesh is fixed medially over the Cooper's ligament and pubic bone using an implant.

Currently, three popular brands of implants to fix the mesh are available. These are Tacker, Protack, and Anchor. The comparative chart of these implants is shown in **Table 1**.

After adjusting the mesh properly, it should be fixed by stapling first its middle part three fingers above the superior limit of the internal ring. With mesh duly stapled, pneumoperitoneum is reduced to 9 mm Hg. It is important to avoid pricking of the inferior epigastric artery or the testicular vessels. Intracorporeal suturing can also be used for fixation of mesh if surgeon has sufficient suturing skill.

After fixing the mesh properly, the peritoneum flap is replaced over the mesh. It is important that mesh should be completely covered by the peritoneum. Ideally, peritoneum should be opposed by overlap fashion and peritoneum



Fig. 11: Cutting the corner of mesh.

defect is closed either by staples or by continuous suturing and Aberdeen termination **(Figs. 14A and B)**.

Repair of Bilateral Inguinal Hernia

In laparoscopic surgery, postoperative recovery of bilateral hernia is same as that of unilateral hernia. The technique

JAYPEE BROTHERS

of bilateral laparoscopic repair of hernia is same as that of unilateral hernia. Patients with bilateral hernia are good candidates of laparoscopy. The two sides may be repaired using two meshes, but single long mesh also can be used and is pushed across from one side behind the bladder, and across the inguinal orifice on the opposite side. The size of the mesh for bilateral hernia should be 30 × 15 cm **(Fig. 15)**. Surgeon should avoid twisting of the mesh. After placing the mesh in bilateral hernia surgery, it should look just like a bow tie.

Repair of Recurrent Inguinal Hernia

Recurrent laparoscopic hernia after open surgery is better to be repaired laparoscopically, because external anatomy is disrupted and open repair has more chances of recurrence. Laparoscopy is method of choice for recurrent hernia. The defect is usually direct and more than one in recurrent hernia.

The result of laparoscopic repair is excellent even in case of multiple hernias.

Laparoscopic Hernia in Children

Laparoscopy has been tried in small children. Only closure of ring and herniotomy is possible in pediatric age group. The sac is simply inverted and tied internally. Care should be taken that the vas or vessels should not be caught in the ligature **(Figs. 16A and B)**.

Ending of the Operation

At the end of surgery, the abdomen should be examined for any possible bowel injury or hemorrhage. The entire instrument should be removed followed by all the ports. Each port should be removed under direct observation through telescope. Ports larger than 10 mm should be sutured. Telescope should be removed at last after releasing all the gas keeping in mind that last port should not be pulled without putting telescope or any blunt instrument in, to prevent entrapment of bowel or omentum and formation of omental or intestinal adhesion. Wound should be closed with suture, especially 10 mm wound.

TOTALLY EXTRAPERITONEAL HERNIA REPAIR

The technique of TEP repair of inguinal hernia was described even before the TAPP technique; however, technical difficulties of working in closed space and anatomy with very limited working space hindered its popular acceptance. The effectiveness of this type of repair has been well established by the open operation of Stoppa.

ADVANTAGES OF TOTALLY EXTRAPERITONEAL REPAIR

- Pneumoperitoneum is not required.
- Less chance of dangerous vessel injury or bowel injury
- The view of groin is better for dissection around the neck of the sac.
- Continuity of peritoneum is not breached so it need not be closed.

DISADVANTAGES OF PREPERITONEAL REPAIR

- The identification of correct plane of dissection is difficult.



Fig. 12: Introduction of mesh in preperitoneal space.

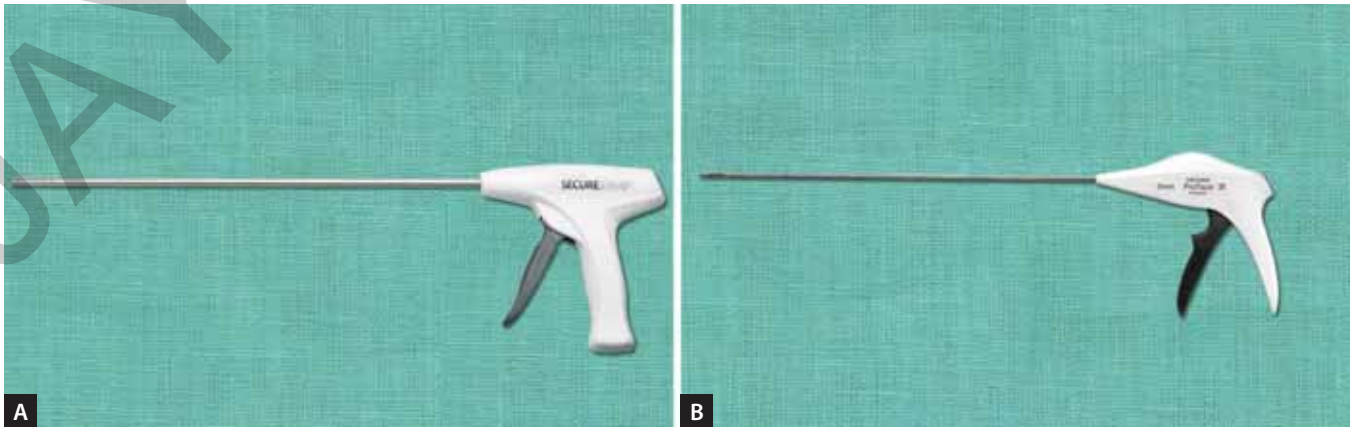

Figs. 13A and B: (A) Hernia secure trap Ethicon stapler; (B) Hernia tacker from Covidien.

JAYPEE BROTHERS

TABLE 1: Comparison of ESS Endoanchor, Tyco Protack, and Tyco Tacker.

Feature	*ESS Endoanchor*	*Tyco Protack*	*Tyco Tacker*
Number of implants	20	30	20
Geometry of implant	Anchor	Helical fastener	Helical fastener
Implant material	Nitinol	Titanium	Titanium
Implant length	5.9 mm	3.8 mm	3.6 mm
Implant width	6.7 mm	4 mm	3.4 mm
Port size required	5 mm	5 mm	5 mm
Shaft length	360 mm	356 mm	356 mm
Trigger fire orientation	Release to deploy	Depress to deploy	Depress to deploy

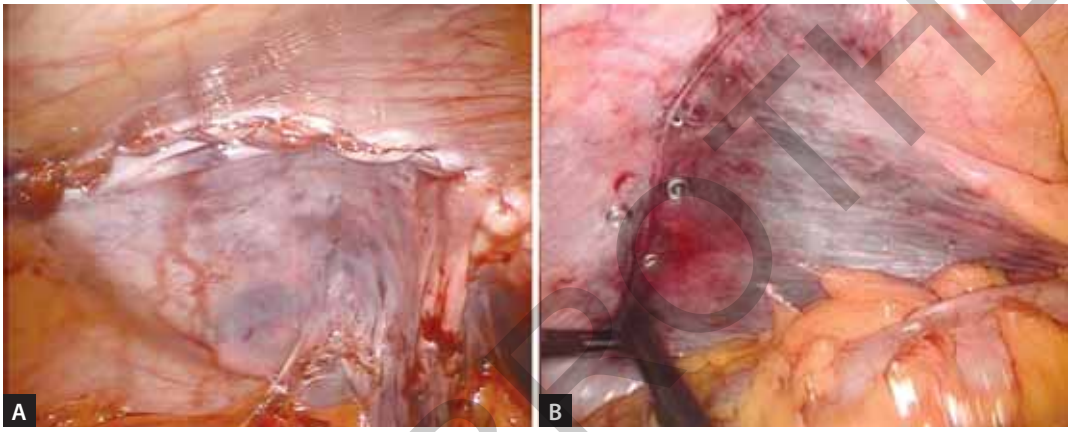

Figs. 14A and B: (A) Closure of peritoneum by suturing; (B) Closure of peritoneum by tacker.

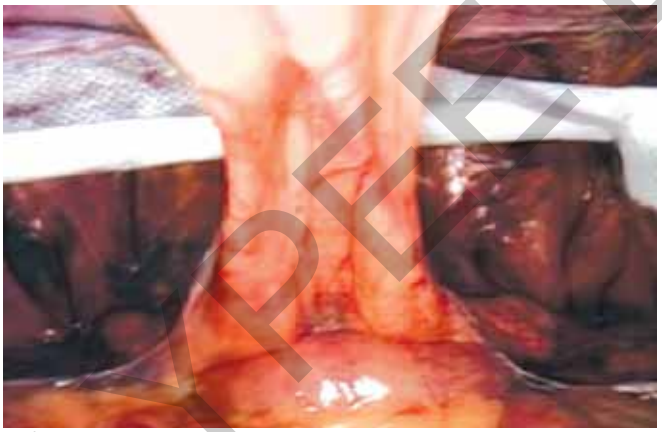

Fig. 15: Introduction of mesh for bilateral hernia.

- The landmarks of hernia dissection can only be identified when they are encountered.
- Reduction of content of sac is difficult to ensure.
- Sliding hernia is difficult to recognize from outside of the sac.
- If the sac gets accidentally cut, it is difficult to close it again.
- In recurrent hernia, extensive adhesion makes the dissection difficult because peritoneum may be adherent to the under surface of the scar.
- There is always a chance of breach of peritoneum continuity and this will reduce the view.
- Four ports generally are necessary for bilateral hernia surgery. Whereas, in TAPP only three ports are sufficient.

Preparation of the Patient

Preparation of the patient in totally preperitoneal hernia repair is same as of the transabdominal hernia repair. Knowledge of the anatomy of the abdominal wall muscle and recognition of the transition zone that occur at the arcuate line of Douglas is very important for totally preperitoneal hernia repair.

Approach to Preperitoneal Space

In TEP repair of hernia, the main concern is to make an extraperitoneal space. The extraperitoneal space is made possible by the fact that the peritoneum in suprapubic region can easily be separated from anterior abdominal wall, thereby creating enough space for dissection.

A 2 cm longitudinal skin incision is made just below the umbilicus 1 cm lateral to the midline on the side of hernia **(Figs. 17A and B)**. The incision is deepened down to reach up to the anterior rectus sheath. All the subcutaneous fat is cleared and the rectus is opened under direct vision. Two-stay

JAYPEE BROTHERS

for detailed information on surgery books, visit our website www.jaypeebrothers.com, for detailed information on surgery books, visit our website www.jaypeebrothers.com, for detailed information on s

Textbook of Laparoscopy *for* Surgeons and Gynecologists

Salient Features

- A unique textbook in laparoscopic surgery which deals with all essential aspects for surgeons, gynecologists, and urologists
- Specifically address topics of fundamentals of laparoscopic surgery and operative steps of each procedure in detail
- Aimed not only at the dedicated laparoscopic surgeons, but also at general surgeons, gynecologists, urologists, and surgical trainees
- Aim of each chapter is to define, sharpen and emphasize issues of surgical steps, using the available evidence
- Art and science of minimal access surgery is explained giving a true overall view as well as the recent technological advances made in this field
- Intended for those who are conversant with operative surgical and gynecological procedures. Its scope is broad and deep
- Illustrations and diagrams are provided to facilitate faster learning of minimal access surgery
- Self-sufficient book which explains the concept of ergonomics, task analysis and practical, and practical problems encountered in laparoscopic operative surgery
- An overall view of the latest instruments and techniques of their application is presented.



RK Mishra is an internationally recognized pioneer laparoscopic surgeon. He has 25 years of experience in laparoscopic surgery and 12 years of experience in performing da Vinci robotic surgeries. He is internationally renowned for his work in laparoscopic and robotic surgery and has performed over 12,000 laparoscopic and robotic surgeries. He has his internationally recognized institutes of Minimal Access Surgery in the USA, UAE, and India. He is a Professor, Scientist, and Prolific Author, who has written many books on minimal access surgery and more than 28 chapters in different international co-authored books of minimal access surgery. He has written hundreds of articles on various topics on minimal access surgery in different international journals. He is the Editor-in-Chief of the World Journal of Laparoscopic Surgery for the last 15 years. He is an active Member and Reviewer of the Member Selection Committee of the Society of American Gastrointestinal Endoscopic Surgeons (SAGES). He is one of the most experienced professors in laparoscopic and robotic surgery. He has alone trained more than 11,000 surgeons, urologists, pediatric surgeons, and gynecologists from more than 138 countries in laparoscopic surgery and more than 2,000 in da Vinci robotic surgery. He has vast experience in teaching laparoscopic and da Vinci robotic surgery. He is a Professor of Minimal Access Surgery, and his endeavor of starting a unique university program started in Ninewells Hospital and Medical School, UK, with Professor Sir Alfred Cuschieri. He has completed his surgical residency and Master's degree in Minimal Access Surgery (M.MAS) from Ninewells Hospital and Medical School, University of Dundee, UK.

RK Mishra is among the few fortunate who has been conferred the degree of Master in Minimal Access Surgery by Sir James Whyte Black (Nobel Prize Winner in Medicine) and the most prestigious Chancellor in the history of the University of Dundee, United Kingdom. After mastering laparoscopic surgery, he has further refined his robotic surgery training at Harvard Medical School, Boston, USA. He has taken his Diploma in Laparoscopic Surgery from the University of Strasbourg, France.

After returning to India from the UK in the year 2001 he worked at Indraprastha Apollo Hospital, New Delhi, India. He could feel the pain and concern about high-cost laparoscopic surgery to Indian people and he started performing free laparoscopic surgery for the needy. Due to his charity work, he received Super Idol Award from Being Human Foundation, a registered charitable trust of Salman Khan. He also felt the commercialization of half-cooked fractured laparoscopic training available in India. These training programs were in the hand of the industry that makes laparoscopic instruments. Keeping in mind the need for time and being the first qualified Master Minimal Access Surgeon, he started giving training in Minimal Access Surgery. His way of providing real laparoscopic training had no parallel in the whole world and that convinced the majority of the international organization of minimal access surgery that real laparoscopic training to young and practicing surgeons is possible if like-minded people join hands and work towards achieving this goal. According to him if you have to make the community of Minimal Access Surgeons then catch them young. Due to his dedication, World Laparoscopy Hospital, Gurugram, Haryana, India is the center of excellence in minimal access surgery.

Printed in India

Available at all medical bookstores or buy online at www.jaypeebrothers.com

JAYPEE BROTHERS
Medical Publishers (P) Ltd.
EMCA House, 23/23-B, Ansari Road,
Daryaganj, New Delhi - 110 002, INDIA
www.jaypeebrothers.com

Join us on facebook.com/JaypeeMedicalPublishers

Shelving Recommendation
SURGERY

ISBN 978-93-90020-61-4

9 789390 020614