rothers.com, for detailed information on radiology books, visit our website www.jaypeebrothers.com, for detailed information on radiology books

Celebrating 50

Passion, Quality and Innovation in Healthcare Publishing

Principles and Practice of Ultrasonography



THIRD EDITION

Sumeet Bhargava
Satish K Bhargava

JAYPEE

Contents

1. **Historical Perspective of Ultrasound** 1
   Satish K Bhargava
2. **Nature of Ultrasound** 4
   Satish K Bhargava, Amit Sahu
3. **Interaction of Ultrasound with Matter** 8
   Satish K Bhargava, Sumeet Bhargava
4. **Transducer** 12
   Satish K Bhargava, Sumeet Bhargava
5. **Basic Ultrasound Instrumentation** 20
   Satish K Bhargava, Amit Sahu
6. **Real Time Ultrasound** 30
   Satish K Bhargava, Amit Sahu, Sumeet Bhargava
7. **Ultrasound Artifacts, Biological Effects of Ultrasound, Image Quality, and Instrumentation** 37
   Satish K Bhargava, Sumeet Bhargava
8. **Scanning Techniques in Sonography** 51
   Satish K Bhargava, Rajul Rastogi, Sumeet Bhargava
9. **Basic Sonographic Anatomy** 63
   Sumeet Bhargava, Rajul Rastogi
10. **Abdomen: Hepatobiliary System and Spleen** 130
    Sumeet Bhargava, Shuchi Bhatt, Amit Sahu
11. **Abdomen: Pancreas** 158
    Shuchi Bhatt, Rajul Rastogi, Sumeet Bhargava
12. **Abdomen: Gastrointestinal Tract** 164
    Satish K Bhargava, Sumeet Bhargava
13. **Abdomen: The Urinary Tract** 172
    Sumeet Bhargava, Shuchi Bhatt, Satish K Bhargava
14. **Abdomen: Adrenal Glands** 193
    Satish K Bhargava, Sumeet Bhargava, Rajul Rastogi
15. **Abdomen: The Retroperitoneum** 196
    Rajul Rastogi, Amit Sahu, Shuchi Bhatt, Sumeet Bhargava
16. **Abdomen: The Peritoneum** 202
    Sumeet Bhargava, Rajul Rastogi, Amit Sahu
17. **Abdomen: The Uterus and Adnexa** 209
    Shuchi Bhatt, Rajul Rastogi, Sumeet Bhargava
18. **Pediatric Abdomen** 224
    Satish K Bhargava, Sumeet Bhargava
19. **Intracranial Sonography** 236
    Sudhanshu Bankata, Sumeet Bhargava, Satish K Bhargava
20. **Eye and Orbit** 243
    Satish K Bhargava, Rajul Rastogi, Sumeet Bhargava

JAYPEE BROTHERS

21. Thyroid **250**
Sumeet Bhargava, Satish K Bhargava, Amit Sahu

22. Small Part Ultrasound **253**
Satish K Bhargava, Sumeet Bhargava, Rajul Rastogi, Shuchi Bhatt

23. Ultrasound Examination of the Peripheral Arteries **277**
Satish K Bhargava, Rajul Rastogi, Sumeet Bhargava

24. Intraoperative and Laparoscopic Sonography **293**
Satish K Bhargava, Sumeet Bhargava, Rajul Rastogi

25. Intravascular Ultrasound: Current Concepts **301**
Chander Mohan, Rajul Rastogi, A Verma

26. Perendoscopic Ultrasound **310**
Sumeet Bhargava, Satish K Bhargava, Rajul Rastogi

27. Contrast Agents for Ultrasound **314**
Sumeet Bhargava, Satish K Bhargava

28. Normal Ultrasound Measurements **318**
Satish K Bhargava, Sumeet Bhargava, Amit Sahu

29. Obstetric Ultrasound **331**
Satish K Bhargava, Rajul Rastogi, Sumeet Bhargava

30. Interventional Radiology **378**
Poonam Narang

31. Color Doppler **383**
Shuchi Bhatt, Rajul Rastogi, Sumeet Bhargava, Satish K Bhargava

32. Basics of Echo **405**
Atul Luthra

33. Elastography **421**
Amit Sahu, Sumeet Bhargava

34. Musculoskeletal Ultrasonography **423**
Amit Sahu, Sumeet Bhargava

Index *443*

JAYPEE BROTHERS

12

CHAPTER

Abdomen: Gastrointestinal Tract

Normal gut has a reproducible pattern or "gut signature", and a variety of gut pathologies create recognizable sonographic abnormalities. On sonography the gut signature varies from a bull's eye appearance in cross-section (an echogenic center with a hypoechoic rim) to full depiction of five sonographic layers. With 5.0 MHz probes the sonographic layers are alternately echogenic and hypoechoic; the first, third and fifth are echogenic and the second and fourth are hypoechoic **(Figs. 12.1 to 12.5)**.

Gut Wall Pathology

Gut wall pathologies creates a characteristic sonographic pattern **(Figs. 12.6A and B)**. The most familiar is a "target" pattern, symmetric if the echogenic mucosa is centrally placed or asymmetric if present on one side of the hypoechoic gut wall. The "pseudokidney" **(Fig. 12.7)** pattern is also specific for gut wall pathologies. The thickened gut wall corresponds to the hypoechoic external rim while the residual gut lumen or mucosal ulceration appears as the echogenic center. Gut wall masses are distinct from the thickened gut wall, and may be intraluminal, mural or exophytic. Intraluminal masses are frequently obscured by gut gas or luminal contents. The exophytic masses are more



Fig. 12.2: Anterior and posterior wall of stomach irregularly thickened in a case of linitis plastica.



Fig. 12.1: Coronal scan showing thickened stomach wall in the region of the fundus in a case of carcinoma stomach.

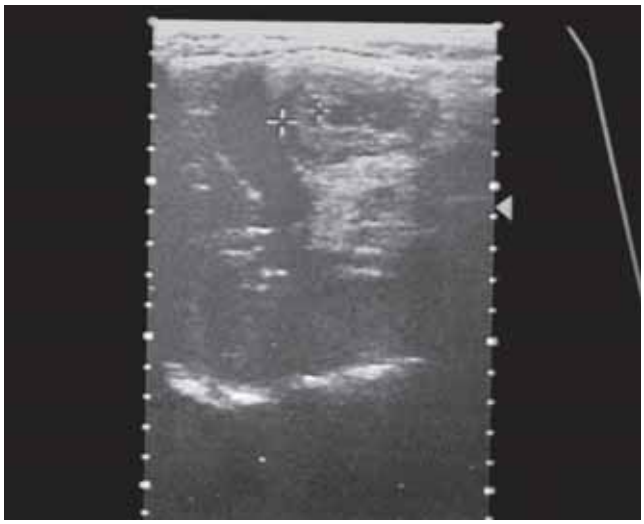

Fig. 12.3: Duodenal wall appears thickened.

JAYPEE BROTHERS

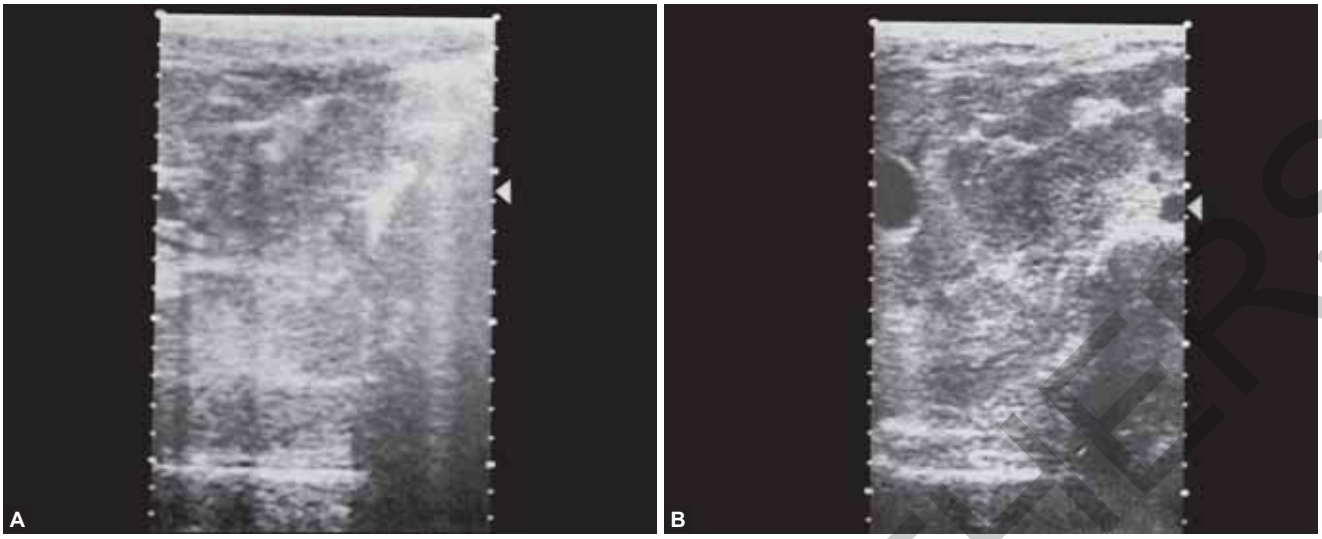

Figs. 12.4A and B: (A) Concentric bowel thickening is seen in the region of stomach and duodenum in a case of gastric lymphoma extending into the duodenum; (B) A small hypoechoic lesion is seen (shown by cursor) suggestive of lymph node.

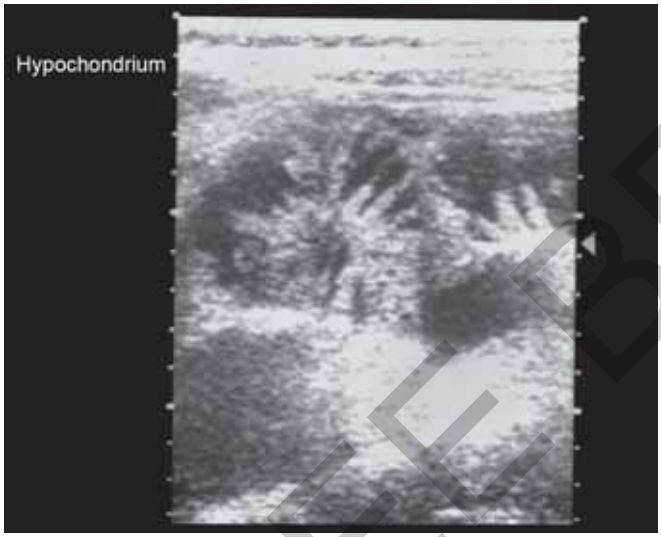

Fig. 12.5: Dilated fluid-filled jejunal loops: Valvulae conniventes are well seen.

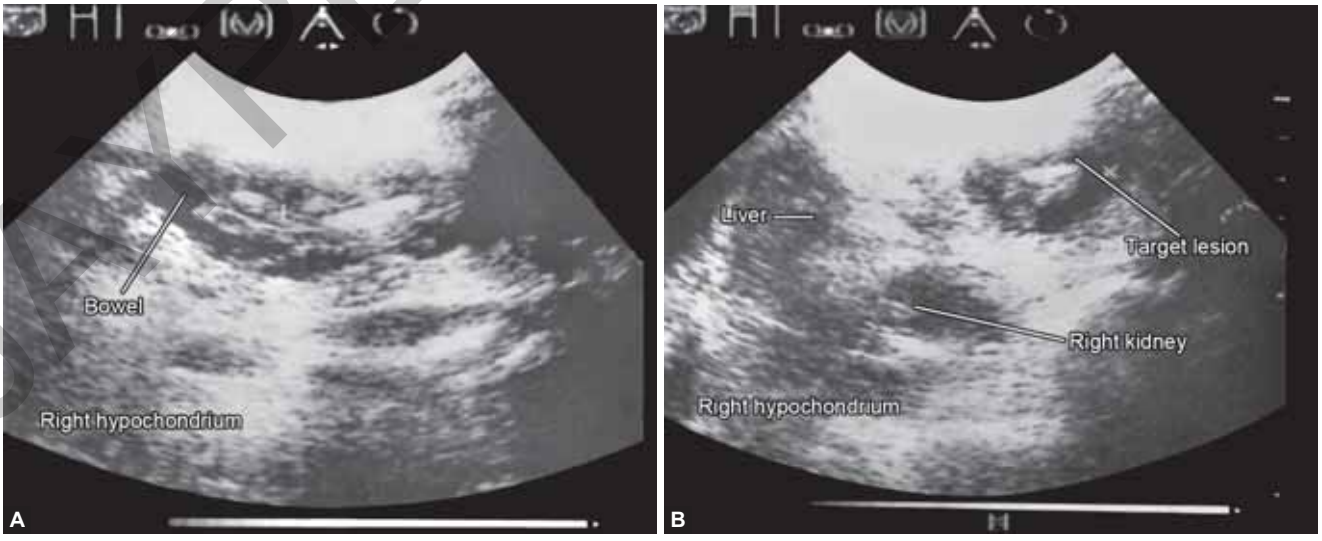

Figs. 12.6A and B: Target lesion: Longitudinal and transverse scan showing bowel thickening.

JAYPEE BROTHERS

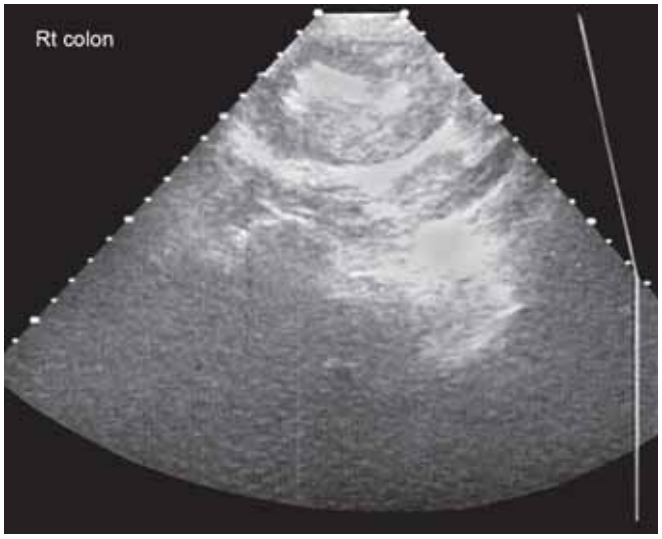

Fig. 12.7: Pseudokidney sign seen in a case of bowel thickening.

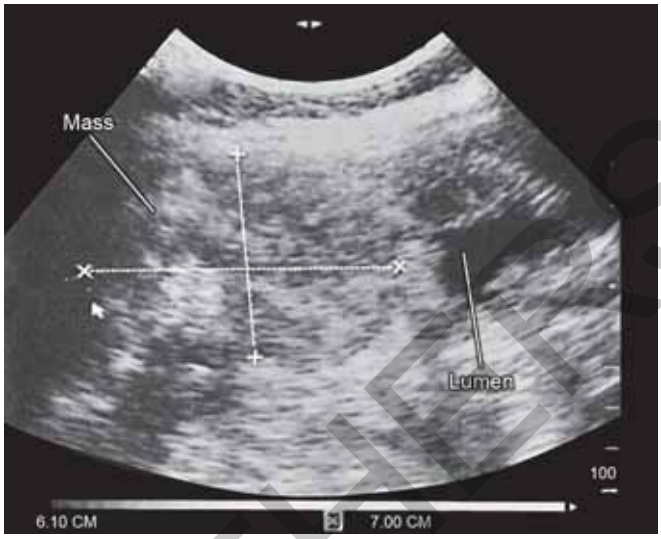

Fig. 12.8: Carcinoma colon—a large soft tissue mass, predominantly hypoechoic is seen arising from the hepatic flexure.

easily visualized but they may be difficult to assign to a GI origin if typical gut signatures are not seen on sonography.

GASTROINTESTINAL TRACT NEOPLASMS

Middle or elderly people presenting with vague abdominal symptomatology, abdominal pain, a palpable abdominal mass and anemia are often investigated by US to exclude GI malignancy.

Adenocarcinoma

It is the most common malignant tumor of the gastrointestinal (GI) tract. It accounts for 80% of the malignant gastric neoplasms and most commonly affects the prepyloric region, antrum and lesser curve. Adenocarcinomas are much less frequent in the small bowel and 90% of these arise in the duodenum and proximal jejunum.

Colon carcinoma **(Fig. 12.8)** is very common. Adenocarcinoma has the following growth patterns—polypoidal, fungating, ulcerated and infiltrative. On sonography only the large mass intraluminal or exophytic and annular tumors create abnormalities like target lesion—symmetric or asymmetric or a pseudokidney appearance. Tumor is usually hypoechoic and presence of air in the mucosal ulceration is seen as a linear echogenic foci with ring down artifact. Annular lesions may produce sonographic features of gut obstruction which includes hyperperistaltic, dilated fluid filled bowel loops. Evidence of direct tumor invasion, lymph nodes and liver metastasis is also looked for.

Mesenchymal Tumors

Tumors of smooth muscle origin are more common as an incidental finding. On sonography they appear typically as rounded mass lesions of varying size and echogenicity often with a central cystic necrotic area. If ulceration is present, gas in the tumor seen as echogenic line with ring down artifact suggests its gut origin.

Lymphoma (Figs. 12.4A and B)

Lymphoma affects the gut as primary non-Hodgkin's lymphoma or as widespread dissemination in stages III and IV lymphoma. Small submucosal nodules are easily overlooked on US, but the large, hypoechoic masses are seen well. Long linear, high amplitude echoes with ring-down artifacts, indicating gas in the residual lumen or ulceration, are frequently seen. Regional or generalized lymph node enlargement may be present. Lymphoma can also present as a thickening of the bowel wall.

Metastatic Tumors

Malignant melanoma and primary tumors of the lung and breast are more likely to have secondary involvement of the GI tract. Stomach involvement occurs more often than small bowel and colon. The usual sonographic appearance is that of hypoechoic well-defined masses that often have bright specular echoes with ring down artifacts in areas of ulceration. Omental or peritoneal deposits are also found with evidence of ascites. Extensive omental cakes with involved gut loops appear as a heterogeneous mass lesion.

INFLAMMATORY BOWEL DISEASE

Crohn's disease and ulcerative colitis are chronic bowel diseases of inflammatory nature characterized by multiple remissions and exacerbations, and are well assessed by a noninvasive modality like US **(Figs. 12.9 and 12.10)**. Crohn's disease most commonly affects the terminal ileum

JAYPEE BROTHERS

and colon. Sonography documents the classic features of Crohn's like gut wall thickening, strictures, creeping fat, mesenteric lymphadenopathy and uncommonly the mucosal abnormality or complications like phlegmon, obstruction, perforation or appendicitis **(Figs. 12.11 to 12.15)**. Gut wall thickening is most frequently concentric with preservation of normal gut layers. Echogenicity is variable. Sometimes target or a pseudokidney appearance may be evident. The involved gut segment is rigid and fixed with no visible peristalsis. Strictures can cause obstruction which is inferred if dilated hyperperistaltic segments are seen proximally. Edema and fibrosis of the adjacent mesentery produces a mass in the mesentery which may involve the near by diseased gut. This appears as a hyperechoic mass medial and superior to the ileocecal valve. Creeping mesenteric fat is seen as a uniform echogenic halo around the mesenteric border of the gut with a "thyroid-like" appearance in cross-section, conglomerate masses having matted bowel, inflamed edematous mesentery, increased fat deposition and uncommonly mesenteric lymphadenopathy may be found. Complex or fluid filled masses with gas are suspicion of abscesses. Fissures are also visible as echogenic linear areas penetrating deeply into the wall beyond the margin of gut lumen. If the fistulous tract is empty it appears as a hypoechoic linear tract and echogenic if it contains gas.

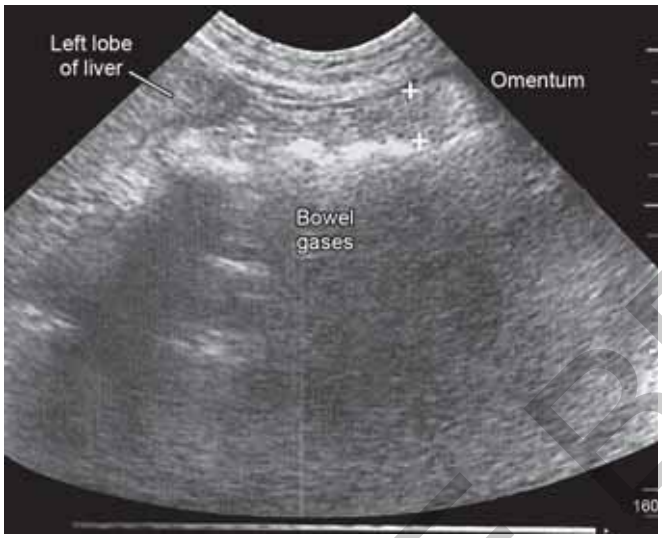

Fig. 12.9: Thickened omentum (1.6 cm) in a case of abdominal Koch's.

Acute Abdomen

Sonography is valuable in imaging patients with specific GI diseases, e.g. acute appendicitis or acute diverticulitis or patients with a distended and gasless abdomen, in detecting ascites, unsuspected masses or abnormally dilated fluid-filled loops of small bowel. A systematic approach is invaluable in the sonographic assessment of the abdomen in a patient with an acute abdomen. Gas seen as echogenic focus with dirty shadowing or ring down artifact is assessed for its location, whether intraluminal or extraluminal. Extraluminal gas could be intraperitoneal or extraperitoneal and is due to perforation of bowel or infection by gas forming organism. Gas in gut wall with or without gas in the portal vein is found in ischemia of gut. Gas in biliary tree is seen in biliary enteric fistulas or emphysematous cholecystitis. Fluid could be seen inside the normal caliber or dilated gut or could be extraluminal. Extraluminal fluid may be free or loculated. Presence of echoes or strands is noted inside the fluid collection. Inflammation of the pericecal fat appears as an echogenic "mass effect" often with absence of the usual appearance created by normal gut. The real time sonography also delineates the focal points of

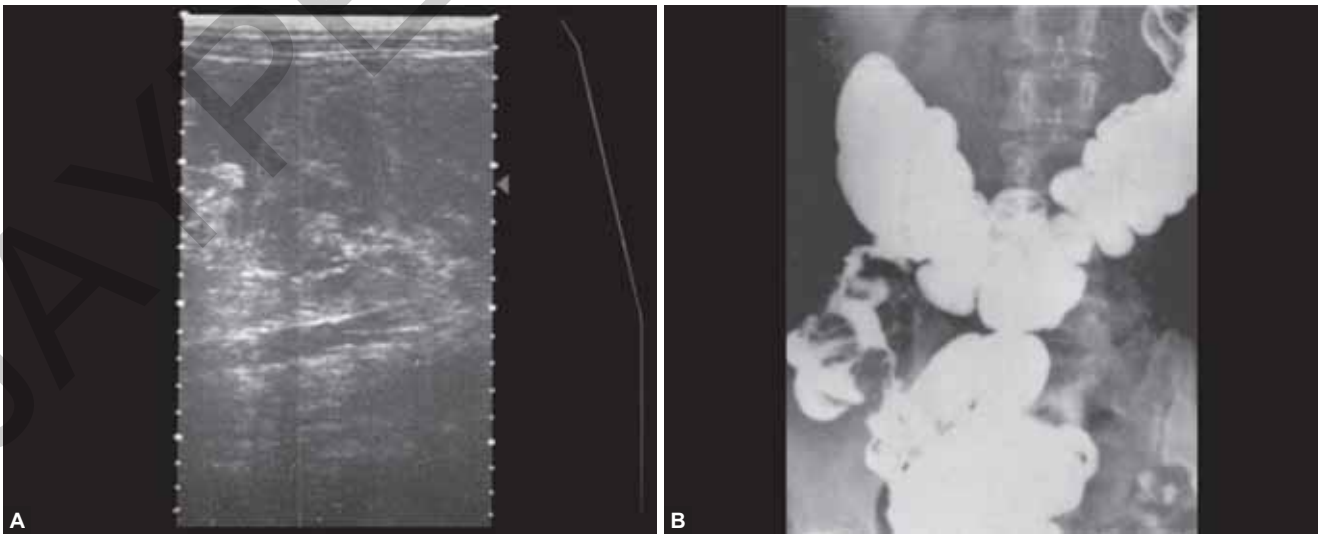

Figs. 12.10A and B: (A) Matted bowel loop: clumped small bowel loops are seen in right iliac fossa (RIF) with surrounding free fluid in a case of abdominal tuberculosis; (B) Barium enema film of cecal region shows gross thickening of wall.

JAYPEE BROTHERS



Fig. 12.11: Inflammatory thickening of cecum and appendix is seen in a case of typhilitis.



Fig. 12.12: Longitudinal and transverse scans of right iliac fossa (RIF) shows inflamed appendix. However no periappendicular collection is seen.



Fig. 12.13: Appendicular lump: Seen as an ill-defined complex SOL in the right iliac fossa. Inflamed appendix, periappendiceal fat and omentum are seen in the lump, adherent bowel loops are also seen.

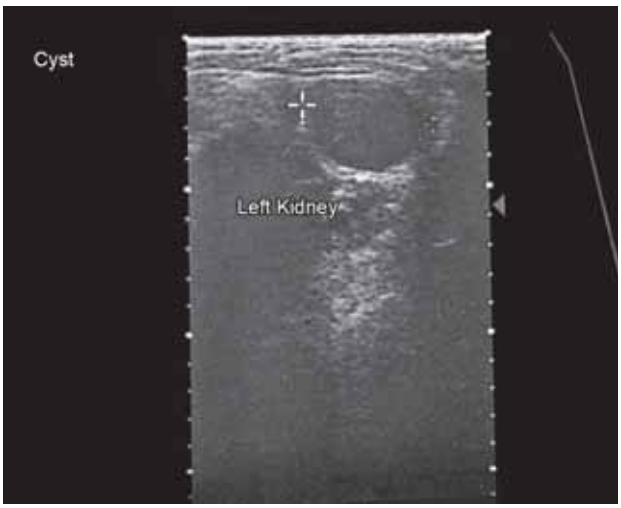

Fig. 12.14: Mesenteric cyst seen as an anechoic cystic SOL anterior to left kidney.

JAYPEE BROTHERS

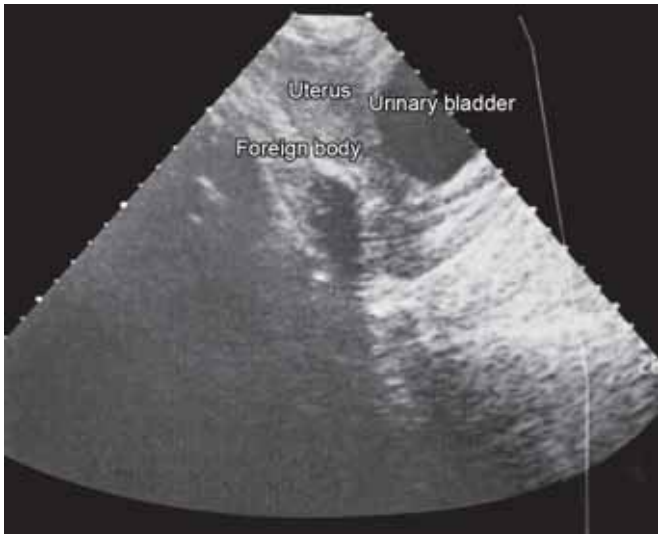

Fig. 12.15: Postoperative case of ileal perforation shows a dense echogenic focus with distal acoustic shadowing in the pouch of Douglas suggestive of foreign body in pouch of Douglas.

tenderness in the patients abdomen sonographic Murphy or sonographic McBurney sign. Mesenteric lymphadenopathy occurring due to inflammatory and neoplastic processes appears as focal, discrete, rounded, and hypoechoic masses.

Acute Appendicitis

This is the most common cause of acute abdomen and classically presents with pain (first periumblical, then shifting to the right iliac fossa), vomiting and fever. Sonography helps in diagnosing cases with atypical and confusing presentations. An appendix is seen as a blind-ended, aperistaltic tube arising from the tip of cecum with a gut signature. The normal appendix is compressible with a wall thickness of 3 mm. Inflamed appendix is noncompressible with a diameter of greater than 6 mm. An appendix with an appendicolith, regardless of the diameter is also suggestive of appendicitis. The sensitivity of sonography to detect appendicitis decreases with perforation of the appendix. US features in such cases are loculated pericecal fluid or circumferential loss of the submucosal layer.

Acute Diverticulitis

Diverticular disease is an acquired condition whose incidence increases with age. These are multiple and most commonly occur in the sigmoid and left colon. They become clinically significant when inflamed, presenting with left lower quadrant pain, fever, and leukocytosis. Micro-perforation leads to abscess formation as well. In few cases fistula formation also occurs. On US, segments of thickened gut and inflamed diverticula are evident. Concentric thickening of the gut wall is frequently hypoechoic while the inflamed diverticula are seen as bright echogenic foci, with acoustic shadowing or ring down artifact, within or beyond the thickened gut. Acute inflammatory changes in the pericolonic fat are seen as poorly defined hyperechoic zones with gas or fluid. Abscess is seen as loculated fluid collection in an intramural or pericolonic location. With the spread of inflammation the diverticula are no longer visible. Intramural sinus tracts are seen as linear high amplitude echoes often with ring down artifact with in the gut wall. Fistulas are seen as linear hypoechoic (if fluid filled) or hyperechoic (gas filled) tracts, extending from the inflamed gut wall to adjacent organs. Thickening of the mesentery may also be found.

Gastrointestinal Tract Obstruction

Mechanical obstruction is due to a physical impediment to the progression of the intraluminal content, while functional obstruction occurs due to paralysis of intestinal musculature (paralytic ileus).

Mechanical Obstruction

There are three types of mechanical obstruction: obstruction is related to blockage of the lumen by material in the lumen; e.g. bezoars, intussusception; intrinsic causes of gut wall like strictures or extrinsic lesions like adhesions (not visible on US), abscesses, etc. US is not helpful in most cases of GI obstruction as majority of the cases are due to adhesions and the presence of abundant gas hinders US examination. US study in cases of bowel obstruction should assess the following: GI tract caliber note any point at which the caliber changes, content of dilated loops, peristaltic activity within the dilated loops is markedly increased with a to and fro movement of the luminal content. In strangulation peristalsis decreases or ceases and the possible cause and site obstruction is also determined.

Closed Loop Obstruction

It occurs when bowel lumen is occluded at two points and is more prone to strangulation and necrosis. US shows a fluid-filled (with little or no gas) dilated loop.

Intussusception (Figs. 12.16 and 12.17)

Invagination of a bowel segment into the next distal segment frequently causes mechanical, intraluminal obstruction in children. US appearance of multiple concentric signs in cross-section is virtually pathognomonic. In longitudinal scan a "hay fork" appearance may be suggestive of the condition. Occasionally a target appearance may be seen.

Mid Gut Malrotation

In children presenting with acute GI obstruction and with the superior mesenteric vein present to the left ventral aspect of the superior mesenteric artery, suggests the said condition.

JAYPEE BROTHERS



Figs. 12.16A to C: (A) Intussusception is seen as target sign—hypoechoic solid mass with a central echogenic component; (B) Small bowel intussusception: trident sign is demonstrated in this scan along the long axis of the bowel; (C) Pseudokidney sign in intussusception.

PARALYTIC ILEUS

US is not helpful if large quantities of gas is present in the GI tract. Occasionally US may show dilated, fluid-filled, aperistaltic loops. A fluid-filled level in a dilated loop is characteristic of paralytic ileus.

GASTROINTESTINAL INFECTIONS

Intestinal Tuberculosis

Mycobacterium tuberculosis affects the terminal ileum and the cecum most frequently in the GI tract. Fifty percent of these patients have pulmonary Koch's. Sonography demonstrates striking concentric uniform thickening of the colon wall, usually localized to the cecum and adjacent ascending colon, terminal ileum also shows narrowing with increased wall thickness. Mesenteric lymph nodes seen as discrete or confluent hypoechoic masses. Omental nodes, splenomegaly with or without multifocal lesions, peritoneal masses, ascites-loculated or free with presence of strands in it, omental or mesenteric thickening may also be appreciated.

Pseudomembranous Colitis

This is a necrotizing inflammation of bowel (colon) due to a variety of causes and presents with fever, abdominal pain and watery diarrhea. Proliferation of *Clostridium difficile* and release of its toxins following an antibiotic (vancomycin) therapy is the most common etiological factor. Sonographic feature is striking with thickening of the entire colon wall in a patient without a previous history of inflammatory bowel disease. Exaggerated haustral marking and nonhomogeneous thickened submucosa, virtual apposition of the mucosal surface of the thickened walls are characteristic findings.

Miscellaneous Abnormalities of GI Tract

Congenital abnormality: Duplication cyst may be present in any part of GI tract and are characterized by the presence of normal gut wall.

Ischemic bowel disease: Most commonly colon is affected in elderly persons who have arteriosclerosis. No specific finding may be seen on US. Sometimes gut wall thickening with or without linear echogenic focus seen in the gut wall

JAYPEE BROTHERS

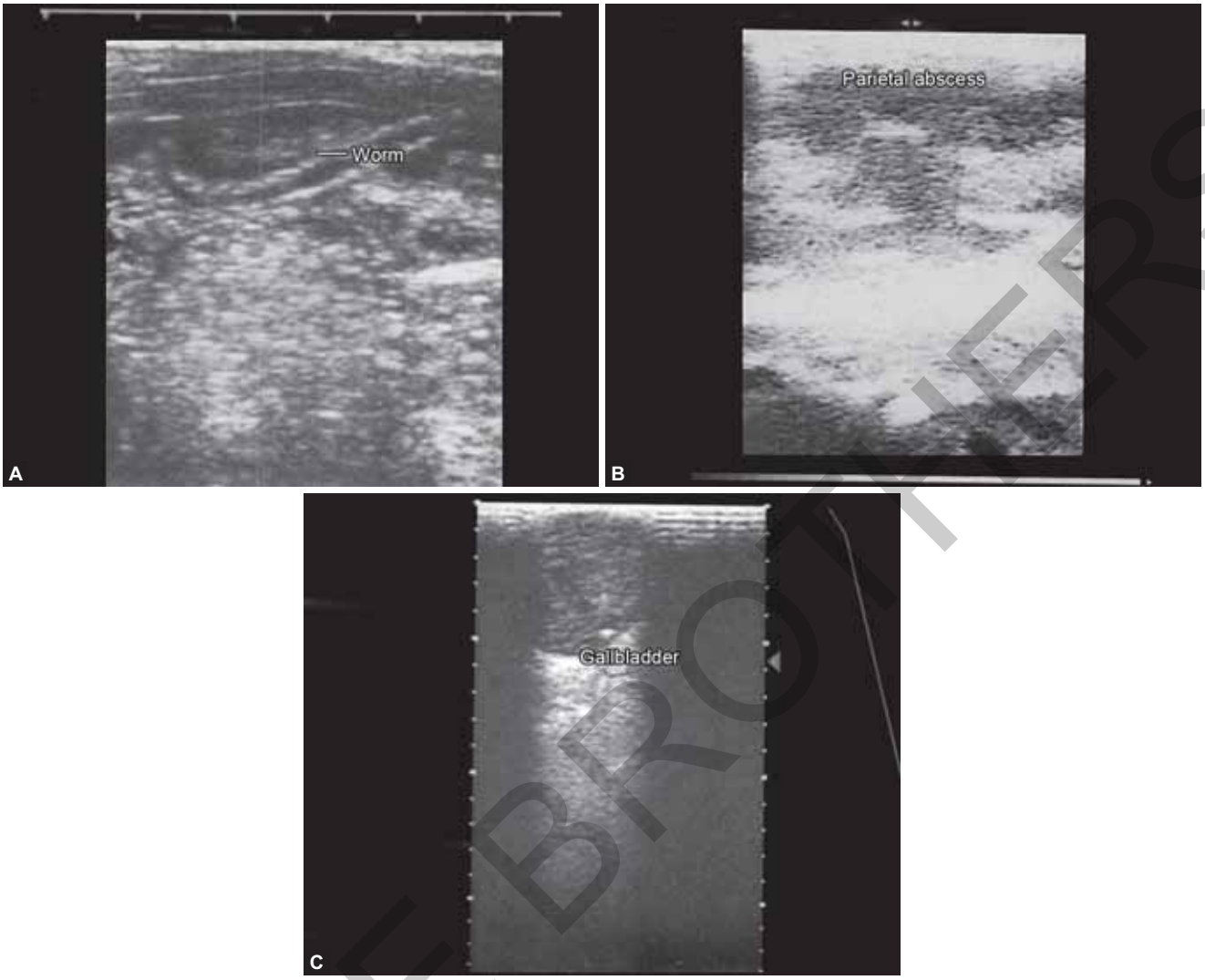

Figs. 12.17A to C: (A) Ascaris in bowel; (B) A hypoechoic irregular collection with evidence of posterior enhancement transecting the muscle planes is seen in a case of parietal abscess; (C) Antibioma—a well defined rounded hypoechoic SOL enhancement is seen in the abdominal wall.

which gives dirty shadowing or ring down artifacts and thus suggests the presence of gas in gut wall.

Mucocele of appendix: This uncommon condition presents with a palpable mass lesion in the right lower quadrant of abdomen in 50% cases. Two varieties are known: a benign form and a malignant form. The lumen of appendix is obstructed by fecolith or scarring in the benign form or cystadenocarcinoma in the malignant variety. US appearance is that of a well-defined elongated, oval, cystic mass in the right lower quadrant which is hypoechoic with a variable internal echogenicity, wall thickness and wall calcification. Perforation of the malignant mucocele causes pseudomyxoma peritonei.

Gut Edema

Prominent thickened hypoechoic valvulae conniventes and gastric rugae are easily recognized on US being due to gut edema. Main causes are hypoalbuminemia, congestive cardiac failure, and venous thrombosis.

Peptic Ulcer

Stomach or duodenum are the locations of peptic ulcer, which is a defect in the epithelium extending to the depth of submucosa. US demonstrates a bright echogenic focus with ring down artifact, either in a focal area of wall thickening or beyond the wall.

Bezoars

These are masses of foreign material in the stomach as after ingestion of indigestible organic substance such as hair (trichobezoar). Ultrasonic appearance is that of intraluminal densities with evidence of shadowing.

JAYPEE BROTHERS

for detailed information on radiology books, visit our website www.jaypeebrothers.com, for detailed information on radiology books, visit our we

Principles and Practice of Ultrasonography

With the established use of ultrasound and advancement in technology in various systems of the body, this is the only book available covering scanning techniques, pathologies of the various systems of the body. It will be beneficial for Postgraduate students, Radiologists, Sonologists, Obstetricians and Practitioners to update their knowledge. A new chapter on Elastography has been added and many illustrations have been updated/added. This book will serve a larger purpose for the interest of the medical fraternity.

Sumeet Bhargava MBBS DNB (Radiodiagnosis) FICRI FIMSA FIAMS FCGP MNAMS FCCP is Associate Professor, Department of Radiology and Imaging, MS Medical College and Hospital, Hapur Road, Ghaziabad, Uttar Pradesh, India. He is a young Radiologist awarded Honors and Gold Medal in various subjects during his MBBS studies. He was trained at Dewan Chand Satya Pal Aggarwal Imaging Center; Rajiv Gandhi Superspecialty Hospital; All India Institute of Medical Sciences (AIIMS); and the University College of Medical Sciences (UCMS) and Guru Teg Bahadur Hospital, New Delhi, India. He has published 25 research papers both in national and international journals besides contributing many chapters in textbooks. He is a Life Member of the National Academy of Medical Sciences, International Medical Science Academy. He has been Awarded "Dr N Ram Das Best Research Paper Award" of Indian College of Radiology and Imaging (2009). Due to his extensive academic contribution, he has been awarded Fellowship of the College of General Practitioners (2010); M/s German Remedies Travelling Fellowship in Radiodiagnosis and Imaging of ICRI (2011); Fellowship of Indian College of Radiology and Imaging; Fellowship of IMA College of General Practitioners (2011); Fellowship of National College of Chest Physicians.

Satish K Bhargava MD (Radiodiagnosis) MD (Radiotherapy) DMRD FICRI FIAMS FIMSA FCCP FUSI FAMS is Former Head, Department of Radiology and Imaging, University College of Medical Sciences (University of Delhi) and Guru Teg Bahadur (GTB) Hospital, New Delhi, India. He is also Former Head, Department of Radiology and Imaging, School of Medical Sciences and Research, Sharda Hospital, Sharda University, Greater Noida, Uttar Pradesh and Department of Radiology and Imaging, JN Medical College, Aligarh Muslim University, Aligarh, Uttar Pradesh, India. He was an advisor to set up the Department of Radiology at BP Koirala Institute of Health Sciences (BPKIHS), Nepal. In fact, he has also established the Department of Radiology at the University College of Medical Sciences (UCMS), New Delhi.

He has been an author of many textbooks, an excellent teacher and contributed more than 350 research papers in various national and international journals. Due to his wide academic contribution, he has been awarded Sir JC Bose Memorial Oration, distinguished Medical Teachers' Award, BC Roy Award, Brig SK Majumdar Oration Award, Swami Vivekanand Oration Award, Prithvinath Bhargava Memorial Oration Award, and GEMS International Award. He was working as the Chairman, Board of Research Studies, University of Delhi. He has also been awarded distinguished Excellence DNB Teachers' Award by Vice President of India; Lifetime Academic Excellent Award by Vice-Chancellor, Aligarh Muslim University; Lifetime Achievement Award by National Indian Radiological and Imaging Association on 23rd, January 2020; Lifetime Achievement Award by Delhi State of Indian Radiological and Imaging Association on 8th Feb 2020.

His unique contribution to the field of medical science in his Hindi books such as *Vikiran Vigyan* and *Cancer Ke Tathya*. In recognition of his contribution to his books in Hindi, he has been awarded *Maulik Hindi Pustak Puraskar* by the Ministry of Health and Family Welfare, Government of India. He has also translated and edited a book on *Diagnostic Ultrasound ka Manual* in Hindi, on behalf of WHO published by M/s Jaypee Brothers Medical Publishers (P) Ltd, New Delhi, India.

He has widely traveled abroad for a number of assignments and fellowships such as WHO Fellowship to USA and Finland; Visiting Fellowship to Holland; Harvard Medical School, Boston, USA; Thomas Jefferson Medical College, Philadelphia, USA and to UK, etc. and also invited by the French Government to attend a symposium on latest imaging technique at Paris. He was instrumental in innovating and starting vocational training courses like Diploma in Radiography, BSc and MSc (Medical Technology Radiography) course under University of Delhi.

Due to his wide academic contribution, he has served as Secretary, Indian College of Radiology and Imaging; Chairman, Indian College of Radiology and Imaging; and National President, Indian Radiological and Imaging Association.

Available at all medical bookstores or buy online at www.jaypeebrothers.com

JAYPEE BROTHERS
Medical Publishers (P) Ltd.
www.jaypeebrothers.com

Join us on facebook.com/JaypeeMedicalPublishers

Shelving Recommendation
RADIOLOGY

ISBN 978-93-90020-82-9