others.com, for detailed information on obstetrics & gynecology books, visit our website www.jaypeebrothers.com, for detailed information on obstetrics & gynecology books

diginerve
A Jaypee Initiative
Your Guide at Every Step
Video Lectures | Notes | Self-Assessment
Scan to Know More

Instruments and Procedures in Obstetrics and Gynecology

Kiran Agarwal



Foreword
Narendra Malhotra

SECOND EDITION

JAYPEE

Instruments and Procedures in
OBSTETRICS AND GYNECOLOGY

SECOND EDITION

Kiran Agarwal MD FICOG

Professor
Rohilkhand Medical College and Hospital
Bareilly, Uttar Pradesh, India

Pro Vice-Chancellor
Bareilly International University
Rohilkhand Medical College and Hospital
Institute of Dental Sciences
Rohilkhand College of Nursing
Rohilkhand College of Pharmacy
Rohilkhand College of Paramedical Sciences, Bareilly

Vice President
Varun Arjun Medical College and Rohilkhand Hospital
Shahjahanpur, Uttar Pradesh, India
Varun Arjun College of Nursing
Varun Arjun College of Pharmacy
Varun Arjun Institute of Paramedical Sciences
Banthra, Shahjahanpur

Foreword

Narendra Malhotra

JAYPEE BROTHERS MEDICAL PUBLISHERS
The Health Sciences Publisher
New Delhi | London

JAYPEE BROTHERS

Contents

Section 1: Instruments for Examination in Obstetrics and Gynecology 1

Sims Speculum 1
Cusco's Speculum 4
Auvard Speculum 6
Sims Anterior Vaginal Wall Retractor 7
Vulsellum 8
Tenaculum 10
Uterine Sound 12
Bladder Sound 13
Pinard Stethoscope (Fetoscope) 14
Stethoscope and Digital Fetal Doppler 15

Section 2: Instruments for Dilatation, Curettage and Evacuation 17

Hegar's Dilators 17
Uterine Curette 20
Endometrial Biopsy Curette 24
Pipelle 26
Ovum Forceps 27
Karman Double Whistle Cannula, Karman Menstrual Regulation Syringe and Manual Vacuum Aspiration Syringe 29
Laminaria Tent 35

Section 3: Instruments for Tubal Patency Test 37

Instruments for Tubal Patency Tests 37

Section 4: Instruments for Operative Vaginal Delivery 44

Obstetrical Forceps 44
Ventouse or Vacuum Extractor 56

JAYPEE BROTHERS

Section 5: Instruments for Destructive Operations 62

Instruments for Destructive Operations 62

Section 6: Catheters 69

Catheters 69

Section 7: General Instruments in Obstetrics and Gynecology 74

Cheatle Forceps 74
Towel Clips 75
Sponge Holding Forceps 76
Bard Parker's Knife 77
Retractors 79
Needle Holder 86
Dissecting Forceps 88
Artery Forceps 90
Pessary 94
Tissue Holding Forceps 95
Scissors 98
Umbilical Cord Clamp 104

Section 8: Special Instruments in Obstetrics and Gynecology 105

Green Armytage Forceps 105
Doyen's Myoma Screw 106
Bonney's Myomectomy Clamp 106
IUCD Removing Hook 108
Uterine Packing Forceps 109
Uterus Holding Forceps 111
Mersilene Tape 112
Shirodkar Cervical Encerclage Needles 114
Intrauterine Insemination Cannula 116
Electrosurgical Loop 119
Cervical Punch Biopsy Forceps 121
Cryomachine 122
Suture Materials 125

JAYPEE BROTHERS

Section 9: Instruments for Cervical Screening 135

Ayre's Spatula and Cytobrush 135
Colposcope 147

Section 10: Diagnostic Tools 153

Cardiotocograph 153
Hysteroscope 164
Laparoscope 168
Ultrasound 173
Further Reading *181*
Index *183*

JAYPEE BROTHERS

SECTION 2

Instruments for Dilatation, Curettage and Evacuation

HEGAR'S DILATORS

These are curved double ended dilators with conical tips used to dilate endocervical canal and internal os rapidly.

Types

- Metallic
- Plastic.

Sizes

- Size increases gradually ranging from diameter of few millimeters to more than 2 cm. Number of dilators are according to diameter of the shaft. Each double ended dilator has two sizes with a difference of 0.5 mm **(Fig. 2.1)**.

Parts

- Solid rod which is curved near the tip.
- Tip is tapered. The dilating portion is within terminal 1.5 cm of dilator.



Figure 2.1: Hegar's dilators.

JAYPEE BROTHERS

Technique

- Consent
- Patient preparation. Empty bladder.

Steps

1. Anesthesia and patient positioning
   - GA or paracervical block
   - Dorsal lithotomy position
   Bimanual examination.
2. Uterine sounding is done after retraction with speculum and holding cervix with vulsellum. Sounding confirms size and direction of the uterus.
3. **Uterine dilatation**: Hegar's dilator is held as in pen holding manner in right hand by thumb and first two fingers, while fourth and fifth fingers and heel of hand (ulnar border) rests on perineum and buttock. This prevents injury from sudden and excessive dilatation **(Fig. 2.2)**.

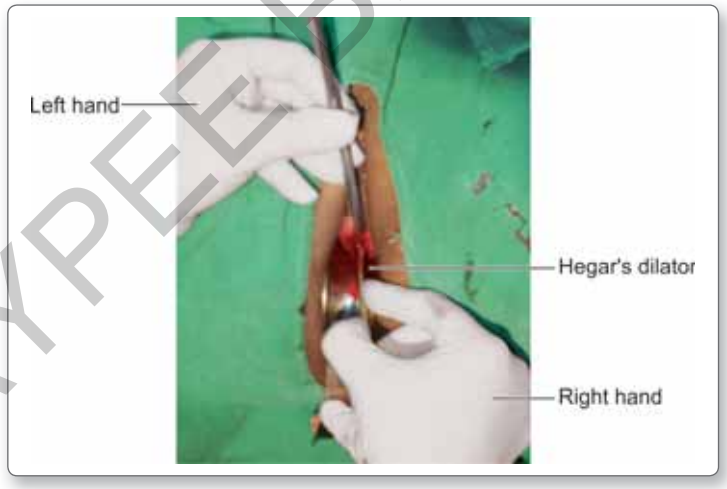

Figure 2.2: Method of cervical dilatation.

JAYPEE BROTHERS

- The right and left hand provide traction and counter traction so that the amount of pressure is controlled while dilating the cervical os.
- Each dilator is gently and gradually advanced through the internal os.
- Serial dilatation continues until cervix admits the selected curette.
- Tip is directed anteriorly or posteriorly according to direction of the uterus whether it is anteverted or retroverted.
- For MTP the dilatation required depends on size of pregnancy in weeks, i.e., for 6 weeks pregnancy the size of dilator required is no. 6.

Uses

Uses in Gynecology

- Prior to curettage (commonest), D and C and polypectomy.
- Prior to hysteroscopy.
- Acquired or congenital cervical stenosis. To prevent cervical stenosis following Manchester operation for prolapse of uterus and following conization.
- To drain hematometra, pyometra.
- Smaller sizes can be used as urethral dilator in stricture.
- Prior to removal of embedded intrauterine contraceptive device dilator no. 4/no. 5 is used.
- Prior to breaking uterine adhesions in Asherman's syndrome.
- To diagnose incompetent os, if no. 8 dilator goes easily in the internal os of the cervix in nonpregnant patient.
- Prior to insertion of radium into the uterine cavity in cancer cervix and endometrial cancer.
- Dysmenorrhea.

Uses in Obstetrics

- D and E, MTP, incomplete abortion, missed abortion, vesicular mole.
- Drain lochiometra.
- Retrograde dilatation in elective cesarean section.

JAYPEE BROTHERS

Advantages

- The angle makes the instrument less traumatic.
- The increasing sizes of dilators make cervical canal patulous by gradually stretching the muscle and fibrous tissue of the cervix.

Disadvantages

Complications are few and rare

- Vasovagal shock due to forceful dilatation.
- Injury: Cervical tear and laceration, false passage.
- Uterine perforation occurs mainly in soft uterus, i.e., pregnant uterus, in atrophic postmenopausal or scarred uterus and can also occur in malignant uterus. In acute anteflexion the dilator can perforate posteriorly and when retrodisplacement exists, the perforation usually occurs anteriorly. When dilator goes further in **without resistance** beyond measured length of uterine cavity then perforation is suspected.
- Hemorrhage.
- Infection.
- Injury to bladder and intestine.
- Late: Cervical incompetence (due to excessive dilatation) and cervical stenosis.

UTERINE CURETTE

It is a long double ended instrument.

Sizes

Different sizes of loops from a few millimeters to few centimeters are available.

JAYPEE BROTHERS

Parts

The terminal ends are oval loops. They are angled to the shaft.

It is differentiated from anterior vaginal wall retractor by following points:

- It is smaller
- Oval loops are sharp and blunt without transverse serrations.

- **Sharp** end has smaller loop and is used in gynecological conditions.
- **Blunt** end has larger loop and is used in obstetrics **(Fig. 2.3)**.



Figure 2.3: Blake blunt and sharp uterine curette.

Technique

- Consent
- Patient preparation. Empty bladder
- Injection atropine is given to prevent vasovagal attack.

Steps

1. Anesthesia and patient positioning
   - GA or sedation with a paracervical block with 1% lignocaine, 5 to 10 mL at 3 and 9 O' clock position.
   - Lithotomy position
     Bimanual examination.
2. Uterine sounding
   - After retracting vagina with speculum and holding cervix with vulsellum confirm the size and direction of the uterus.
3. Uterine dilatation
   - Done with dilators depending on size of curette to be inserted and indication of operation starting from no. 3 to no. 10.

JAYPEE BROTHERS

4. **Uterine curettage**
   - Uterine curette is introduced with tip facing anteriorly if uterus is anteverted and posteriorly if uterus is retroverted to avoid perforation. Curette is advanced to fundus following the long axis of corpus. Pressure is exerted gently but firmly against endometrium as curette is pulled towards internal cervical os lengthwise. Posterior surface is curetted followed by anterior and then left and right lateral surface and finally fundus. Action of curette is gentle one with curette lightly held in first three fingers and thumb of right hand.
   - Curetted endometrial sample is collected on swab placed just under posterior lip of cervix in posterior fornix. Tissue is sent for HPE in 10% formalin and AFB culture in saline as required. The angulation between loop and shaft helps in easy removal of uterine contents without causing injury to uterus.
     Normal endometrium is pink and healthy.
     Profuse, pale looking friable tissue suggests malignancy.

Hysteroscopy directed biopsy and curettage is a more accurate procedure.

Uses in Gynecology

Sharp end of curette is used.

- Dysfunctional uterine bleeding (DUB) for hormonal pattern.
- Secondary amenorrhea: To detect tubercular endometritis. Optimum results are obtained from endometrial samples curetted from cornua of the uterus as tuberculosis is a descending infection and cornual end is the first part of the uterine cavity to be affected.
- Postmenopausal bleeding: To rule out endometrial cancer.
- Endometrial cancer: To study the endocervical tissue and the extent of spread. This helps in staging and deciding treatment.

  For **fractional curettage** three specimens are taken and sent in labelled vials.
  - Undilated cervical canal: Endocervical curettage (ECC).
  - Dilated cervix just above the internal os from isthmic region.
  - From uterine cavity (4 walls, i.e., anterior, lateral, posterior and fundus).

    Involvement of endocervical lining places malignancy in stage II of the disease.

JAYPEE BROTHERS

- Infertility: Till now D and C was performed premenstrually to detect if ovulation has occurred or not. Proliferative endometrium indicates nonovulation and secretory endometrium indicates ovulation. Now D and C is replaced by ultrasound for monitoring ovulation except in tubercular endometritis where endometrial tissue is sent in saline for AFB culture and PCR.

  The corpus luteal phase defect is diagnosed if endometrial histology lags behind by 2 days of menstrual date.
- A menopausal woman on hormonal replacement therapy for endometrial hyperplasia and cancer.
- A woman on tamoxifen therapy for breast cancer must have curettage 6-monthly for the diagnosis of endometrial hyperplasia and cancer.
- Diagnosis of choriocarcinoma.
- Treatment of Asherman's syndrome to break adhesions.
- After removal of polyp and prior to myomectomy.

Uses in Obstetrics

Blunt end of the instrument is used for (check curettage)

- Incomplete abortion, missed abortion
- Evacuation of hydatidiform mole
- MTP (Medical termination of pregnancy)
- PPH for retained products of conception.

Disadvantages

Complications are less than 1%

- Infection
- Perforation
- Cervical injuries
- Hemorrhage
- Asherman's syndrome leading to amenorrhea and placenta praevia with over enthusiastic curettage as it damages the decidua basalis layer
- Infertility
- Ectopic pregnancy due to PID
- Rupture uterus during subsequent pregnancy or labor.

JAYPEE BROTHERS

Contraindications

- Suspected pregnancy
- Genital tract infection
- In acute endometritis and salpingitis curettage should be avoided
- Removal of the infected placental tissue is preceded by parenteral antibiotics
- Pyometra.

ENDOMETRIAL BIOPSY CURETTE

It is a long tubular instrument used for endometrial biopsy.

Parts

- Hollow and blunt tipped instrument
- The tip has a whistle subterminally which is notched and has cutting edge
- The instrument is angulated about 5 cm from tip for easier introduction in the uterine cavity **(Fig. 2.4)**
- Stilette is for removing biopsy tissue.



Figure 2.4: Randall endometrial biopsy curette.

JAYPEE BROTHERS

for detailed information on obstetrics & gynecology books, visit our website www.jaypeebrothers.com, for detailed information on obstetrics & gynecology books, visit our webs

Instruments and Procedures in Obstetrics and Gynecology

This book is a comprehensive account of instruments and procedures related to obstetrics and gynecology. It covers description of more than 150 instruments with colored photographs and operative procedures.

Instruments are described in a format that gives:

- Name of instruments
- Parts of instruments
- Procedures
- Uses of instruments
- Advantages, disadvantages and complications.

With all these features this book is an excellent guideline for students preparing for MBBS examinations and for resident doctors.

Kiran Agarwal MD FICOG is a Professor in Department of Obstetrics and Gynecology at Rohilkhand Medical College, Bareilly, Uttar Pradesh, India and is a fellow member of ICOG. She is founder member and Pro Vice Chancellor of Bareilly International University and Vice-President of Varun Arjun Medical College and Rohilkhand Hospital, Shahjahanpur, Uttar Pradesh, India. She has published research articles, review articles and case reports in several international and national journals. She is a social activist and plays an active role in providing tertiary medical care in Bareilly and adjoining regions.



Printed in India

Available at all medical bookstores or buy online at www.jaypeebrothers.com



JAYPEE BROTHERS
Medical Publishers (P) Ltd.
EMCA House, 23/23-B, Ansari Road,
Daryaganj, New Delhi - 110 002, INDIA
www.jaypeebrothers.com

Join us on facebook.com/JaypeeMedicalPublishers

Shelving Recommendation
OBSTETRICS & GYNECOLOGY

ISBN 978-93-90595-18-1

