ebrothers.com, for detailed information on surgery books, visit our website www.jaypeebrothers.com, for detailed information on surgery books

SURGERY

VOLUME 17



Roshan Lall Gupta's Recent Advances in SURGERY

Editor
Puneet



Contents

1. **Biomarkers of Sepsis** 1
   Nishanth Baliga, JV Divatia
2. **Surgery for Gastric Cancer** 13
   Arindam Mondal, Manish Suresh Bhandare, Vikram Anil Chaudhari, Shailesh V Shrikhande
3. **Prenatal Surgery** 34
   Vaibhav Pandey, Ajay N Gangopadhyay
4. **Etiopathogenesis and Management of Fecal Incontinence** 48
   Ashok Kumar, Kailash Chand Kurdia
5. **Targeted Therapy in Gastrointestinal Malignancy** 69
   Rahul, Mansi Sharma, Richa Sinha
6. **Recent Advances in Endoscopy** 92
   Jayanta Samanta, Akash Singh, Virendra Singh
7. **Evaluation of Incidental Dilated Bile Duct** 118
   Supriya Sharma, Anu Behari
8. **Antibiotics in Abdominal Surgery: Current Guidelines and Practices** 137
   S Suresh Kumar, R Kalayarasan, Vikram Kate, N Ananthakrishnan
9. **Malignant Melanoma** 159
   SVS Deo, Manoj Gowda
10. **Surgical Safety Checklist** 182
    Arunima Verma, Sharad Kumar, Vinita Singh, Sunil Kumar
11. **Management of Penile Carcinoma** 192
    Sameer Trivedi, Sabby Dias
12. **Microvascular Surgery** 217
    Arun Kumar Singh, Harsha Vardhan
13. **Inflammatory Breast Cancer** 232
    Vani Parmar, Garvit Chitkara
14. **Phyllodes Tumors of the Breast** 244
    Chintamani, Megha Tandon
15. **Management of Thyroid Nodule** 256
    Roma Pradhan, Amit Agarwal
16. **Surgical Practice in COVID Era** 273
    Sankha Shubhra Chakrabarti, RN Meena, SK Gupta

Index *295*

JAYPEE BROTHERS

CHAPTER 6

Recent Advances in Endoscopy

Jayanta Samanta, Akash Singh, Virendra Singh

INTRODUCTION

The role of endoscopy in the practice of gastroenterology and gastrointestinal (GI) surgery cannot be overstated. Over the years, its use has transformed from an initial diagnostic tool to one of the key therapeutic modalities for patient care.[1] With the advent of newer technologies, the art of endoscopy has advanced from basic tissue harvesting to early detection of disease conditions and hence advocate better management options. Moreover, the armamentarium of therapeutic endoscopy has exponentially expanded in recent years to even obviate surgery in various cases and thus, catapulted its popularity to become the touchstone for gastroenterology practice.

Technological advancement is a part and parcel of our daily life and the world of endoscopy has advanced with the advent of high-resolution endoscopes, newer devices such as capsule endoscopy, ability for endoscopic microscopic assessment, and various accessories. In fact, procedures such as endoscopic retrograde cholangiopancreatography, endoscopic ultrasound (EUS), and "third space" endoscopy have surely brought a paradigm shift in the management options for patients with GI diseases. A brief overview of the recent advances in the field of GI endoscopy will be highlighted in this review.

ADVANCES IN ENDOSCOPIC IMAGING

Flexible endoscopes, pioneered by Hirchowitz et al.[2] in 1957, used the fiber optic technology which transmitted light using the principle of total internal reflection through optic bundles and created an image at the tip using a lens. From the use of charged couple devices (CCDs), the world of image acquisition technology in the field of gastroenterology has come a long way to the current era of image-enhanced endoscopy with landmark technologies such as magnification endoscopy, autofluorescence imaging (AFI), electronic chromoendoscopy techniques such as narrow-band imaging (NBI), i-scan, or flexible spectral imaging color enhancement (FICE) and confocal laser endomicroscopy (CLE). The cutting edge technology allows endoscopist to view the minutest of details and clinch the culprit lesion. In today's era of early cancer detection, these technologies have given comprehensive tools to create the effect of in vivo histological prediction, the concept of "optical biopsy."[3]

JAYPEE BROTHERS

High-resolution, High-magnification Endoscopy

A high-magnification capability in an endoscope enables the power of optical zoom to get a closer image of the target keeping the resolution intact. This is in stark contrast to an electronic magnification, wherein the image is merely brought closer at the cost of loss of pixels and hence image quality is hampered after a certain extent. This electronic magnification or digital zoom is usually to the tune of 1.5–2 times. While standard scopes have optical zoom of 30–35, high-magnification ("zoom") endoscopes can magnify up to 150 times. All the currently available manufacturers have zoom endoscopes with both optical and digital zoom.[4]

Majority of the studies have clubbed this high-resolution magnification technology with other image-enhanced technologies such as NBI, i-scan, FICE, or the conventional chromoendoscopy and promote enhanced image viewing experience and lesion detection rates for the endoscopist.

Virtual Chromoendoscopy

Virtual chromoendoscopy uses enhanced tissue architecture visualization by optical filtering or software-driven image processing. Various available technologies are narrow-band imaging (NBI, Olympus Corporation), multiband imaging with FICE (Fujinon, Japan), and i-scan (Pentax, Japan). Majority of the studies experimenting image enhancement systems have been with the use of NBI.

Narrow-band Imaging

Narrow-band imaging system primarily aims at targeting the mucosal vasculature and henceforth highlights the alterations therein during pathologic settings. The shorter blue wavelength (i.e., 415 nm), corresponding to the main peak absorption spectrum of hemoglobin, enhances the superficial mucosal capillaries as brown and the longer green wavelength (i.e., 540 nm) corresponding to a secondary hemoglobin absorption peak displays the deeper mucosal and submucosal vessels as cyan.[5] NBI can be used for the diagnosis of a variety of conditions such as Barrett's esophagus, gastric metaplasia, *Helicobacter pylori* infection, celiac disease, and also classifying colorectal tumors using NBI International Colorectal Endoscopic (NICE) Classification[6] based on color, microvascular architecture and surface pattern of lesions, and a host of other conditions. The technology of NBI has shown promise as far as better mucosal detail description is concerned and adequate training in this technology holds the key to its better utilization **(Figs. 1A and B)**.

Optical Biopsy

The correlation of endoscopic findings and the pathological picture is often a tricky affair and in spite of techniques aiding for targeted biopsies, the

JAYPEE BROTHERS

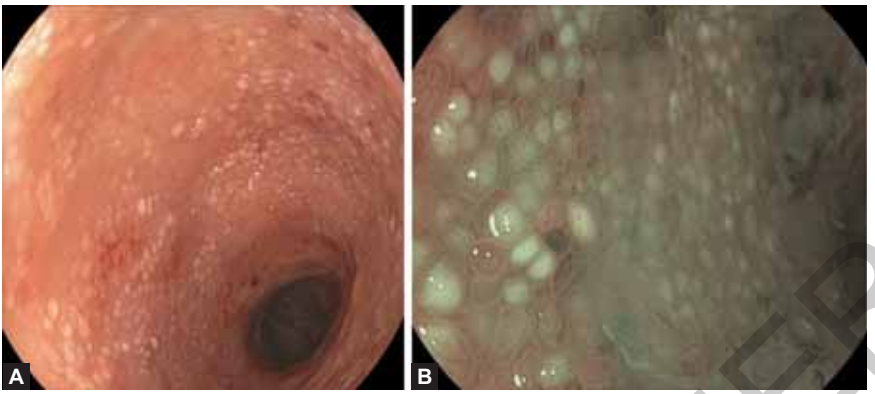

Figs. 1A and B: Terminal ileum in a case of primary intestinal lymphangiectasia: (A) White light image; (B) narrow-band imaging (NBI) image showing the enlarged whitish villi.

exact representative tissue for a corroborative histology keeps eluding the endoscopist and frustrating the pathologist. Hence, the concept of so called "optical biopsy" or "virtual biopsy." It encompasses three technologies, namely CLE, endocytoscopy (EC), and optical coherence tomography (OCT). The most widely studied is CLE.

Confocal Laser Endomicroscopy

Confocal laser endomicroscopy is a technique of high-resolution image acquisition of the mucosal layers of the GI tract. The current CLE devices are based on tissue fluorescence wherein exogenous fluorescence contrast agents such as fluorescein (most commonly used) (Pharmalab, Lane Cove, New South Wales, Australia) are used.[7] The devices commercially available are the Pentax Endomicroscopy system integrated in to the conventional endoscopy (Pentax, Tokyo, Japan) and the probe-based Cellvizio Endomicroscopy system (Mauna Kea Technologies, Paris, France).

Various applications for CLE include Barrett's esophagus, early gastric cancer, colonic polyps, and for inflammatory bowel diseases (IBD). Yet another advancement is in the form of needle-based CLE (nCLE; AQ-Flex19; Mauna Kea), which can be inserted through a 19-gauge EUS-FNA needle, and have found utility in the diagnosis of pancreatic cysts.[8]

The spectrum of CLE is rapidly expanding and even molecular imaging is being done along with it. More than its use in the GI lumen, it has applicability for the unmet needs in the pancreatobiliary domain where lack of a histological "gold standard" further complicates the scenario.

Endocytoscopy

Another emerging technique for real time in vivo histology is endocytoscopy (Olympus, Tokyo, Japan) (EC). Using the concept of contact white-light

JAYPEE BROTHERS

microscopy, EC, unlike CLE, can characterize cellular structures of only the superficial epithelial layer, not the deeper layers, in a plane parallel to the mucosal surface. Limited studies exist in its evaluation for esophageal lesions[9] and colorectal lesions.[10] More and more data are being generated in favor of EC's role, although it is still in its infancy.

Video Capsule Endoscopy

Video capsule endoscopy (VCE) has come a long way in becoming an invaluable tool in the diagnostic armamentarium of small bowel diseases including bleed[11] celiac disease, inflammatory bowel disease, tuberculosis, lymphoma, and a host of other conditions **(Figs. 2A and B)**. VCE is not only limited to the small bowel, and dedicated colon capsule (Pillcam Colon 2-Given Imaging, Israel) and esophageal capsule (PillCam Eso) are available for the specific imaging of the respective areas.[12] Image-enhancement techniques have also been incorporated in the VCE with as wider 360-degree viewing capsule[13] and FICE in the Given Imaging workstation (Pillcam SB2)[14] for "better" visualization.

The major drawback of VCE is the lack of facilities to intervene or take biopsies in case a lesion is detected. Magnetic steerable capsule endoscopy is now being evaluated for their potential role in better image-capturing capacity.[15] Future lies in the development of its capability to both diagnose as well as administer therapy such as drug delivery systems.

ADVANCES IN ENDOSCOPIC RETROGRADE CHOLANGIOPANCREATOGRAPHY

Endoscopic retrograde cholangiopancreatography (ERCP) has been the standard-of-care therapeutic tool for management of pancreatobiliary diseases for quite some time now. Management of cholangiocarcinoma (CCA)

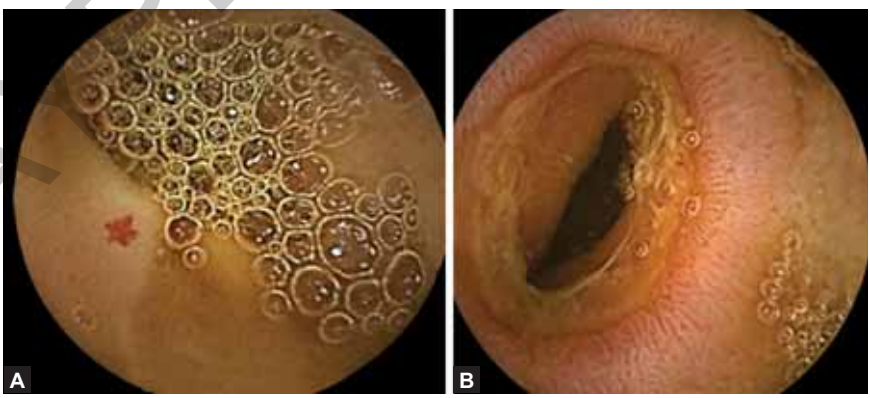

Figs. 2A and B: Video capsule endoscopy images of various conditions: (A) Telangiectasia in a case of occult gastrointestinal (GI) bleed; (B) Diaphragmatic disease in a case of pain abdomen with nonsteroidal anti-inflammatory drug (NSAID) abuse.

JAYPEE BROTHERS

included biliary stenting which improved the quality of life but did not aid in improvement of survival. Hence, the newer concept of tumor ablative therapies such as photodynamic therapy (PDT) and radiofrequency ablation (RFA) which is believed to not only improve stent patency but also augment survival.

Endoscopic Retrograde Cholangiopancreatography-guided Photodynamic Therapy

Photodynamic therapy (PDT) is an ablative modality for the local control of tumor and entails the administration of photosensitizing agent that concentrates inside target cells and is activated by specific wavelength of light to generate reactive-oxygen species (ROS). ROS cause cellular damage and antiangiogenic pathways too get activated.[16] Recent meta-analysis hints toward improved survival in patients undergoing PDT with stenting compared to stenting alone.[17] Side effects include phototoxicity. More data are needed to define the ideal number of sessions required or need for bilateral versus unilateral treatment.

Endoscopic Retrograde Cholangiopancreatography-guided Radiofrequency Ablation

Radiofrequency ablation is another modality for management of perihilar CCA using electromagnetic wave frequencies in the range of 10^4 to 3×10^{12} Hz to create molecular friction and heat generation leading to coagulative necrosis and tissue destruction.[18] Recent meta-analysis showed better stent patency and survival benefit in patients with RFA and stenting.[19] RFA is a relatively well-tolerated procedure with rare adverse effect profile.

Hence, both PDT and RFA are now being used not only for palliation of unresectable CCA but also as neoadjuvant therapy for patients awaiting liver transplantation.

Cholangioscopy and Pancreatoscopy

Slim endoscopes and optical catheters are used to visualize the bile duct or the pancreatic duct directly and hence facilitate identification and management of intraductal lesions. The systems available are endoscope-based dual-operator systems, also known as "mother-daughter" (Olympus America, Center Valley, PA, and Pentax, Montvale, NJ) and a catheter-based system, known as "single-operator" cholangioscopy (SpyGlass DS Direct Visualization System, Boston Scientific Endoscopy, Marlboro, MA). Moreover, slim scopes (4.9–5.9 mm outer diameter) can be used for direct cholangioscopy. Fiberoptic cholangioscopes have a working channel of 1.2 mm allowing passage of forceps and lithotripsy fibers with up/down tip deflection,[20] for sampling and therapy. Pancreatoscopy is done with the same devices as that for cholangioscopy.

Cholangioscopy is commonly used for difficult bile duct stones and for evaluation of indeterminate strictures, with or without biopsy. NBI

JAYPEE BROTHERS

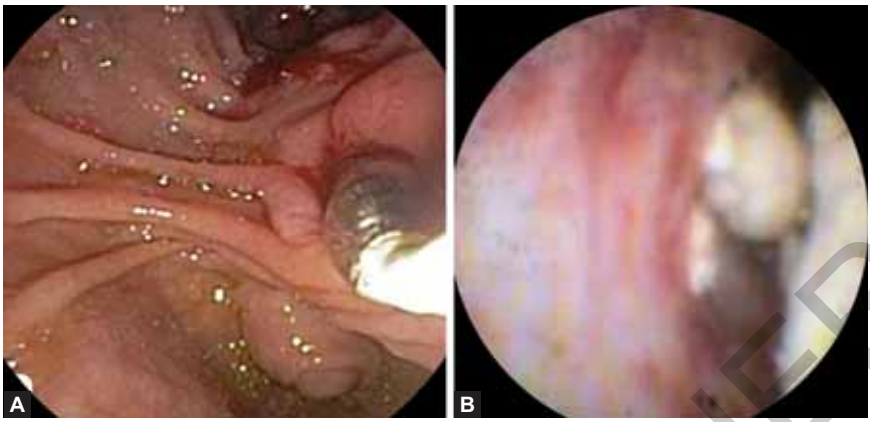

Figs. 3A and B: Pancreatoscopy using SpyGlass in a case of chronic pancreatitis: (A) Pancreatoscopy through minor papilla; (B) Pancreatic duct with intraductal stones.

cholangioscopy has been used in various biliary tract diseases such as biliary strictures, CCA, and biliary papillomatosis. Pancreatoscopy is used for pancreatic ductal stones and for neoplastic lesions such as intraductal papillary mucinous neoplasm (IPMN) **(Figs. 3A and B)**.

ADVANCES IN DIAGNOSTIC ENDOSCOPIC ULTRASOUND

Endoscopic ultrasound has come a long way into becoming one of the most valuable tool for investigation and plan management in a wide variety of GI diseases. Diagnostic accuracy of EUS-guided tissue acquisition reaches a sensitivity and specificity of 80% and 100%, respectively, but can be technically demanding and require multiple passes. Therefore, newer technologies are needed to not only reduce the need for sampling but also help in obtaining targeted tissue for accurately clinching the diagnosis.

Endoscopic Ultrasound-guided Elastography

Elastography is a real-time method for the assessment of tissue stiffness based on the internal force concept, wherein stiffer tissues pose lower strain and hence deform less on compression.[21] Two different modes are available—qualitative and quantitative. Qualitative elastography quantifies the degree of deformation after compression in the B-mode imaging and the strain is smaller in hard tissues than in soft tissues.[22] Hard tissue is dark blue and soft tissue is red with intermediate being green and medium in yellow **(Fig. 4)**. Quantitative elastography uses strain ratio and strain histogram for quantification of the hardness of the tissue and various cut-off points are taken to determine malignancy **(Table 1)**.

Endoscopic ultrasound-elastography has been used primarily for the assessment of solid pancreatic lesions and enlarged lymph nodes. Since the

JAYPEE BROTHERS

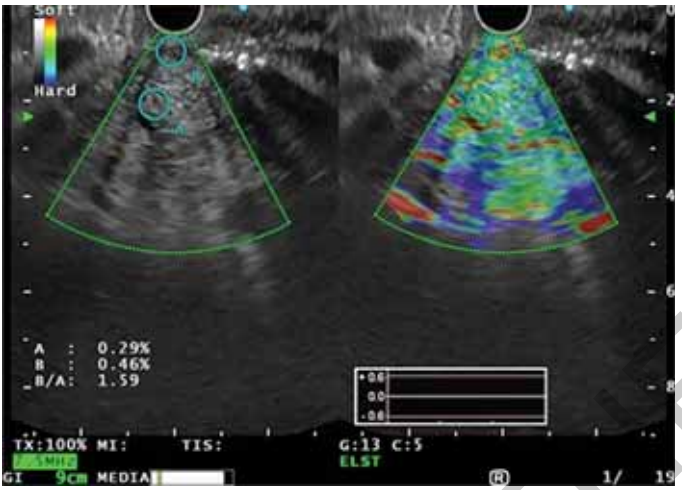

Fig. 4: Endoscopic ultrasound (EUS) elastography with strain ratio assessment.

TABLE 1: Endoscopic ultrasound (EUS) elastography: Qualitative and quantitative.

Qualitative assessment		
Color and pattern	*Hardness*	*Chance of malignancy*
Heterogeneous red and green	Soft	No
Homogenous green	Soft	No
Heterogeneous green predominant	Intermediate	No
Heterogeneous blue	Hard	Yes
Homogeneous blue	Hard	Yes
Heterogeneous green and blue	Intermediate hard	Not definite
Quantitative assessment		
Parameter	*Value*	*Chance of malignancy*
Strain ratio	>10	yes
Strain histogram	<50	Yes

(Adapted from: Iglesias-Garcia J, Dominguez-Munoz JE. Endoscopic ultrasound image enhancement elastography. Gastrointest Endosc Clin N Am. 2012;22(2):333-48, x-xi.)

first study by Giovanni et al.,[23] describing EUS-elastography in pancreatic masses, multiple studies have assessed the role of this modality for its accuracy in predicting malignancy. Meta-analysis has shown that elastography could differentiate pancreatic malignancy from inflammatory masses with a sensitivity of 95% and specificity of 67–69%.[24] It has also been shown to be helpful to differentiate benign from malignant lymph node and hence its role in cancer staging.

Various other upcoming uses of this modality include transrectal elastography for prostate cancer, rectal cancer, IBD, and for evaluation of subepithelial masses and adrenal glands.

JAYPEE BROTHERS

Contrast-enhanced Endoscopic Ultrasound

Evaluation of vascularity of solid lesions can help differentiate benign from malignant lesions. This concept is used in contrast-enhanced harmonic endoscopic ultrasound (CH-EUS). The CH-EUS uses the technology of signal generation by hitting gas-filled microbubbles (diameter 2–5 mm) of contrast agents with ultrasonic waves.[25] Second-generation contrast agents such as SonoVue (sulfur hexafluoride microbubbles; Bracco, Italy) and Sonazoid (perfluorobutane microbubbles; GE Healthcare, USA) are commonly used.

Contrast-enhanced harmonic endoscopic ultrasound has wide applicability including solid pancreatic lesions such as pancreatic adenocarcinoma, mural nodule of IPMN, neuroendocrine tumor, inflammatory masses, and gastrointestinal stromal tumor (GIST). It can be used for tumor staging and nodal staging as well as for assessment of chemotherapeutic response.

Advances in Endoscopic Ultrasound-guided Tissue Acquisition

The art of EUS-guided tissue acquisition (EUS-TA) has evolved over the last 25 years since its first description. Multiple factors such as site of lesion, technique of sampling, needle-type, and expertise of the endosonographer influence the outcome in EUS-TA. Recent advancements in the field of needle design have enabled the art of EUS-guided biopsy sampling (EUS-FNB) with better tissue acquisition for a core biopsy. The ProCore FNB (EchoTip Procore; Cook Medical, USA) has additional beveled side cut of the distal needle shaft, while two other FNB needles have different needle tip design—Sharkcore (Medtronic, Minneapolis, MN, USA) and Franseen needle tip (Acquire; Boston Scientific, Natick, MA, USA) **(Figs. 5A to C)**.

The advent of EUS-FNB needles enables core tissue acquisition, need for less number of passes and may eventually obviate the need for rapid onsite cytological evaluation (ROSE), a facility entailing higher costs. Moreover, newer devices such as through the needle cytology brushes and forceps can help improve the diagnostic yield in pancreatic cystic lesions.



Figs. 5A to C: The different kinds of FNB needles: (A) EchoTip ProCore HD EUS needle (*Courtesy:* Cook Medical, Bloomington, IN); (B) SharkCore FNB needle (*Courtesy:* Medtronic, Minneapolis, MN); and (C) Acquire EUS-FNB device (*Courtesy:* Boston Scientific, Natick, MA).

JAYPEE BROTHERS

Needle-based Confocal Laser Endomicroscopy

The technique of CLE provides the ability to produce real-time microscopic imaging of the lesion, the art of "optical biopsy." Of late, the development of needle-based CLE (nCLE) have been used predominantly for the characterization of pancreatic cysts,[26] although its use extends to solid pancreatic lesions as well as lymph nodes.

ADVANCES IN THERAPEUTIC ENDOSCOPIC ULTRASOUND

There has been remarkable progress in the field of pancreatobiliary endoscopy in the past few years with immense progress in the use of EUS as a therapeutic tool. The spectrum of therapeutic EUS has expanded from drainage of pancreatic fluid collections to EUS-guided bile duct and pancreatic duct access in cases of failed ERCP, gallbladder drainage, gastrojejunostomy (GJ), and EUS-guided cancer therapy including celiac plexus neurolysis (CPN).

Lumen-apposing Metal Stents

Lumen-apposing metal stents (LAMS) has opened the gates of therapeutic endoscopy to a wide array of interventional options. Earlier plastic stents were used to drain pancreatic fluid collections but with the advent of LAMS, not only can the fluid be drained but also provide a wide conduit (10–20 mm) allowing the endoscopist to pass regular endoscopes beyond the lumen of the GI tract for carrying out procedures such as necrosectomy (termed as direct endoscopic necrosectomy).[27] The various LAMS available in the market are the Hot Axios (Boston Scientific. Marlborough, MA, USA), NAGI, and SPAXUS stents (Taewoong Medical, South Korea).

The use of these LAMS provides high technical and clinical success with short procedure duration. Its use is not only restricted to drainage of pancreatic fluid collections, but also for EUS-guided choledochoduodenostomy, gallbladder drainage, and GJ as will be discussed in the subsequent text.

Endoscopic Ultrasound-guided Biliary Drainage

Endoscopic retrograde cholangiopancreatography is the standard-of-care for endoscopic biliary access. Failure to cannulate the bile duct can occur in 4–16% of cases.[28] In these cases, the options earlier used to be surgical drainage or percutaneous transhepatic drainage (PTBD). Surgical drainage has good technical success but high mortality (30-day mortality 15%) and major complications rate (39%). PTBD, on the other hand, is technically easy but has very high reintervention and complication rates (~80%) with poor quality of life due to external catheter. With the advent of endoscopic ultrasound-guided biliary drainage (EUS-BD), these shortcomings can be circumvented and can be used in suitable cases safely and effectively.

JAYPEE BROTHERS

The indications for EUS-BD include failed ERCP, altered anatomy, inaccessible papilla due to tumor infiltration, and large ascites precluding PTBD.[29]

Technique

Endoscopic ultrasound-guided biliary drainage can be performed in multiple ways depending on the site of biliary obstruction, the accessibility of papilla, and the expertise and comfort of the interventionist.

The basic steps involve access into either the left hepatic ductal system or the common bile duct (CBD) with the help of, preferably, a 19G EUS-FNA needle. After puncturing the system, the position of the needle is confirmed by aspiration of bile, followed by injection of contrast to obtain a cholangiogram. Guide-wire is then negotiated through the needle into the ductal system. The tract is then dilated using graded diameter stiff catheter, balloon catheter, or cystotome. Once the access is secured and tract is dilated, then stenting is done.

There are four ways of EUS-BD, namely, hepaticogastrostomy (EUS-HGS) choledochoduodenostomy (EUS-CDS), EUS-guided antegrade stent (EUS-AS) placement, and EUS-guided rendezvous procedure (EUS-RV). EUS-HGS **(Figs. 6A to D)** entails placement of stent in the left ductal system with proximal

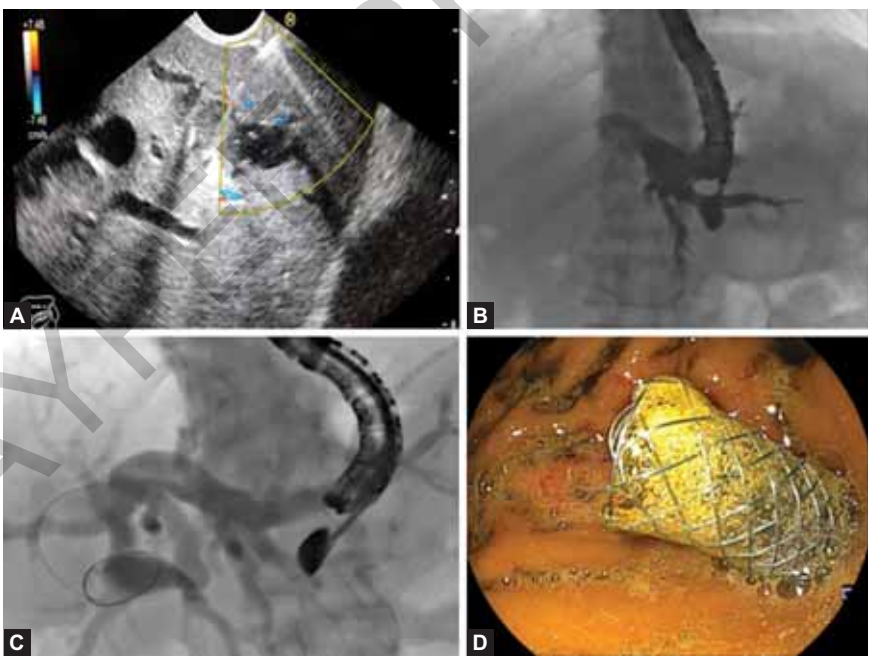

Figs. 6A to D: Endoscopic ultrasound (EUS)-hepaticogastrostomy: (A) EUS-guided puncture of the dilated left ductal system; (B) Contrast injection to confirm and obtain cholangiogram; (C) Guidewire negotiated up to the hilum; and (D) Intragastric part of the self expandable metallic stent (SEMS) seen.

JAYPEE BROTHERS

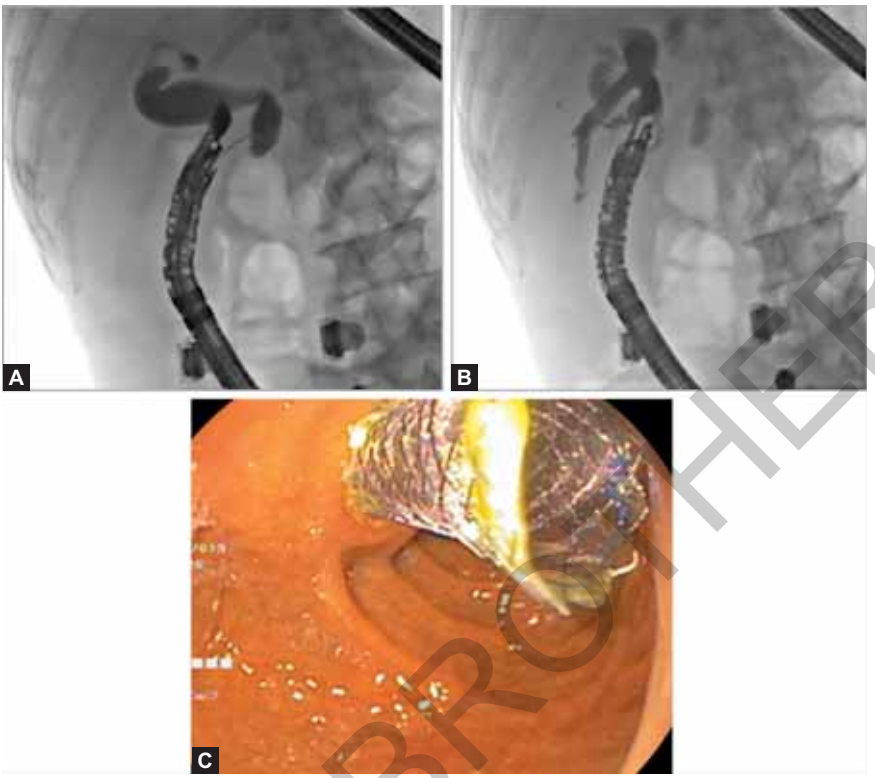

Figs. 7A to C: Endoscopic ultrasound (EUS) choledochoduodenostomy in pancreatic cancer with duodenal obstruction: (A) EUS-guided puncture of the CBD from D1 station; (B) Guidewire looped inside the CBD; and (C) Endoscopic image of the CDS stent in D1.

end in the stomach creating a permanent transgastric-transhepatic fistula. EUS-CDS **(Figs. 7A to C)** creates a transduodenal-CBD fistula for transmural drainage. EUS-AS helps in the placement of stent in the biliary system across the papilla akin to ERCP. EUS-RV is a technique to assist the conventional ERCP by negotiating the guide wire across the papilla and then complete the procedure using conventional ERCP. The various nuances of the four techniques and indications are detailed in **Table 2**. No definite consensus exists as to which technique or approach is best.

Published data suggest a cumulative success rate of EUS-BD to be 88–93%,[30] with complications rate of 13–20% cases. Complications include infection (cholangitis, cholecystitis, etc.), pneumoperitoneum, bile leak, bleeding, and stent migration. In fact, recent review showed that EUS-BD fared better than PTBD in terms of better clinical success, less adverse events, and lower rates of reinterventions.[31]

Overall, EUS-BD scores over both surgery and PTBD with good safety profile. Nevertheless, EUS-BD is a complex procedure and should be done by skilled endoscopists with good surgical and interventional radiology back-up.

JAYPEE BROTHERS

TABLE 2: The various techniques of endoscopic ultrasound-guided biliary drainage (EUS-BD).

Technique	*Indications*	*Route*	*Remarks*	*Advantages/Disadvantages*
EUS-hepaticogastrostomy (EUS-HGS)	• Hilar or CBD obstruction with inaccessible papilla • Failure to access left ductal system through PTBD	Intrahepatic puncture	• Creation of permanent fistula—transgastric transhepatic • Metallic SEMS preferable	• Stable scope position • Technically challenging stent deployment
EUS-Choledochoduodenostomy (EUS-CDS)	• Lower or mid-CBD obstruction with inaccessible papilla	Extrahepatic route	• Creation of permanent fistula transduodenal • SEMS preferable	• Stable long loop scope position • Technically easier stent deployment
EUS-antegrade stent placement (EUS-AS)	• Lower CBD obstruction with inaccessible papilla	Intrahepatic route	• Placement of stent across papilla akin to ERCP	• Technically difficult guide-wire negotiation • Temporary fistula across the transgastric puncture route
EUS-Rendezvous (EUS-RV)	Failed ERCP with accessible papilla	• Intrahepatic route • Extrahepatic route	Placement of guidewire across papilla for facilitation of conventional ERCP	• Intrahepatic route: Stable scope position but difficult guidewire manipulation • Extrahepatic route: Unstable scope position at D1-D2 junction but easier guidewire manipulation

(CBD: common bile duct; ERCP: endoscopic retrograde cholangiopancreatography; PTBD: percutaneous transhepatic drainage; SEMS: scanning electron microscopes)

JAYPEE BROTHERS

Endoscopic Ultrasound-guided Pancreatic Duct Drainage

Similar to EUS-BD, EUS-guided pancreatic duct drainage (EUS-PD) can be performed with the technical steps similar to that of EUS-BD. Primarily, it is done in cases of chronic pancreatitis requiring stenting in whom ERCP has failed probably due to strictures or other causes. Other indication can be pancreatic trauma with duct disruption.

Access to the duct can be obtained at either the neck or body of the pancreas and pancreatic rendezvous is attempted. In cases where this cannot be done, transluminal drainage of the duct is carried out by creating a pancreaticogastrostomy or pancreaticoduodenostomy **(Figs. 8A to D)**. EUS-PD is technically more challenging and complications include pancreatitis, bleeding, pneumoperitoneum, and stent migration.

Endoscopic Ultrasound-guided Gallbladder Drainage

Cholecystitis is ideally managed by antibiotics and surgery. However, in high surgical risk candidates, patients can be managed either by the percutaneous route by placement of cholecystostomy tube or by ERCP-guided transpapillary

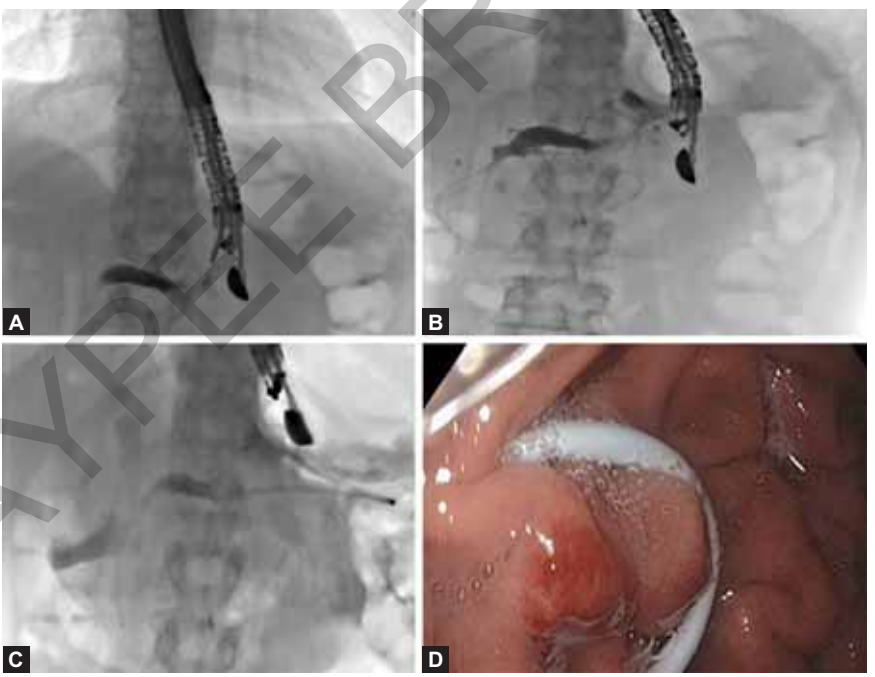

Figs. 8A to D: Endoscopic ultrasound (EUS)-guided pancreatic duct drainage (EUS-PD) in a case of groove pancreatitis: (A) EUS-guided pancreatic duct (PD) puncture; (B) Pancreatogram showing stricture in head with dilated PD, guidewire negotiated across stricture; (C) Long plastic stent placed and pancreatogastrostomy created; and (D) Endoscopic view of stent.

JAYPEE BROTHERS

stent placement. However, the percutaneous route has the risk of an externally lying catheter, while the ERCP route has a technical success of only 81%. EUS-guided gallbladder drainage (EUS-GBD) has gained immense popularity since its first description in 2007.[32]

The access to the gallbladder is gained either through the prepyloric area or the first part of duodenum, usually with a 19G needle and drainage can be done either by placement of naso-gallbladder drains, plastic stents, or metallic stents. The technique has a technical and clinical success rates of nearly 100% with adverse events rate of 6–12%.[33] With the recent advent of "Hot LAMS," having electrocautery mounted tip, the steps of the procedure are reduced. Long-term data on outcome of EUS-GBD needs to be established.

Endoscopic Ultrasound-guided Gastrojejunostomy

Gastric outlet obstruction commonly occurs with advanced upper GI and pancreatobiliary malignancies and requires intervention. The available options are surgical GJ and endoscopic enteral stenting. Surgical GJ is fraught with prolonged recovery time and gastroparesis while enteral stenting may migrate or occlude with tumor overgrowth. EUS-guided GJ (EUS-GJ) has come up as an excellent option with the use of a LAMS with long-term patency.[34]

Endoscopic ultrasound-guided gastrojejunostomy can be done by four techniques, namely, water immersion, water-inflated balloon technique, EPASS balloon, and the free-hand technique. In order to reduce the steps of procedure, electrocautery-mounted LAMS ("Hot LAMS") are preferred **(Figs. 9A to E)**.

Technical success reported is 92%.[35] Compared to enteral stenting, EUS-GJ had less reintervention rates,[36] similar clinical success compared to surgical GJ.[37] Thus, early data of this new technique of EUS-GJ is promising and long-term data needs to be established.

Endoscopic Ultrasound-guided Vascular Interventions

The advantage of obtaining high-resolution images of the mediastinal and abdominal vasculature enables EUS with Doppler facility as a modality for an accurate vascular access and possible therapy. It has been shown to be feasible for Dieulafoy's lesions, bleeding tumors, and pseudoaneurysms.

For gastric varices (GV), the standard-of-care is endoscopic glue (cyanoacrylate) injection with hemostasis rates of 58–100% and rebleeding rates of 0–40%.[38] EUS has multiple technical advantages over conventional endoscopic therapy in the management of GV. With EUS, (1) detection rate of GV increases and is more accurate because of the Doppler facility; (2) residual patency can be assessed as that can predict rebleed; (3) enables accurate delivery of the hemostatic agent into the lumen of the varix; (4) "feeder" vessel can be identified and targeted, if needed; (5) stainless steel coils can be injected and hence can reduce the need for glue injection reducing embolization risk.

JAYPEE BROTHERS

for detailed information on surgery books, visit our website www.jaypeebrothers.com, for detailed information on surgery books, visit our web

Roshan Lall Gupta's
Recent Advances in SURGERY-17

Salient Features

- Topics with recent advances in the field of Surgery covered
- Focused for postgraduate students and young practicing Surgeons
- Authors of chapters are eminent surgeons and experts in their field
- Important topic from various specialty covered
- Topic may change the clinical surgical practice included.

Puneet MS DNB (Surg) MNAMS FACS has competed his graduation and postgraduation from Institute of Medical Sciences, Banaras Hindu University, Varanasi, Uttar Pradesh, India. He has obtained DNB in Surgery from National Board of Examination and worked as Senior Registrar in Dr Ram Manohar Lohia Hospital, New Delhi, India. Thereafter, he has worked in different hospitals in various capacities. He was appointed as Assistant Professor in King George Medical College (KGMC), UP state colleges and Institute of Medical Sciences, Banaras Hindu University, Varanasi, Uttar Pradesh, India. However, he decided to join his alma mater. He has been elevated to Associate Professor and then Professor and Head in the Department of Surgery, Institute of Medical Sciences, Banaras Hindu University, Varanasi, Uttar Pradesh, India.

Professor Puneet has presented various papers and delivered lectures in India and abroad. He has best paper award and travelling fellowships to his credit. He has done his fellowship in hepatobiliary and pancreatic surgery from Queen Elizabeth Hospital, Birmingham, UK. He has published more than 80 National and International papers, authored/edited 6 books and written 20 chapters in various publications. He has been investigator to various research projects and reviewers to journals. He is also Fellow of American College of Surgeons, Chicago and Recipient of Citation from Oklahoma, USA.

Printed in India

Available at all medical bookstores or buy online at www.jaypeebrothers.com



JAYPEE BROTHERS
Medical Publishers (P) Ltd.
EMCA House, 23/23-B, Ansari Road,
Daryaganj, New Delhi - 110 002, INDIA
www.jaypeebrothers.com

Join us on facebook.com/JaypeeMedicalPublishers

Shelving Recommendation
SURGERY

