Contents

1. General Introduction 1



- Anatomical Terminology 3
- Structures Encountered in Dissection 5
- Dissection 17
- Instruments and their Usage 18
- Dissection Methodology 18

2. Upper Limb 21



- Pectoral Region 24
- Axilla 31
- Sternoclavicular Joint 35
- Back 36
- Disarticulation of the Upper Limb 39
- Scapular Region 40
- Anterior Compartment of Arm and Cubital Fossa 42
- Back of the Arm 48
- Pectoral Girdle and Shoulder Joint 51
- Front of Forearm and Hand 53
- Back of the Forearm and Hand 69
- Joints of the Hand 77

3. Thorax 85

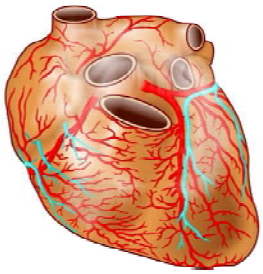

- Thoracic Wall 87
- Pleural Cavity 92
- Anterior Mediastinum 98
- Middle Mediastinum 98
- Posterior Mediastinum 112

4. Abdomen 117

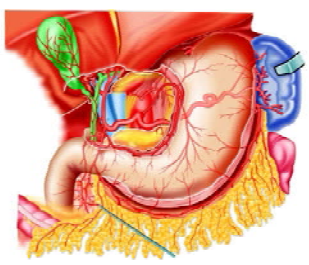

- Loin 121
- Anterolateral Abdominal Wall 124
- Inguinal Canal and Scrotum 128
- Abdominopelvic Cavity 134
- Diaphragm 137
- Lesser Sac 138
- Coeliac Trunk 139

- Liver 140
- Gallbladder 142
- Stomach 143
- Spleen 145
- Jejunum and Ileum 146
- Large Intestine 148
- Duodenum and Pancreas 153
- Kidney, Suprarenal and Blood Vessels 158
- Autonomic Nerve Plexuses 161
- Posterior Abdominal Wall 163

5. Pelvis and Perineum 167

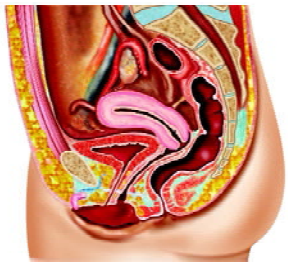

Pelvis 169
- Pelvic Peritoneum 170
- Male Pelvis 173
- Female Pelvis 177
- Pelvic Wall 180

Perineum 185
- Anal Triangle 185
- Urogenital Region—Male 187
- Urogenital Region—Female 191

6. Lower Limb 195



- Anteromedial Aspect of Thigh 199
- Gluteal Region 211
- Back of Thigh and Popliteal Fossa 218
- Hip Joint 224
- Back of Leg 227
- Knee Joint 231
- Anterolateral Compartment of Leg and Dorsum of Foot 236
- Ankle 243
- Joints of the Foot 253
- Tarsal Joints 255

7. Head and Neck 259

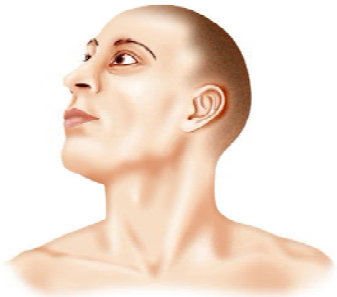

Superficial Dissection of Head 262
- Scalp 262
- Face 267

Neck 274
- Posterior Triangle 277
- Suboccipital Triangle 283
- Anterior Triangle 285
- Sternoclavicular Joint–Disarticulation 288
- Inlet of Thorax 289
- Thyroid and Parathyroid 291
- Neurovascular Bundle 292
- Digastric Triangle 300

Deep Dissection of Head 302
- Temporal and Infratemporal Region 302

- Submandibular Region 308
- Removal of Spinal Cord 310
- Cranial Cavity 312
- Orbit 317
- Nose 323
- Mouth 331
- Pharynx 335
- Larynx 339
- Eyeball 344

8. Central Nervous System 347

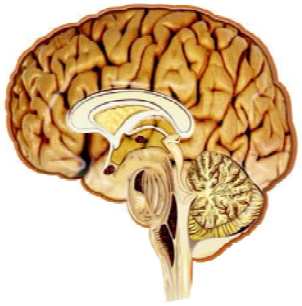

Spinal Cord 347
- Blood Supply of Spinal Cord 349
- External Features 350
- Internal Structure 352

Brain 354
- External Features 354
- Brainstem 360
- Cerebellum 363
- Fourth Ventricle 368
- Sections of Brainstem 369
- Forebrain 374
- Cerebrum 376
- Limbic System 382
- White Matter of Cerebrum 383
- Lateral Ventricle 386
- Third Ventricle 387
- Diencephalon 388
- Sections of Forebrain 389

Appendix 393

Index 395