Contents

CT Anatomy: Abdomen and Pelvis 1

SECTION 1 Esophagus

1. Hiatus Hernia 19
2. Esophageal Carcinoma 21
3. Leiomyomatosis of Esophagus 23

SECTION 2 Diaphragm

4. Eventration 27
5. Eventration of Diaphragm with Duplication of Inferior Vena Cava 29

SECTION 3 Stomach

6. Gastrointestinal Stromal Tumor 33
7. Gastric Malignanacy 35

SECTION 4 Duodenum

8. Carcinoma Duodenum 41

SECTION 5 Small Bowel

9. Small Bowel Obstruction 45
10. Ileocecal Lymphoma 47
11. Small Bowel Gastrointestinal Stromal Tumor 49
12. Angiodysplasia of Jejunum 51
13. Ileal Carcinoma 53
14. Pneumatosis Intestinalis 55
15. Midgut Volvulus 57

SECTION 6 Appendix

16. Acute Appendicitis 61
17. Appendicular Abscess 63

SECTION 7 Colon

18. Intussusception 67
19. Nontoxic Megacolon 70

20. Sigmoid Diverticulitis 72
21. Abdominal Koch's 74
22. Carcinoma Sigmoid 77

SECTION 8 Rectum

23. Carcinoma Rectum 81

SECTION 9 Liver

24. Focal Fatty Liver 87
25. Simple Hepatic Cyst 89
26. Budd-Chiari Syndrome 91
27. Liver Laceration 94
28. Hepatic Abscess 97
29. Hepatic Hydatid Cyst 100
30. Hepatic Hemangioma 103
31. Focal Nodular Hyperplasia 106
32. Hepatic Adenoma 108
33. Hepatic Angiomyolipoma 110
34. Hepatocellular Carcinoma 112
35. Hepatic Metastases 115
36. Hepatoblastoma 118
37. Intrahepatic Cholangiocarcinoma 120
38. Extrahepatic Cholangiocarcinoma 123
39. Transient Hepatic Attenuation Difference 125

SECTION 10 Gallbladder

40. Choledochal Cyst 129
41. Acalculus Cholecystitis 131
42. Acute Calculus Cholecystitis 133
43. Emphysematous Cholecystitis 136
44. Choledocholithiasis 138
45. Porcelain Gallbladder 140
46. Carcinoma Gallbladder 142

SECTION 11 Pancreas

47. Acute Pancreatitis 147
48. Pancreatic Pseudocyst 149
49. Necrotizing Pancreatitis 153
50. Periampullary Carcinoma with Metastases 155

SECTION 12 Spleen

51. Splenunculus 161
52. Splenic Trauma 163
53. Splenic Abscess 166

SECTION 13 Vascular

54. Superior Mesenteric Artery Syndrome 171
55. Superior Mesenteric Artery Thrombosis 173
56. Accessory Renal Artery Stenosis 176
57. Aneurysm of Abdominal Aorta 178
58. Inferior Vena Cava Thrombus 180
59. Aortic Thrombus 182
60. Portal Vein Thrombosis 184

SECTION 14 Adrenal

61. Adrenal Adenoma 189
62. Pheochromocytoma 192
63. Adrenal Metastases 194

SECTION 15 Renal

64. Renal Aplasia 199
65. Dysplastic Kidney 201
66. Polycystic Kidneys 203
67. Pelviureteric Junction Obstruction 205
68. Obstructive Uropathy 208
69. Emphysematous Pyelonephritis 215
70. Renal Vein Thrombosis 217
71. Renal Laceration 219
72. Renal Angiomyolipoma 221
73. Wilms' Tumor 223
74. Renal Cell Carcinoma 226

SECTION 16 Urinary Bladder

75. Vesical Calculus 231
76. Urinary Bladder Diverticulum 233
77. Cystitis 235
78. Carcinoma Urinary Bladder 237

SECTION 17 Prostate

79. Carcinoma Prostate 243

SECTION 18 Scrotum

80. Hydrocele 247
81. Testicular Trauma 249
82. Seminoma 251
83. Undescended Testis 253

SECTION 19 Penis

84. Penile Carcinoma 257

SECTION 20 Uterus

85. Broad Ligament Fibroid 261
86. Hydrometrocolpos 263
87. Pyometra 265
88. Endometrial Carcinoma 267
89. Carcinoma Cervix 270
90. Vaginal Carcinoma 272
91. Ureterovaginal Fistula 274
92. Vulval Carcinoma 276

SECTION 21 Ovary

93. Ovarian Vein Thrombosis 281
94. Ovarian Tumor 283

SECTION 22 Abdominal Wall

95. Abdominal Wall Sarcoma 289
96. Abdominal Wall Hernia 291

SECTION 23 Miscellaneous

97. Inguinal Hernia 297
98. Omental Infarction 300
99. Primitive Neuroectodermal Tumor 302
100. Fetus-in-Fetu 304
101. Lymphangioma 306

Index *309*

Introduction

PHYSICAL PRINCIPLE OF CT SCAN IMAGING

CT was invented in 1972 by British engineer, Sir Godfrey Newbold Hounsfield in Hayes, United Kingdom at EMI Central Research Laboratories using X-rays. EMI laboratories is best known today for its music and recording business. About the same time South Africa-born American physicist, Allan McLeod Cormack of Tufts University in Massachusetts independently invented a similar process, and both shared the 1979 Nobel Prize.

The first clinical CT scan was installed in 1974. The initial systems were dedicated only to head scanning due to small gantry, but soon this was overcome and whole body CT system with larger gantry, became available in 1976.

Basic principle is to obtain a tomogram having thickness in millimeters of the region of interest using pencil beam X-radiation. The radiation transmitted through the patient is counted by scintillation detector. This information when fed in the computer is analyzed by mathematical algorithms and reconstructed as a tomographic image by the computer so as to provide an insight into the structure being studied (Table 1).

Developments in CT Technology

Conventional Axial CT (Table 1)

Table 1: Generations of CT scan

Generation of CT scan	*Motion of X-ray tube-detector system*	*Stationary detectors*	*X-ray beam type*
First	Translate-Rotate	Two detectors	Pencil beam
Second	Translate-Rotate	Multiple detectors up to 30	Narrow fan beam (10°)
Third	Rotate-Rotate	Multiple detectors up to 750	Wide fan beam (50°)
Fourth	Rotate-Fixed	Ring of 1500–4500 detectors	Fan beam
Fifth	Rotate-Fixed	Two rings of 1500–4500 detectors with two tubes	Fan beam

Spiral/Helical CT

Spiral CT uses the conventional technology in conjunction with slip ring technology, which simultaneously provides high voltage for X-ray tube, low voltage for control unit and transmits digital data from detector array. Slip ring is a circular instrument with sliding bushes that enables the gantry to rotate continuously while the patient table moves into the gantry simultaneously, thus three-dimensional volume rendered image can be obtained. The advantages

over the conventional scanner are the reduced scan time, reduced radiation exposure and reduced contrast requirement with superior information.

Electron Beam CT (EBCT)

In EBCT, both the X-ray source and the detectors are stationary. High energy focused electron beam is magnetically steered on the tungsten target to emit X-rays, which pass through the subject on to the detectors and image is acquired. EBCT is particularly used for faster imaging in cardiac studies.

Multislice/Multidetector CT (MDCT)

Spiral CT uses single row of detectors, resulting in a single slice per gantry rotation. Multislice CT, multiple detector arrays are used resulting in multiple slices per gantry rotation. In addition, fan beam geometry of spiral CT is replaced by cone beam geometry.

The major advantages over spiral CT are improved spatial and temporal resolution, reduced image noise, faster and longer anatomic coverage, and increased concentration of intravenous contrast.

Dual Source CT

The dual energy technology of the new Flash CT provides higher contrast between normal and abnormal tissues making it easier to see abnormalities while reducing radiation. With its two rotating X-ray tubes, enhanced speed and power allows children to be screened more effectively. It turns off the radiation when it comes close to sensitive tissue areas of the body like thyroid, breasts, or eye lens.

Pediatric patients benefit because they do not need to hold breath or lay completely still during the examination and they do not have to be sedated.

Hounsfield Units

CT numbers recognized by the computer are from (–) 1000 to (+) 1000, i.e. a range of 2000 Hounsfield units which are present in the image as 2000 shades of gray, but our eye cannot precisely discriminate between these 2000 different shades.

Hounsfield scale assigns attenuation value of water as zero (HU 0), and other tissues their attenuation value as compared to water as given in Table 2.

Table 2: Attenuation value of various tissues on CT scan

Tissue	*Attenuation value in HU*
Air	(–)1000
Lung	(–) 400 to (–) 800
Fat	(–) 40 to (–) 100
Water	0
Fresh blood	55 to 65
Soft tissue	40 to 80
Bone	400 to 1000

Window Level (WL) and Window Width (WW)

To permit the viewer to understand the image, only a restricted number of HU are put on view and this is accomplished by setting the WL and WW on the console to a suitable range of Hounsfield units, depending on the tissue, for interpreting the image. The expression WL represents the central Hounsfield value of all the Hounsfield numbers within the WW. Tissues with CT numbers outside this array are shown as either black or white. Both the WL and WW can be set on the displayed image as desired by the viewer. On CT examination of the chest, a WW of 300 to 350 and WL of 35 to 45 are chosen to image the mediastinum (soft tissue window) whereas WW of 1500 and WL of 0 is used to assess the lung.

Image Reconstruction

The acquisition of volumetric data using spiral CT means that the images can be postprocessed in ways appropriate to the clinical situation.

Multiplanar reformatting (MPR) is by taking standard axial images and subject to the three-dimensional array of CT numbers obtained with a series of contiguous slices; and can be viewed in sagittal, coronal, oblique and paraxial planes (Figs 1A to C).

Three-Dimensional Imaging

Many fractures like fracture of the mandible associated with frontal bone with or without walls of sinuses can be reconstructed into a 3-dimensional image (Figs 2A to D).

CT Angiography

CT angiography (CTA) sequence is created subsequent to intravenous contrast, images are acquired in the arterial phase and then reconstructed and exhibited in 2D or 3D format. This performance is used for imaging the aorta, renal, cerebral, coronary and peripheral arteries (Figs 3 to 5).

CT is readily available in most hospitals and stand-alone CT centers. It is fast imaging modality and provides with cross-sectional high-resolution images. Data acquired on axial scans can be used for multiplanar and 3D reconstructions.

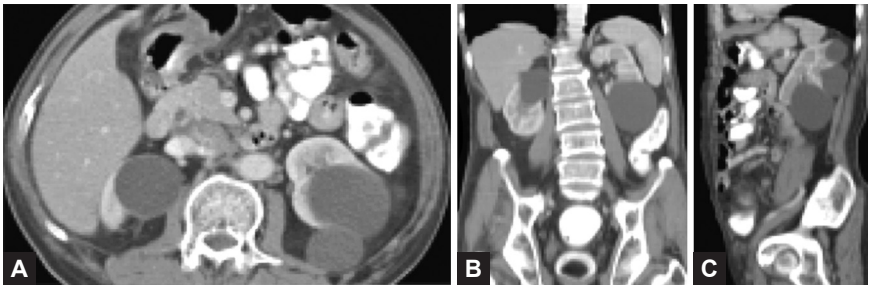

Figs 1A to C Bilateral renal cysts seen in axial section (A) are reformatted into sagittal; (B) and coronal; (C) planes

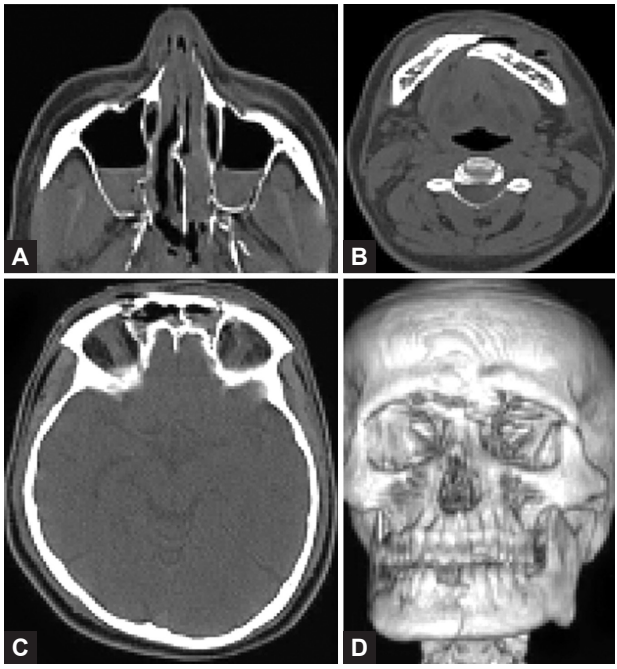

Figs 2A to D Fracture of body of mandible and frontal bone with bilateral maxillary hemosinus. D shows the 3D image of face including mandible

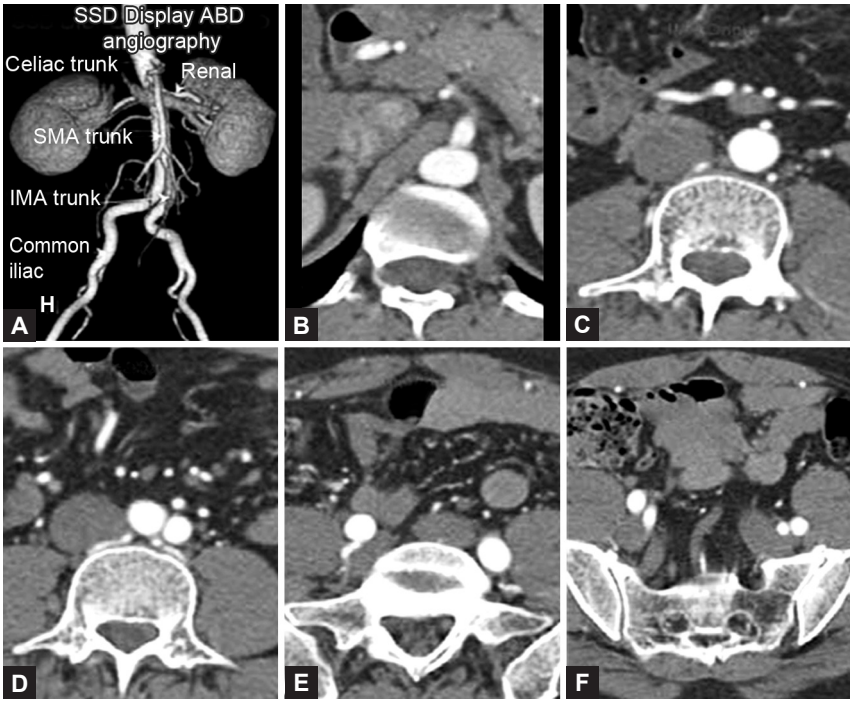

Figs 3A to F CT abdominal angiography

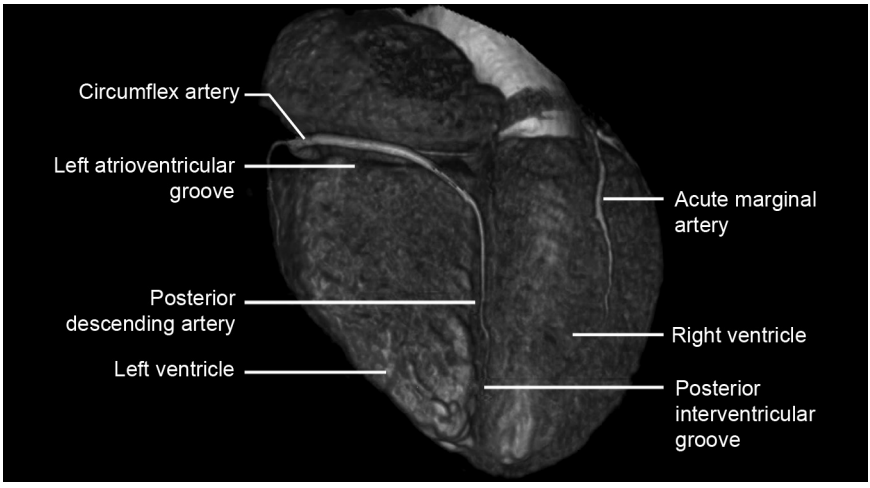

Fig. 4 Volume rendered image—posterior coronal plane shows coronary arteries *(For color version, see plate 1)*

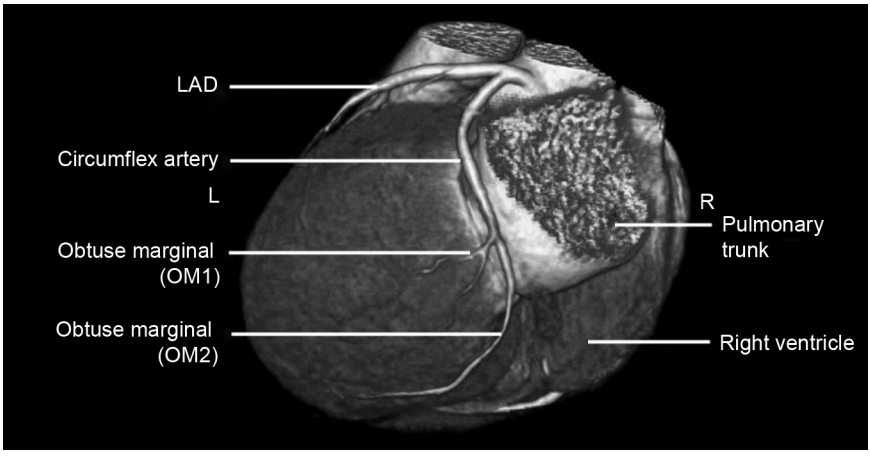

Fig. 5 Volume rendered image—posterior oblique coronal plane shows coronary arteries *(For color version, see plate 1)*

It detects subtle differences between body tissues. However, it uses X-rays which have radiation hazards, CT need contrast media for enhanced soft tissue contrast. Contrast is contraindicated in asthma, cardiac disease, renal and certain thyroid conditions.